

Obstructed Direct Inguinal Hernia – A Rare Encounter

Vikas C Kawarat, Shanthi PS, Kannan R, Ganapathy N*

Institute of General Surgery, Madras Medical College and Ragiv Gandhi Government General Hospital, Chennai, Tamilnadu, India

DOI: [10.36347/sasjs.2020.v06i01.002](https://doi.org/10.36347/sasjs.2020.v06i01.002)

| Received: 16.01.2020 | Accepted: 23.01.2020 | Published: 26.01.2020

*Corresponding author: Ganapathy N

Abstract

Case Report

Obstructed direct inguinal hernia with bowel and peritoneal layer covering bladder as content is rare in presentation. We report a case of a 64year old male patient, who is diabetic and dilated cardiomyopathy patient for past 5 years who presented with complaints of irreducible tender swelling in the right groin for past 2days with history of vomiting and constipation with a negative cough impulse. On emergency exploration, the obstructed hernia was found to be direct type with congested small bowel loops and necrosed bladder peritoneum as content. After gaining bowel viability, contents were reduced and the necrosed segment trimmed off and proceeded on with herniorrhaphy. Direct inguinal hernia getting obstructed is rare in presentation and contents as bowel and bladder peritoneum is extremely rare.

Keywords: Direct inguinal hernia, obstruction.

Copyright @ 2020: This is an open-access article distributed under the terms of the Creative Commons Attribution license which permits unrestricted use, distribution, and reproduction in any medium for non-commercial use (NonCommercial, or CC-BY-NC) provided the original author and source are credited.

INTRODUCTION

A hernia is defined as a protrusion, bulge or projection of an organ or a part of an organ through the body wall that normally contains it [1]. In an inguinal hernia the protrusion occurs through the inguinal canal. Of the entire abdominal wall hernias, 75% is contributed by the groin [2]. Inguinal hernias comprises of 95% of all groin hernias with femoral hernias comprising the remainder 5% [3]. Inguinal hernias can be either indirect (two thirds) or direct (one third). In men, indirect hernia occurs most commonly than direct type in a ratio of 2:1. Direct hernias are rare in women. The lifetime risk of strangulation of hernias is 27% in male and 3% in female [4].

Inguinal hernias can either be congenital or acquired. Increased abdominal pressure, smoking, connective tissue diseases, obesity, aging, straining during defecation, heavy weight lifting, preexisting abdominal wall weakness are the suggested risk factors for the occurrence of inguinal hernias.

CASE REPORT

History: A 64year old male patient presented to the emergency department with complaints of a painful irreducible swelling in the right groin for the

past two days with vomiting which is non projectile, on bilious and contains food particles. Pain in the swelling is acute, non-radiating, severe and continuous with a history of constipation. Patient was a known case of dilated cardiomyopathy and diabetes mellitus for the past 5 years and is on treatment for the same.

CLINICAL EXAMINATION

General examination of the patient was within normal limits. On local examination, a globular swelling of size 8*6cm in the right inguinal region extending above and medial to pubic tubercle, smooth surfaced, well defined margins, firm in consistency, irreducible, tender with a local rise of temperature, with a negative cough impulse and dull percussion note. Other hernial orifices were free and external genitalia normal. Perrectal examination revealed a normal sphincter tone with no fecal staining.

Investigations

Xray abdomen erect view (Fig.1) revealed dilated small bowel loops with air fluid levels. A right sided obstructed inguinal hernia was diagnosed with both clinical and radiological findings and an emergency exploration was planned for taking into account the necessary preoperative precautions.

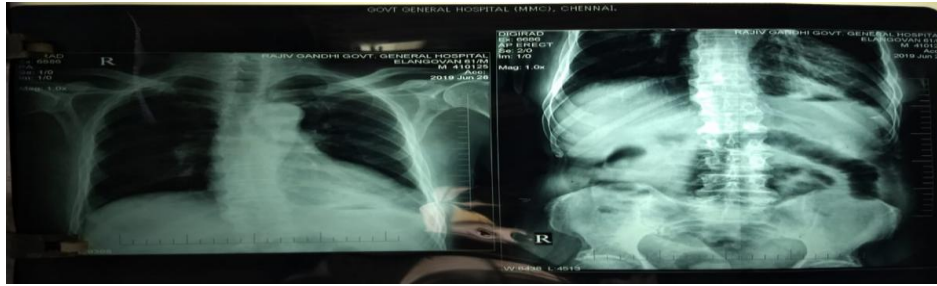

Fig-1: Xray abdomen erect view and chest xray PAView

Surgical intervention findings

A right sided inguinal scrotal incision was made. Sac and cord structures meticulously separated off. Sac found to be lying medial to the right inferior epigastric artery and hence a direct inguinal sac is confirmed [Fig.2]. Sac opened and a minimal amount of toxic fluid let off. A congested loop of small bowel along with a necrosed part of bladder peritoneum found as contents [Fig.3]. After gaining viability, the small bowel loop was reduced and the contused part trimmed off. Bladder wall integrity was checked and found to be intact. Sac is closed with 2-0 vicryl. The posterior wall defect was closed and proceeded on with herniorraphy by darnning method.

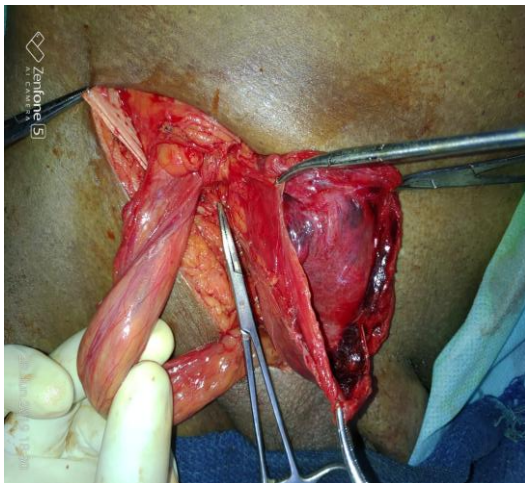


Fig-2: Showing sac medial to right inferior epigastric artery

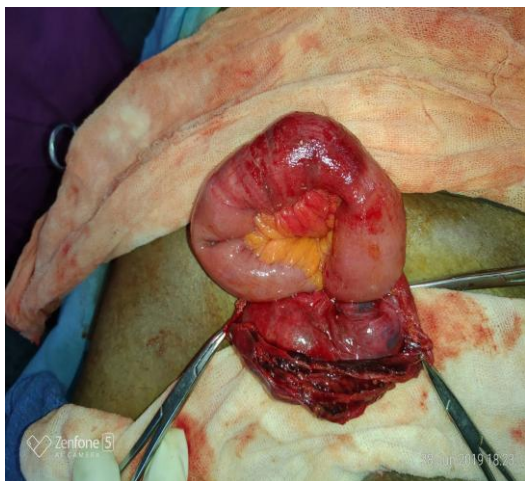

Fig-3: Showing congested small bowel loop

Post-operative period was uneventful. Patient was discharged on seventh postop day after regaining normal bowel and bladder habits and advised followup after 5 days for suture removal.

Follow up

Follow up of patient after 5 days revealed a healthy wound and patient was asymptomatic. After 5 months follow up, patient was found to have healed scar with no evidence of recurrences.

DISCUSSION

Groin hernias are classified into inguinal (direct or indirect) and femoral hernias depending on the site of occurrence. Indirect inguinal hernias are found to be protruding through the deep inguinal ring and lateral to the inferior epigastric artery. Direct inguinal hernias lie medial to the inferior epigastric artery within the hesselbach's triangle. This triangle is bounded medially by the lateral border of rectus sheath, laterally by the inferior epigastric artery and inferiorly by the inguinal ligament [5].

Hernias may be reducible (if the contents are reduced spontaneously or manually) or irreducible. Irreducible hernias may become obstructed (lumen gets obstructed with intact blood supply) or strangulated (loss of blood supply leading to ischemia). Indirect inguinal hernias have a higher risk of strangulation with direct type being the rarest one to strangulate.

Even though the neck of the direct hernia sac (fascia defect) is soft and wide enough to avoid strangulation in the early stage of the hernia, it may become fibrotic, solid and narrowed with time. This process may create a risk for a direct hernia to be incarcerated [6].

A sliding inguinal hernia is a protrusion of a retroperitoneal organ through an abdominal wall defect. Frequency of sliding hernias is estimated at 3–8% of all elective operations of inguinal hernias. Sliding hernias are supposed to be more anatomically challenging for a surgeon than an uncomplicated non-sliding inguinal hernias.

In our case, patient presented with an obstructed inguinal hernia, emergency exploration was done. On table, a direct inguinal hernia was concluded and sac opened up to look for viability of bowel and proceeded on with herniorraphy.

CONCLUSION

Although incarceration and strangulation are rare presentations in direct inguinal hernias, a long standing direct inguinal hernia may present as obstruction at acute settings. Hence old age with obstructed inguinal hernias may be of direct type and needs to be operated immediately.

However the presentation of direct inguinal hernia as obstruction is rare and with both a bowel loop and bladder peritoneum as content is even rare and hence we have reported it.

REFERENCES

1. Bax T, Sheppard BC, Crass RA. Surgical options in the management of groin hernias. *Am. Fam. Physician*, 1999;59:143–156
2. Beauchamp CM, Ever BM, Mattox KL. 19 ed. Saunders; Philadelphia: 2012. (Sabiston Textbook of Surgery: The Biological Basis of Modern Surgical Practice). 2012; 1114
3. McIntosh A, Hutchinson A, Roberts A, Withers H. Evidence-based management of groin hernia in primary care—a systematic review. *Fam. Pract.* 2000;17(October (5)):442
4. Gould J. Laparoscopic versus open inguinal hernia repair. *Surg. Clin. North. Am.* 2008; 88 (October (5)):1073–1081.
5. Brunicaudi FC, Andersen DK, Billiar TR. 10 ed. McGraw Hill Education; New York: 2014. *Schwartz's Principles of Surgery*, 1496.
6. Kulacoglu H, Kulah B, Hatipoglu S, Coskun F. Incarcerated direct inguinal hernias: a three-year series at a large volume teaching hospital. *Hernia*. 2000;4(3):145–147.