

## Research Article

### Magnetic resonance spectroscopy in neurological disorders

Mohammad Ali ElahiFar MD<sup>1</sup>, Amin Bighamian MD<sup>1</sup>, Hajar Taheri MD<sup>1\*</sup>, Ali Amini Harandi MD<sup>2</sup><sup>1</sup>Zahedan University of Medical Sciences, Iran<sup>2</sup>Shahid Beheshti University of Medical Sciences, Tehran, Iran.

#### Corresponding author

**Hajar Taheri**Email: [hajar.taheri@gmail.com](mailto:hajar.taheri@gmail.com)

**Abstract:** Magnetic resonance spectroscopy (MRS) is a non-invasive technique that can be used to measure the concentrations of different low-molecular weight chemicals. It differs from conventional Magnetic Resonance Imaging (MRI) in that spectra provide physiological and chemical information instead of anatomy. The high diagnostic specificity of MRS enables the biochemical changes that accompany various neurological disorders to be detected, as well as disease characterization, sometimes diagnosis, and monitoring. In this paper we discuss the physical basis, normal spectra, clinical applications and results interpretation of MRS in the evaluation of neurological disorder.

**Keywords:** Magnetic resonance spectroscopy, Neurological disorder

#### Introduction

Magnetic resonance spectroscopy of the brain reveals specific biochemical information about cerebral metabolites and function of the normal and pathological structures of the brain [1, 2].

MRS produces a spectra of resonances correspondent to a series of metabolites, in a system of two axes, which represent the intensity of the signal (vertical axis) and the position of the signal in the frequency scale (horizontal axis, respectively), expressed in parts per million (ppm). The spectrum is measured within a volume of interest (VOI), which is defined on the morphological multiplanar sequences previously acquired during the examination [3].

The major applications of brain MRS are :the characterization of cerebral tumors and the monitoring of their treatment (e.g., radiation necrosis versus recurrence tumor), trauma (prognosis in comatose patients), neurodegenerative processes, such as Alzheimer's and Parkinson's diseases [4], epilepsy, infection, stroke, multiple sclerosis (MS), and allows to diagnose several hereditary and acquired brain metabolic disease such as creatine deficiency syndromes, Canavan's disease, hepatic encephalopathy and adrenoleukodystrophy [5-7].

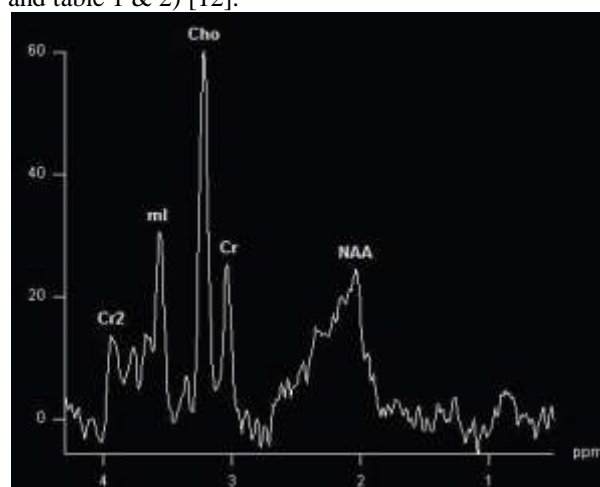
#### Physical Basis

The resonant frequencies (RF) of protons range between about 10 MHz at 0.3 T to about 300 MHz on a 7 T magnet. The advantages of higher field strength are higher signal-to-noise and better separation of the metabolite peaks. In a proton spectrum at 1.5 T, the metabolites are spread out between 63,000,000 and 64,000,000 Hertz.

The results of MRS are displayed as a spectrum of resonances (peaks) distributed along the x-

axis, labeled in parts per million (ppm). The ppm scale reads from right to left. Each metabolite appears at a specific ppm, and each one reflects specific cellular and biochemical processes. The observable MR metabolites provide powerful information, but unfortunately, many notable metabolites are not represented in brain MR spectra such as DNA, RNA, most proteins, enzymes, and phospholipids. Some neurotransmitters are absent such as acetylcholine and serotonin. Either their concentrations are very low or the molecules are invisible to MRS [8-11].

In brain MRS, the predominant metabolites are N-acetyl aspartate (NAA), choline (Cho), creatine (Cr), myo-inositol (mI), lactate (Lac), lipids (Lip), glutamine and glutamate (Glx), and amino acids. The common way to analyze clinical spectra is to look at metabolite ratios, namely NAA/Cr, NAA/Cho, and Cho/Cr. (Fig. 1 and table 1 & 2) [12].



**Figure1:** Spectrum of different metabolites in human brain

**Table 1: Concentration of brain metabolites in human bases ppm.**

ppm	Observable Proton metabolites	
	Metabolites	Properties
0.9-1.4	Lipids	Products of brain destruction
1.3	Lactate	Product of anaerobic glycolysis
2.0	NAA	Neuronal marker
2.2-2.4	Glutamine/GABA	Neurotransmitters
3.0	Creatine	Energy metabolism
3.2	Choline	Cell membrane marker
3.5	<i>Myo</i> -inositol	Glial cell marker, osmolyte hormone receptor mechanisms
1.2	Ethanol	Triplet
1.48	Alanine	Present in meningiomas
3.4&3.8	Glucose	Increased in diabetes
3.8	Mannitol	Rx for increased ICP

**Table 2: Normal and abnormal of major metabolites ratio**

Metabolite Ratios	Normal	abnormal
NAA/Cr	2.0	< 1.6
NAA/Cho	1.6	< 1.2
Cho/Cr	1.2	> 1.5

**Brain metabolites****N-acetylaspartate (NAA)**

Peak of NAA is the highest peak in normal brain. This peak is assigned at 2.02 ppm. NAA is synthesized in the mitochondria of neurons then transported into neuronal cytoplasm and along axons. NAA is exclusively found in the nervous system. It is a marker of neuronal and axonal viability and density. NAA also plays a role as a cerebral osmolyte. Absence or decreased concentration of NAA is a sign of neuronal loss or degradation. Neuronal destruction from malignant neoplasms and many white matter diseases result in decreased concentration of NAA. Increased NAA is nearly specific for Canavan disease. NAA is not demonstrated in extra-axial lesions such as meningiomas or intra-axial ones originating from outside of the brain such as metastases [13, 14].

**Creatine (Cr)**

The peak of Cr spectrum is assigned at 3.02 ppm. Total Creatine is a peak which sums up creatine and phosphocreatine. Cr is a marker of brain energy and intracellular metabolism. Concentration of Cr is relatively constant and it is considered a most stable cerebral metabolite. Therefore it is used as an internal reference for calculating metabolite ratios.

Creatine and phosphocreatine are metabolized to creatinine. Creatine is not produced in the brain, so a wide range of liver or renal diseases can lead to a decrease in the Cr peak. In brain tumors, there is a reduced Cr signal. Gliosis may cause minimally increased Cr due to increased density of glial cells (glial proliferation) [14, 15].

**Choline (Cho)**

Its peak is assigned at 3.22 ppm and represents the sum of choline and choline-containing compounds (e.g. phosphocholine). Cho is a marker of cellular membrane turnover (phospholipids synthesis and degradation) reflecting cellular proliferation. In tumors, Cho levels correlate with degree of malignancy reflecting of cellularity. Increase Cho may be seen in infarction (from gliosis or ischemic damage to myelin) or inflammation (glial proliferation) hence elevated Cho is nonspecific. [14].

**Lactate (Lac)**

Peak of Lac is not seen or is hardly visualized in the normal brain. The peak of Lac is a doublet at 1.33 ppm. A small peak of Lac can be visible in some physiological states such as newborn brains during the first hours of life. Lac is a product of anaerobic glycolysis so its concentration increases under anaerobic metabolism such as cerebral hypoxia, ischemia, seizures and metabolic disorders (especially mitochondrial ones). Increased Lac also occurs with macrophage accumulation (e.g. acute inflammation). Lac also accumulates in tissues with poor washout such as cysts, normal pressure hydrocephalus, and necrotic and cystic tumors.

**Lipids (Lip)**

Lipids (0, 8-1,5 ppm) can be present in normal conditions, these are components of cell membranes. Presence of lipids may result from improper voxel selection causing voxel contamination from adjacent fatty tissues (e.g. fat in subcutaneous tissue, scalp and diploic space). Lipid can be seen when there is cellular

membrane breakdown or necrosis such as in metastases or primary malignant tumors.

#### **Myoinositol (Myo)**

Myo is a simple sugar assigned at 3.56 ppm. Myo is considered a glial marker because it is primarily synthesized in glial cells, almost only in astrocytes. It is also the most important osmolyte in astrocytes. Myo may represent a product of myelin degradation. Elevated Myo occurs with proliferation of glial cells or with increased glial-cell size as found in inflammation. Myo is elevated in gliosis, astrocytosis and in Alzheimer's disease.

#### **Alanine (Ala)**

Ala (at 1.48 ppm) is an amino acid. Increased concentration of Ala may occur in oxidative metabolism defects. It can be found in abscesses, meningioma (specific in tumors), or dying tissue.

#### **Glutamate-Glutamine (Glx)**

Glx(2,05-2,50 ppm): is a composite peaks from glutamate (Glu), Glutamine (Gln) and gamma-aminobutyric acid (GABA). These metabolite peaks are difficult to separate at 1.5 T. Glutamate is the main excitatory neurotransmitter in the central nervous system, and also the most abundant amino-acid in the diet. Elevated concentration of Gln is found in a series of neurological disorders such as hepatic encephalopathy epilepsy, schizophrenia [14,16,17].

### **Main clinical applications**

#### **Brain masses**

The most common clinical application of MRS is the evaluation of brain masses—most importantly, intra axial masses.

MRS can help to grade tumors and to differentiate primary CNS neoplasms from metastasis. It also plays an important role to distinguish a neoplasm from mimics such as subacute ischemic infarction and multiple sclerosis. The final application of MRS is differentiating of radiation necrosis from recurrent tumor [18].

MRS give the information related to the extent of the lesion and infiltration into surrounding parenchyma that appears normal on MRI. Multi-voxel spectroscopy is best to detect infiltration of malignant cells beyond the enhancing margins of tumors. Particularly in the cerebral glioma, elevated choline levels are frequently detected in edematous regions outside the enhancing mass [19, 20].

MRS can be used to determine the degree of malignancy. With increase grade of malignancy, NAA and creatine decrease, and lactate, choline and lipids increase. NAA decreases as tumor growth displaces or destroys neurons. Very malignant tumors have high metabolic activity and deplete the energy stores, resulting in reduced creatine. In hypercellular tumors with rapid growth elevate the choline levels. Lactate

appears when tumors outgrow their blood supply and start utilizing anaerobic glycolysis and lipids are found in necrotic portions of tumors. Finally, MRS can use for accurate grading of the malignancy for biopsy, it detect the most metabolically active part of the tumor.

A common clinical problem is distinguishing radiation necrosis from tumor recurrence. Elevated choline is a marker for recurrent tumor. Radiation change generally exhibits low NAA, creatine, and choline on spectroscopy. If radiation necrosis is present, the spectrum may reveal elevated lipids and lactate [12, 18].

#### **Cerebral ischemia and infarction:**

MRI with diffusion weighting is the technique of choice in the evaluation of acute ischemic stroke [21]. When the brain becomes ischemic, it switches to anaerobic glycolysis and lactate accumulates. MRS changes include a decrease in NAA that occurs over several days after the stroke. Lactate rises early after the insult in the acute phase (<24 hours) and may remain high over a long period into the chronic phase (>7 days) [19, 22]. Other findings are increasing the choline and lipids levels and reducing creatine [12].

In global hypoxic-ischemic insults, NAA and lactate levels in gray matter may have prognostic significance studies have shown [23,24].

#### **Trauma**

MRS is not routinely used in the acute setting of head injuries. CT and MR imaging reveal the fractures and intracranial hemorrhage that need emergent surgical intervention. When the patient has stabilized, MRS can help to evaluate the degree of neuronal injury and predict patient outcomes. Especially in the case of diffuse axonal injury; imaging often underestimates the degree of brain damage. The presence of any lipid or lactate indicates a worse prognosis. Clinical outcome correlates inversely with the NAA/Cr ratio [25].

#### **Infectious diseases**

Brain abscesses destroy or displace brain tissue, so NAA is not present. Lactate, cytosolic acid, alanine, and acetate are characteristic metabolites in bacterial abscesses. A lipid/ lactate resonance and absence of other metabolites is seen in toxoplasmosis. A similar increase in lipid and lactate to that seen in toxoplasmosis may also be seen in necrotic portions of lymphoma and other tumors, but solid tumor in lymphoma shows increased Cho levels [26, 27].

When patients with AIDS start developing cognitive deficits and AIDS dementia complex, the MRS become positive with elevated choline and reduced NAA. Choline is the best marker for the white matter abnormalities, and the extent of NAA depletion correlates directly with the degree of dementia. MRS is also very helpful in following patients that were threatened with anti-viral drugs.

Although MRS have a high sensitivity in detecting brain involvement in HIV related diseases, but some studies have shown a poor specificity in differential diagnosis of HIV brain lesions [28].

In common focal brain lesions in AIDS patients, the most helpful marker is choline, which is elevated in lymphoma, but low in toxoplasmosis, tuberculoma, and cryptococcoma. The spectrum for PML may be similar to lymphoma, but the imaging features are distinctly different and PML may have elevated myo-inositol [12].

### Multiple sclerosis

MS is the most common demyelinating lesion. MRS changes that occur during the development of an acute MS plaque include elevation of Cho and a decline in NAA. After the acute phase these metabolic changes can return to normal. However, MRS of a chronic plaque may reveal a permanent decline in the NAA along with a persistent rise of the Cho. NAA in normal-appearing white matter may also be reduced in patients with longstanding MS [29].

### Pediatric metabolic disorders

MRS has important role in diagnosing and monitoring of metabolic disorders. Compared to the adult, newborns have much less NAA, and increased choline and myo-inositol.

### Hepatic encephalopathy

Hepatic encephalopathy is characterized by markedly reduced myo-inositol. Choline and increase in glutamine. Liver failure results in excess ammonia in the blood. Ammonia is a neurotoxin and causes increased conversion of glutamate to glutamine. Similar changes are seen in Reye's syndrome. The metabolic changes of hepatic encephalopathy increase after TIPS shunt procedure, and they regress to normal after successful liver transplantation [12].

### Neurodegenerative Disorders

Neurodegenerative disorders are a diverse set of conditions with varied etiologies. Patients with Alzheimer disease show reduced levels of NAA along with a significant increase in myo-inositol. Similar changes may be seen in frontotemporal dementia but in a different distribution [30], myo-inositol is not elevated in other adult dementia, so it is a helpful to distinguish Alzheimer's disease from the other causes of dementia [12].

### Conclusion

MRS should be performed as an adjunct to MRI gain additional information for a reliable clinical diagnosis: while conventional MRI provides anatomical images of the brain, MRS provides functional information related to its underlying dynamic physiology.

### References

1. Scheau C, Preda EM, Popa GA, Gherghus AE, Capsa RA and Lupescu IG; Magnetic Resonance Spectroscopy – a non-invasive method in evaluating focal and diffuse central nervous system disease. *Journal of Medicine and Life*, 2012; 5(4):423-427.
2. Salvolini U and Scarabino T; High-Field Brain MRI: Use in Clinical Practice. New York: Springer-Verlag Berlin Heidelberg. 2006:52-56.
3. Thomas MA, Ryner LN, Mehta MP, Turski PA and Sorenson JA; Localized 2D J-resolved H MR spectroscopy of human brain tumors in vivo. *J. Magn. Reson. Imaging*, 1996; 6: 453–459.
4. Ross B and Bluml S; Magnetic resonance spectroscopy of the human brain. *Anat. Rec.*, 2001; 265(2): 54–84.
5. Grodd W, Krageloh-Mann I *et al.*; In vivo assessment of N-acetylaspartate in brain spongy degeneration (Canavan's disease) by proton spectroscopy. *Lancet*, 1990; 336: 437–438.
6. Bianchi MC, Tosetti M, Fornai F *et al.*; Reversible brain creatine deficiency in two sisters with normal blood creatine level. *Ann. Neurol.*, 2000; 47: 511–513.
7. Ross BD, Jacobson S, Villamil F *et al.*; Subclinical hepatic encephalopathy: proton MR spectroscopic abnormalities. *Radiology*, 1994; 193: 457–463.
8. Rubaek Danielsen E, Ross B; Magnetic resonance spectroscopy diagnosis of neurological disease, New York, Marcel Dekker, Inc. 1999.
9. Zimmerman RA and Wang ZJ; The value of proton MR spectroscopy in pediatric metabolic brain disorders. *AJNR Am. J. Neuroradiol.* 1997; 18: 1872–9.
10. Burtscher IM and Holtas S. Proton MR spectroscopy in clinical routine. *J Magn Reson Imaging* 2001;13:560–7.
11. Novotny EJ Jr., Fulbright RK, Pearl PL *et al.*; Magnetic resonance spectroscopy of neurotransmitters in human brain. *Ann. Neurol.*, 2003; 54: S25–31.
12. Howe FA, Barton SJ, Cudlip SA *et al.*; Metabolic profiles of human brain tumors using quantitative in vivo 1H magnetic resonance spectroscopy. *Magnetic Resonance in Medicine*, 2003; 49:223-32.
13. Kreis R, Geissler A, Ernst T, Villamil F and Ross BD; Reversal of chronic hepatic encephalopathy (CHE) by liver transplantation as defined by localized MRS, Presented at the Ninth International Congress of Liver Diseases, Basel, Switzerland, 1992.
14. Haga KK, Khor YP, Farrall A and Wardlaw JM; A systemic review of brain metabolite changes, measured with (1)H magnetic resonance spectroscopy, in healthy aging. *Neurobiol. Aging*, 2009; 30:353-363.
15. Lowry OH, Berger SJ, Chi MM *et al.*; Diversity of metabolic patterns in human brain tumors: High-energy phosphate compounds and basic composition. *J. Neurochem.*, 1977; 29: 959 e77.
16. Wong CG, Bottiglieri T and Snead OC; 3rd. GABA, gamma-hydroxybutyric acid, and neurological disease. *Ann. Neurol.*, 2003; 54 Suppl 6:S3-12.

17. Danielsen ER; Proton MRS in Advanced neuro Imaging: diffusion, perfusion, spectroscopy, topic 8, ESMRMB. School of MRI, 2011.
18. Atlas S W; Magnetic Resonance Imaging of the Brain and Spine. Philadelphia: Lippincott Williams & Wilkins. 2009:1836-1870.
19. Barker PB; Fundamentals of MR Spectroscopy. In: Gillard JH, Waldman AD, Parker PB, eds. Clinical MR neuroimaging: diffusion, perfusion, and spectroscopy. Capetown: Cambridge University Press, 2005:1–17.
20. Burtscher IM and Holtas S; Proton magnetic resonance spectroscopy in brain tumors: clinical applications. *Neuroradiology*, 2001; 43: 345–52.
21. Maheshwari SR, Fatterpekar GM, Castillo M, Mukherji SK; Proton MR spectroscopy of the brain. *Semin Ultrasound CT MR*, 2000; 21: 434–51.
22. Castillo M, Kwock L and Mukherji SK; Clinical applications of proton MR spectroscopy. *AJNR Am. J. Neuroradiol.*, 1996; 17:1–15.
23. Cappellini M, Rapisardi G, Cioni ML and Fonda C; Acute hypoxic encephalopathy in the full-term newborn: correlation between magnetic resonance spectroscopy and neurological evaluation at short and long term. *Radiol. Med.*, 2002; 104: 332–40.
24. Roelants-Van Rijn AM, Van der Grond J, De Vries LS and Groenendaal F; Value of (1) H-MRS using different echo times in neonates with cerebral hypoxia-ischemia. *Pediatr. Res.*, 2001; 49: 356–62.
25. Narayana PA; Magnetic resonance spectroscopy in the monitoring of multiple sclerosis. *J. Neuroimaging*, 2005; 15 (4 ): 46S–57.
26. Chang L and Ernst T; MR spectroscopy and diffusion-weighted MR imaging in focal brain lesions in AIDS. *Neuroimaging Clin. N. Am.*, 1997; 7: 409–26.
27. Chang L, Cornford ME and Chiang FL *et al.*, Radiologic-pathologic correlation. Cerebral toxoplasmosis and lymphoma in AIDS. *AJNR Am. J. Neuroradiol.*, 1995;16:1653–63
28. Chinn RJS, Wilkinson ID and Hall-Craggs MA *et al.*; Toxoplasmosis and primary central nervous system lymphoma in HIV infection: diagnosis with MR spectroscopy. *Radiology*, 1995; 197: 649–54.
29. Miller DH, Thompson AJ and Filippi M; Magnetic resonance studies of abnormalities in the normal appearing white matter and grey matter in multiple sclerosis. *J Neurol* 2003; 250(12): 1407–1419.
30. Valk J, Barkhof F and Scheltens P; Magnetic resonance in dementia. Berlin Heidelberg, Springer-Verlag, 2002.