

## Research Article

### Value of sonographic hydrotubation using agitated saline as a screening test for tubal patency

A.K. P. Ranaweera<sup>1</sup>, M. Batcha<sup>2</sup>, H. Kalansooriya<sup>3</sup>

<sup>1</sup>Senior Registrar in Obstetrics and Gynaecology, National Hospital Sri Lanka, Colombo

<sup>2</sup>Specialist in subfertility, National Hospital Sri Lanka, Colombo

<sup>3</sup>Consultant Obstetrician and Gynaecologist, Teaching Hospital Mahamodara, Galle.

#### Corresponding author

A.K. P. Ranaweera<sup>1</sup>

Email: [akpmfc@gmail.com](mailto:akpmfc@gmail.com)

**Abstract:** Establishing tubal patency is necessary for the treatment of subfertility. Hysterosalpingo contrast sonography (HyCoSy) is one of recommended screening test but is expensive. Vaginal sonographic hydrotubation using agitated saline and size 8 Foley catheter can be used to reduce the cost. The objective of the study is to determine the diagnostic accuracy of vaginal sonographic hydrotubation using agitated saline as a screening test for tubal patency. 42 patients with infertility were evaluated for tubal patency. Vaginal sonographic hydrotubation was performed using a size 8 Foley urinary catheter and agitated saline solution as a contrast medium to assess tubal patency. Results were compared with findings at laparoscopy and chromotubation performed independently. All patients received prophylactic antibiotics prior to procedure. The findings of both methods agreed in 71 out of 84 tubes (concordance, 84.5%). The sensitivity for tubal patency was 84.9% and the specificity 81.8%. The positive predictive value 96.8% and the negative predictive value was 45.0%. The pretest probability was 86% and posttest probability 96%. Adverse events included moderate to severe abdominal pain in two patients and mild discomfort during procedure. No infectious complications recorded. From the study it can be concluded that vaginal sonographic hydrotubation utilizing agitated saline as a contrast medium and a size 8 Foley urinary catheter is a reliable, simple and well-tolerated method to assess tubal patency in an outpatient setting. In addition, detection of other pathologies related to subfertility is also possible at the time of screening.

**Keywords:** Subfertility; laparoscopy; agitated saline; hydrotubation; sonosalpingography; tubal patency.

#### INTRODUCTION

Subfertility is a commonly encountered problem in gynaecological practice, affecting 10-15% of couples' worldwide [1]. Tubal disease accounts for 15 – 20% of cases of primary subfertility and approximately 40% of secondary subfertility [2]. There is limited information on the problems of subfertility in Sri Lanka due to the paucity of well-conducted studies. The only community based study aimed at studying the prevalence and risk factors for primary and secondary subfertility was carried out in 1994 in the district of Colombo [3]. In this study, primary subfertility was found to be 4.1% with secondary infertility being 16.1%. It is recommended that women who are being investigated for subfertility should be offered a test for tubal patency [4]. Tubal patency can be assessed by laparoscopy (Jacobaeus - 1910 Palmer - 1947), hysterosalpingography (Carey -1914) or the newer technique known as hysterosalpingo contrast sonography (Deichert -1993).

The laparoscopy and dye test is considered currently as the gold standard for the evaluation of tubal patency [5]. It allows visual inspection of internal organs of abdomen and pelvis and excludes other problems like endometriosis, fibroids, ovarian cysts and adhesions. Abnormalities detected during the procedure may be dealt with at the same time. Diagnostic

laparoscopy is associated with approximately 3% risk of minor complications such as nausea and shoulder tip pain; the risk of major complications such as bowel injury or injury to a blood vessel is about 0.06 - 0.2% [6]. It also exposes large numbers of healthy women to the hazards of anaesthesia.

Hysterosalpingography (HSG) is often the primary investigation of tubal patency. It can be done as an outpatient procedure and without any anaesthesia. As a test of tubal patency, HSG has a sensitivity of 0.65 (95%CI 0.50-0.78) and a specificity of 0.83 (95% CI 0.77-0.88) [7]. However, HSG is associated several disadvantages including use of clinical radiography time, contrast medium reactions, pelvic discomfort and vasovagal reactions [8]. Vaginal sonographic hydrotubation initially developed by infusing warm saline transcervically in to the uterine cavity and detecting fluid in the pouch of Douglas by transvaginal ultrasound (TVS), indicating patency of at least one Fallopian tube [9]. Evaluate individual tubes during TVS is difficult without an ultrasound contrast medium. Initially, injection of saline followed by injection of air and detecting passage of air bubbles through the Fallopian tubes was used. Few studies has evaluated this technique with laparoscopy [10].

A newer technique was developed known as hysterosalpingo contrast sonography (HyCoSy) which uses an ultrasound contrast medium (Echovist®200) instead of saline to visualize tubes during the same procedure. Several groups have compared HyCoSy screening with either hysterosalpingography or laparoscopy and from these studies; the sensitivity was in the region of 47-90% and specificity 87-100% [11-13].

The effective radiation dose from conventional hysterosalpingogram (HSG) is about 1 mSv, which is about 10 times the normal chest X ray (0.1 mSv) [14]. Nobel laureate best known for his work on the physiological and genetic effects of radiation (X-ray mutagenesis), Muller H. J. stated his views regarding irradiation of the gonads 'all doses, no matter how small, must be considered as carrying some risk of producing mutation' [15]. In Sri Lanka, many hospitals do not have all the protective gear for the person who performs HSG. There is an increased risk of developing cataract if protective eyewear is not worn by persons who are exposed to x-rays frequently [16]. Contrast allergies to iodine compounds are possible in this procedure especially in patients with a history of anaphylaxis [17].

HyCoSy Using a size 8 Foley catheter and agitated saline this cost can be reduced significantly making this technique feasible to use in a limited resources setup. Chena *et al* [18] compared this method with HSG and only 15 cases were compared with laparoscopy and dye test, a drawback that the investigators themselves acknowledged. Thus to test the accuracy of this method confidently it should be compared with the gold standard test.

Use of agitated saline to enhance echogenicity in ultrasonography is not a new concept. It was first described in the late 1960s [19]. Cardiologists use it frequently during echocardiography to confirm the presence of persistence foramen ovale (PFO) in adults (Bubble Study). In this procedure, they inject agitated saline to a peripheral vein and perform echocardiography [20]. Since this procedure has been in use for the last forty years its safety is well established. Injection of saline or other solutes to uterine cavity for diagnostic and therapeutic purposes are widely used. HSG, laparoscopic dye test and saline hydrotubation are few examples [21]. Thus, use of agitated saline for sonographic hydrotubation can be considered safe.

The present work is aimed to determine the diagnostic accuracy of vaginal sonographic hydrotubation using agitated saline as a screening test for tubal patency along to describe the other pathologies detected during vaginal sonographic hydrotubation and to determine the acceptability of vaginal sonographic hydrotubation in patients.

## EXPERIMENTAL SECTION

### Study population & its recruitment

The study was performed on forty-two subfertile women who were admitted to the ward for laparoscopy and dye test as planned from the clinic. The study was conducted at two institutions Unit 3, Teaching Hospital Mahamodara- Galle from September 2009 to April 2010 (12 patients), and Professorial Unit, National Hospital Colombo from May 2010 to April 2011 (30 patients). Informed written consent was obtained from all study subjects. Patients with vaginal and/or cervical discharge other than physiological discharge at the time of procedure (3 patients), patients with evidence or suspicion of candidiasis or any other vulval, vaginal and cervical infections (4 patients), patients in whom pregnancy could not be excluded with certainty (1 patient) and patients in whom speculum examination could not be performed due to pain (2 patients) were excluded from the study.

### Procedure of vaginal sonographic hydrotubation using agitated saline.

The procedure done at the first half of the cycle. Amoxicillin 500mg and metronidazole 400mg stat dose given prior to procedure and no analgesic medication given. Patients were kept on the dorsal position. Cusco's speculum examination of the vaginal wall and cervix was done to exclude any contraindication for the procedure.

After disinfecting the vagina and cervix with chlorhexidin, Size 8 Foleys catheter with a semi-rigid introducer (Figure 1) was inserted into uterine cavity transcervically using a sponge forcep. In case of difficulty of insertion, the cervix was grasped with a tenaculum to straighten the cervical canal and the catheter was re introduced. Then the stylet was removed and the balloon filled with 1.5ml to 2ml of sterile water. If the inflation of the balloon was painful, the balloon was deflated and then slowly inflated again. The placement of the balloon towards the internal os of the cervical canal was secured with gentle traction, which was maintained throughout the procedure. Next the speculum was taken off and 6Hz vaginal ultrasound probe was inserted and the correct position catheter was confirmed (Figure 2). During the initial scan the uterine position, endometrial thickness and morphology as well as ovarian morphology were noted. Then 5ml of saline injected through the Foley catheter and to visualize the shape of the uterine cavity and any other abnormalities (Figure 3). 20ml syringe containing 10ml of saline and 10ml of air will be shaken vigorously to make micro bubbles (Figure 4) immediately prior to injection. This mixture injected through the catheter slowly taking care to tilt the syringe downwards to avoid injection of air. The micro-bubbles produce bright scintillating echoes on ultrasound scan and which become easily visible as they pass through the tubes (Figure 5).

The patency of the uterine tube was examined by observing the passage of agitated saline through the tube. Each tube was examined separately and traced to the peri-ovarian space for the appearance of air bubbles into the peritoneal cavity. The tube considered patent only if the flow of air bubbles was seen at the distal end of the tube (Figure 6). If necessary, the procedure was repeated to exclude tubal spasm. If the repeated injections gave similar results, the tube was considered occluded. Collection of saline solution into the pouch of Douglas was also noted (Figure 7).

After tubal patency evaluation, the balloon was deflated and the catheter removed. Findings were documented in the data collection sheet and the clinic record book but not in the BHT to conceal the findings from the person who is doing laparoscopy and dye test. The patients were asked to monitor signs of pelvic infection and to contact the author if such occurred.

#### **Diagnostic Laparoscopy and Dye test.**

Most patients underwent laparoscopy and dye test the following day as planned earlier but two patients the surgery was postponed due to unavailability of theatre time and was done on a later date. Laparoscopy and chromotubation was performed under general anesthesia by a different operator other than the investigator who performed the sonography test and was ignorant of the findings. Methylene blue injection through a cone-shaped adapter fixed tightly to the external os of cervix with a tenaculum was used for chromotubation during laparoscopy. Tube considered patent only after demonstration of spilling of dye from fimbrial end by the operator. The findings were documented as usual.

#### **Ethical considerations**

Ethical Clearance for the study obtained from the Ethics Review Committee of National Hospital Colombo.

#### **Data Analysis**

Data were analyzed EpiInfo version 3.5.3.

## **RESULTS**

#### **Characteristics of the study population**

The study population comprised 42 subfertile women. Overall, the mean (SD) age was 31.95 (3.8) years, with a range of 24–39 years. Mean (SD) duration of infertility was 2.98 (1.9) years, range 1–10 years. Subfertility was reported as primary and secondary by 38 (90.5%) and 4 (9.5%), respectively. Age distribution of study subjects with regards to type of subfertility is shown in figure 1.

A unilateral or bilateral tubal occlusion was observed in seven patients by laparoscopy and chromotubation (Table 1).

Tubal factor subfertility in this study population was six (15.7%) in primary subfertility group and one (25%) in secondary subfertility group (Table 1).

#### **Value of vaginal sonographic hydrotubation using agitated saline as a screening test**

42 patients were studied by both methods. Thus, altogether 84 uterine tubes were examined. (Table 2). Saline sonographic hydrotubation (SSH) showed patency in 64 (76.2%) tubes and laparoscopy in 73 (86.9%) tubes (Table 2). When there were equivocal findings by either test the patency of the doubtful tube considered to be occluded. The findings of both methods agreed in 71 out of 84 tubes (concordance, 84.5%). The tubal patency found in 64 tubes by SSH was confirmed by laparoscopy in 62 tubes (positive predictive value, 96.8%). Tubal occlusion found in 20 tubes by SSH was confirmed by laparoscopy only in 9 tubes (negative predictive value, 45.0%). There were eleven false positive and two false negative findings. There were thirteen tubes where there was disagreement with laparoscopy findings (Table 2). The sensitivity of SSH in diagnosing tubal patency was 84.9% and the specificity 81.8% (Table 3). The likelihood ratio for open tubes was 4.67; the pretest probability for tubal patency was 86% and posttest probability 96% (Table 4).

#### **Detection of other pathologies during saline sonography and laparoscopy.**

SSH revealed two patients with sub-mucosal fibroids distorting the cavity, which were not detected at the time of laparoscopy. Two other patients detected to have multiple fibroids and one patient with large fundal fibroid during SSH were confirmed by laparoscopy.

There were five patients with bilateral polycystic ovaries detected during SSH and were suspected in laparoscopy by the appearance and increase size of the ovaries.

Six patients were diagnosed to have mild to severe endometriosis out of which two patients had significant adhesions and were treated during laparoscopy. These were not detected during SSH. One patient who was detected to have a left side endometrioma at the time of SSH was confirmed and treated during laparoscopy (Figure 9).

One patient with bilateral tubal occlusion had evidence of pelvic inflammatory disease with significant adhesions during laparoscopy.

#### **Procedure related complication**

The insertion of the Foley catheter into the uterine cavity was successful in all cases. Use of a tenaculum to straighten the cervical canal was needed only for a handful (6 patients) of patients. Frequently, only 5-10 ml of agitated saline solution was required to demonstrate the patency of the tube. Two patients, one

with bilateral tubal occlusion and the other with distal end tubal occlusion complained of moderate to severe pain during the procedure and were given analgesics for pain relief after the procedure. Other patients did not

complained of significant pain needing analgesics. None had infective complications during the study period.

**Table 1. Number of patients with tubal occlusion as diagnosed by laparoscopy and chromotubation according to the type of subfertility.**

Tubal Patency	Type of Subfertility	
	Primary (%)	Secondary (%)
Both tubes patent	32(84%)	3(75%)
One tube patent	3(0.7%)	0(0%)
Both tubes block	3(0.7%)	1(25%)
Total	38	4

**Table 2 Laparoscopic findings in 13 tubes for which the saline sonography findings were different.**

No of Patients	No of tubes	Saline sonography findings	Laparoscopy findings
2	2	Both tubes Patent	Unilateral occlusion
5	5	Unilateral occlusion	Both tubes patent
3	6	Bilateral occlusion	Both tubes patent

**Table 3 Accuracy of saline sonographic hydrotubation in diagnosing tubal patency\***

Saline sonography	Laparoscopy and chromopertubation		
	Patent	Not Patent	Total
Patent	62	2	64
Not Patent	11	9	20
Total	73	11	84

Sensitivity =  $62 / (62+11) \times 100\% = 84.93\%$        $PPV^{\dagger} = 62 / (62+2) \times 100\% = 96.88\%$

Specificity =  $9 / (9+2) \times 100\% = 81.82\%$        $NPV^{\ddagger} = 9 / (9+11) \times 100\% = 45.0\%$

Overall concordance =  $71/84 \times 100\% = 84.52\%$

\* All numbers refer to number of uterine tubes;  $^{\dagger}PPV$ =Positive Predictive Value for tubal patency;

$^{\ddagger}NPV$ = Negative Predictive Value for tubal non patency

**Table 4 Diagnostic validity of saline sonographic hydrotubation in assessment of tubal patency studied by using the likelihood ratio and posttest probability**

Likelihood ratio	=	<u>Sensitivity</u>	=	84.93	=	4.6
		1-Specificity		100-81.82		
Pretest probability	=	<u>Disease positive</u>	=	73	=	0.86
		Total Patients		84		
Pretest odds	=	<u>Pretest probability</u>	=	0.86	=	6.14
		1-Pretest probability		1-0.86		
Posttest odds	=	Pretest odd x Likelihood ratio	=	6.14x4.6	=	28.25
Posttest probability	=	<u>Posttest odds</u>	=	28.25	=	0.96
		1+Posttest odds		1+28.25		

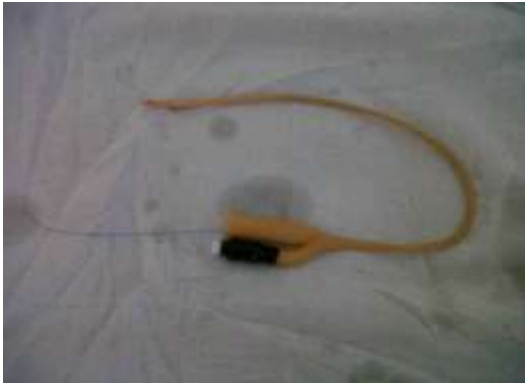

Figure 1. Size 8 Foley catheter with stylet

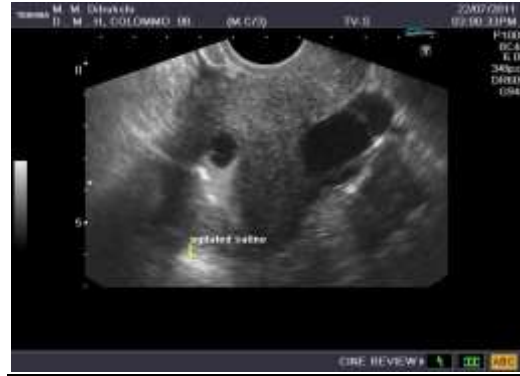

Figure 5. Micro-bubbles produce bright scintillating echoes on ultrasound scan

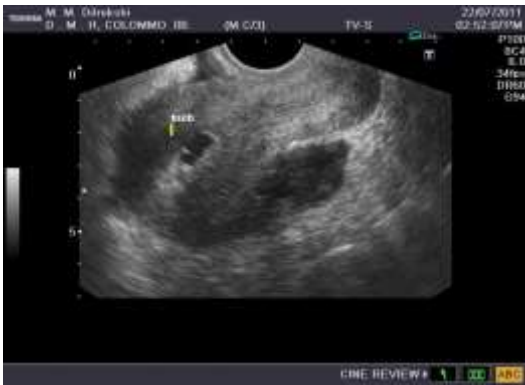

Figure 2. Inflated bulb seen in the uterine cavity

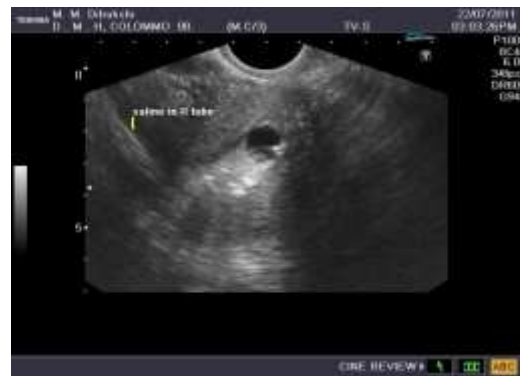

Figure 6. Passage of saline seen through right tube

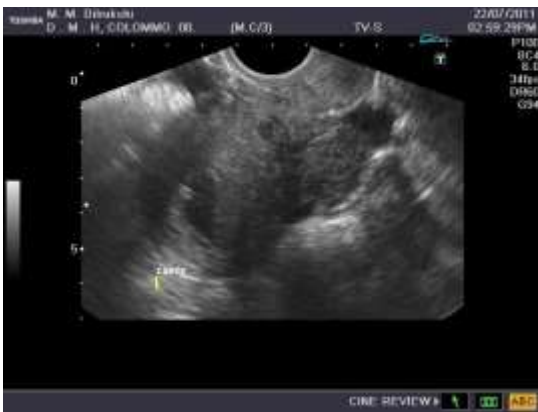

Figure 3. Uterine cavity after infusion of 5ml of saline

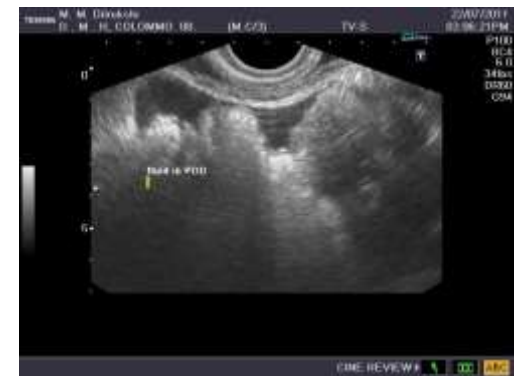

Figure 7. Collection of saline in Pouch of Douglas

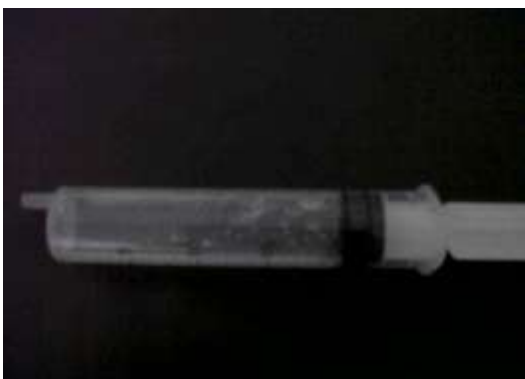

Figure 4. 20ml Syringe just after vigouros shaking with micro-bubbles

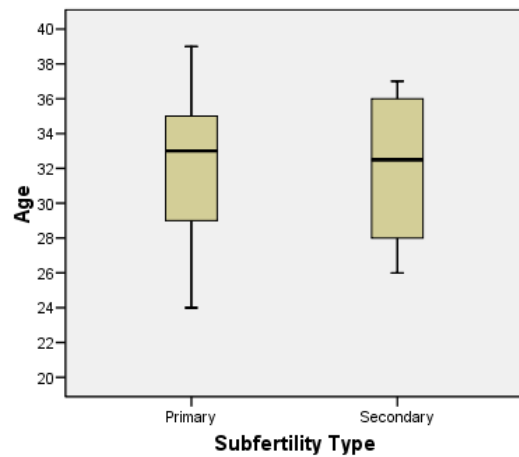
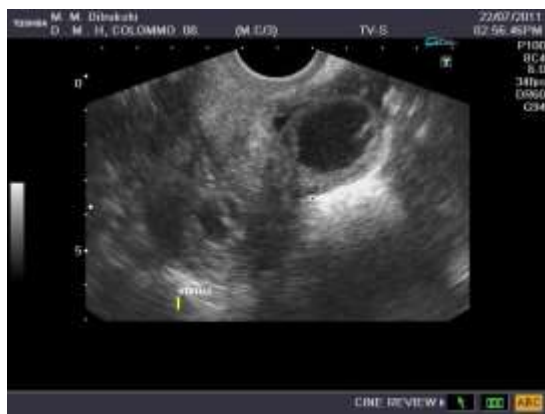

Figure 8. Age distribution within type of subfertility



**Figure 9. Endometrioma detected during procedure**

## DISCUSSION

Subfertility is a commonly encountered problem in modern gynaecological practice. With more women, delaying their pregnancies and advancing age of first pregnancy will compound this problem further [22]. In our study, more than 70% were above 30 years of age and more than 30% were above 35 years of age.

Even though the proportion of patients with tubal disease (Primary – 15.7% and Secondary – 25%) were somewhat similar to reported prevalence of tubal disease in primary (15 – 20%) and secondary (30-40%) subfertility (2), prevalence of tubal disease in our study cannot be compared due to limited number of patients studied.

### Value of vaginal sonographic hydrotubation using agitated saline as a screening test

In the initial workup of women with subfertility, establishing patency of Fallopian tubes is necessary before embarking on further management. Until recently, the assessment of tubal patency in the primary care setup was done by HSG. In recent years, use of ultrasonography in this context is becoming popular.

In our study by using agitated saline as an ultrasound contrast medium, concordance was 84.5% with laparoscopy. This is comparable to the only study which used agitated saline as the contrast medium done in South Africa by Cenia *et al.* [18]. They reported a concordance of 85% with HSG. In their study only 15 cases were compared with laparoscopy thus concordance to laparoscopy was not given.

The other studies which used saline followed by air injection to visualize Fallopian tubes with TVS, had concordance of 83% to 89% with laparoscopy [23-27].

In our study the positive predictive value for tubal patency was high (96.8%), whereas the accuracy in finding out tubal occlusion was lower (negative predictive value 45%). This indicates that vaginal

sonographic hydrotubation using agitated saline as a contrast medium is a reliable method to find a patent tube. The high sensitivity (84.9%) and specificity (81.8%) of the method in diagnosing tubal patency obtained in the present study also support the role of this method as a reliable screening test to assess tubal patency.

In order to further validate the usefulness of sonosalpingography in the diagnostic work-up of infertility, the likelihood-ratio (LR) for tubal patency was calculated. Conceptually, LRs are among the most complicated characteristics of a diagnostic test [28].

LR is a semiquantitative measure of the performance of diagnostic test, which indicates how much a diagnostic procedure modifies the probability of the disease. LRs assist in putting the value of testing in proper perspective. LRs are not affected by the prevalence of the disease in the population studied. The likelihood of a positive test result (LR+) indicates the likelihood of abnormal test result in a patient with the disease, over the likelihood of an abnormal test result in a patient without the disease. The likelihood of a negative test result (LR-) indicates the likelihood of a normal test result in a patient with the disease, over the likelihood of a normal test result in a patient without the disease. Calculation of LRs yields a score that allows categorization of test results: an LR+ of 2-5 indicates a fair clinical test, 5-10 is good, and >10 is excellent. An LR- of 0.5-0.2 indicates a fair clinical test, 0.2-0.1 is good, and <0.1 is excellent [29]. The LR+ ratio obtained in our study 4.67 is close to the value 5, which is generally accepted value for clinical application. The LR- value of 0.18 indicates it's a fair clinical test.

In the present study, we used this value to calculate the posttest probability, which indicates by how much SSH will increase the pretest probability of tubal patency. The pretest probability obtained, 86%, was increased by SSH – a posttest probability of 96% in case of a normal finding.

### Detection of other pathologies during saline sonography

Using ultrasound scan gives an added advantage of detecting uterine pathologies which may contribute to subfertility, which cannot be detected by HSG [30]. Diagnosis of uterine cavity abnormalities by saline infusion sonography (SIS) is well established [31-32]. The method we studied, gives an opportunity to examine the uterus, the cavity and both ovaries at the time of screening for tubal patency. This allows for a better understanding of the problem of subfertility in the woman being investigated. We detected two cases of sub-mucosal fibroids distorting the cavity, one case of endometrioma, several cases of bilateral polycystic ovaries during SSH. The laparoscopy did not detect the two cases of sub-mucosal fibroid.

Ayida and coworkers [8] have recently suggested that laparoscopy and chromotubation have no place as a primary test for tubal patency in a 'non-complicated' patient (i.e. a patient without a history of pelvic inflammatory disease (PID), endometriosis or genital tract anomaly). The odds of finding fertility related pathology by laparoscopy in these patients are relatively low [33]. Accordingly, in our material, mild to severe endometriosis was detected in six patients out of 42 and peri-tubal adhesions due to PID in one patient. These were not detected during SSH. No other pathological findings relevant to fertility were detected by laparoscopy in the present study. Laparoscopy is costly and carries potential risks associated with surgery and general anesthesia [34]. There are reports of more experienced sonographers identifying peri-tubal pathologies during SSH making it even more a useful test compared to HSG [31, 35, 36].

#### **Procedure related complication**

Insertion of Foley catheter in to the uterine cavity was successful in all our subjects. By using tenaculum to straighten the cervical canal, the relative difficulty experienced in inserting the Foley catheter in six patients was easily overcome.

Only two patients experienced significant pain during the procedure requiring medication. This closely parallels previously reported incidences of pain during the procedure [11, 26]. Mild pelvic discomfort was reported by many patients during the insertion of the catheter or injection of agitated saline, but this did not result in discontinuation of the procedure. Patient compliance to sonosalpingography has been reported to be better than to HSG [37, 38].

There is always the potential to introduce infection into the upper genital tract when instruments are passed through the cervix [39]. The risk of infection is difficult to quantify. The UK multicentre study [40] in 1995 did not identify any case of infection in 98 recruits who were not given prophylactic antibiotics. It seems probable that the risk is less than 1%. Nevertheless, risk of iatrogenic pelvic inflammatory disease in women with subfertility can be life long. The Royal College of Obstetricians and Gynaecologists now recommends the use of prophylactic antibiotics for all such procedures [41] and SSH is no exception. Some investigators have used prophylactic antibiotics immediately after SSH [42] and others have not used any antibiotic prophylaxis, but did not have infectious complications [26]. In our study, all study subjects received prophylactic antibiotics prior to procedure and no infectious complications were recorded during the study period.

Other complications reported during SSH are vasovagal attacks, nausea and pain [11].

#### **Limitation**

SSH will not demonstrate pelvic adhesions which do not result in tubal occlusion, or endometriosis which does not result in cyst formation. It must also be accepted that a few cases of tubal disease will be missed even though the false-negative rate is low.

Reasonably good ultrasound scan machine with a transvaginal probe is a necessity for performing SSH confidently and reliably. Many peripheral units in a developing country like Sri Lanka lack this facility. Nevertheless, many centres treating patients with subfertility are currently equipped with a good scan machine making adaptation of this method feasible.

Another major drawback of SSH is the time period needed for training to be able to confidently assess the tubal patency. The expertise required to interpret the images seen at SSH is greater than that for either laparoscopy or hysterosalpingography, where the end-points are obvious. For a person with experience in TVS the learning curve is shallow and will be able to perform the test confidently in a short after about 5 -10 cases.

In this study, the limited number of patients studied may have failed to recognize some of the rare complications of the procedure and other limitations.

#### **Conclusion**

Our results confirm that vaginal sonographic hydrotubation using agitated saline is a low cost, reliable, safe and a comfortable method to assess tubal patency and uterine cavity without special instrumentation on an outpatient basis. The procedure is relatively painless and does not need any medication except prophylactic antibiotics.

In units where vaginal sonographic skills are available, this method can be used to screen for tubal patency after a short period of training. This will greatly reduce the number of patients being exposed to X ray and number of patients undergoing laparoscopy with general anaesthesia unnecessarily.

The use of laparoscopy with appropriate therapeutic measures taken during the same operation can be reserved for patients with a history of endometriosis or previous severe pelvic inflammatory disease.

#### **Acknowledgment**

We acknowledge Professor Malik Goonawardene (MBBS, MS. FRCOG, FSLCOG); Nursing officers in wards for the support given to conduct this study and all women who willingly participated in the study.

#### **References**

1. Evers JLH; Female subfertility. *Lancet*, 2002; 360: 151-9.



2. Bhattacharya S; Infertility. In: Edmonds K, editor. Dewhurst's textbook of Obstetrics & Gynaecology. 7 edition, UK: Blackwell Publishing, 2007: 440 – 60.
3. Samarakoon S; Infertility in the district of Colombo: University of Colombo. 1994.
4. NICE guideline; Fertility: assessment and treatment for people with fertility problems London: National Institute for Clinical Excellence. 2004.
5. Corson SL; The role of laparoscopy in the infertility workup. *J. Reprod. Med.*, 1977; 18(3):127 - 31.
6. Chapron C, Querleu D, Bruhat MA, Madelenat P, Fernandez H and Pierre F; Surgical complications of diagnostic and operative gynaecological laparoscopy: a series of 29,966 cases. *Hum. Reprod.*, 1998; 13: 867 - 72.
7. Swart P MB, van Beurden M, van der Veen F, Redekop WK and Bossuyt PM; The accuracy of hysterosalpingography in the diagnosis of tubal pathology : a meta-analysis. *Fertil. Steril.*, 1995; 64: 486 - 91.
8. Ayida G KS, Barlow D and Chamberlain P; A comparison of patient tolerance of hysterosalpingo-contrast sonography (HyCoSy) with Echovist-200 and X-ray hysterosalpingography for outpatient investigation of infertile women. *Ultrasound Obstet. Gynecol.*, 1996; 7(3): 201 - 4.
9. Tina SRG; Fallopian Tubal Patency Assessed by Ultrasound Following Fluid Injection. *Radiology*, 1984; 152: 507 - 10.
10. Tufekci EC, Girit S, Bayirli E, Durmusoglu F and Yalti S; Evaluation of tubal patency by transvaginal sonosalpingography. *Fertil. Steril.*, 1992; 57(2): 336-40.
11. Holz K BR and Schurmann R; Ultrasound in the assessment of tubal patency: a meta-analysis of three comparative studies of Echovist 200 including 1007 women. *Zentralbi. Gyna-kol.*, 1997; 1(19): 366 - 73.
12. Tanawattanacharoen SSS, Uerpaiojkit B, Wisawasukmongchol W, Boonkasemsanti W and Virutamasen P; Transvaginal HyCoSy compared with chromolaparoscopy: a preliminary report. *J. Med. Assoc. Thailand*, 1998; 81: 520 - 6.
13. Kalogirou DAG, Botsis D, Kassanos D, Vitoratos N and Zioris C; Is colour doppler necessary in the evaluation of tubal patency by HyCoSy?. *Clin. Exp. Obstet. Gynecol.*, 1997; 24: 101 - 3.
14. <http://www.radiologyinfo.org>.
15. Muller HJ; Damage to posterity by irradiation of the gonads. *Am. J. Obstet. Gynecol.*, 1954; 67: 467 - 83.
16. <http://www.protecheyewear.com>
17. Phil Lieberman RLS and George Treadwell; Radiocontrast reactions. *Clinical Reviews in Allergy and Immunology*, 1986; 4(2): 229 - 45.
18. Chenia F HGJ, Moolla S and Oratis P; Sonographic hydrotubation using agiated saline:a new technique for improving fallopian tube visualization. *The British Journal of Radiology*, 1997; 70: 833 - 6.
19. Gramiak PMS R and Kramer DH; Ultrasound cardiography: contrast studies in anatomy and function. *Radiology*, 1969; 92: 939 - 48.
20. Stewart MJ; Contrast Echocardiography. *Heart*, 2003; 89(3): 342 - 8.
21. Patil M; Assessing tubal damage. *J. Hum. Reprod. Sci.*, 2009; 2:2 - 11.
22. AUMenken J, Trussell J, Larsen USO; Age and infertility. *Science*, 1986; 233(4771): 1389.
23. Volpi E, De Grandis T, Rustichelli S, Zuccaro G, Patriarca A and Sismondi P; A new technique to test tubal patency under transvaginal sonographic control. *Acta Obstet. Gynecol. Scand.*, 1994; 73(10): 797-801.
24. Heikkinen H, Tekay A, Volpi E, Martikainen H and Jouppila P; Transvaginal salpingosonography for the assessment of tubal patency in infertile women: methodological and clinical experiences. *Fertil. Steril.*, 1995; 64(2): 293-8.
25. Spalding H, Tekay A, Martikainen H and Jouppila P; Assessment of tubal patency with transvaginal salpingosonography after treatment for tubal pregnancy. *Hum. Reprod.*, 1997; 12(2): 306-9.
26. Inki PPP, Anttila L. Vaginal sonosalpingography in the evaluation of tubal patency. *Acta Obstet. Gynecol. Scand.*, 1998; 77(10): 978 - 82.
27. Ahinko-Hakamaa K, Huhtala H and Tinkanen H; The validity of air and saline hysterosalpingo-contrast sonography in tubal patency investigation before insemination treatment. *Eur. J. Obstet. Gynecol. Reprod. Biol.*, 2007; 132(1): 83-7.
28. Evers JL, Land JA and Mol BW; Evidence-based medicine for diagnostic questions. *Semin. Reprod. Med.*, 2003; 21(1): 9-15.
29. Halkin A, Reichman J, Schwaber M, Paltiel O and Brezis M; Likelihood ratios: getting diagnostic testing into perspective. *QJM*, 1998; 91(4): 247-58.
30. Goldberg TF and M Attaran; Sonohysterographic evaluation of uterine abnormalities noted on hysterosalpingography. *Human Reproduction*; 1997; 12(10): 2151 - 3.
31. Brown SECC, Schnorr J, Toner JP, Gibbons W and Oehninger S; Evaluation of outpatient hysteroscopy, saline infusion hysterosonography and hysterosalpingography in infertile women: a prospective, randomized study. *Fertil. Steril.*, 2000; 74(5): 1029 - 34.
32. Lachlan deCrespigny RK and Dorothy McGinnes; Saline Infusion Sonohysterosalpingography, an Underutilized Technique. *Australian and NewZealand journal of Obstetrics and Gynaecology*, 2008; 37(2): 206 - 9.
33. Hovav Y, Hornstein E, Almagor M and Yaffe C; Diagnostic laparoscopy in primary and secondary infertility. *J. Assist. Reprod. Genet.*, 1998; 15(9): 535-7.
34. Royal College of Obstetricians and Gynaecologists (RCOG); The investigation and management of endometriosis. London(UK): Royal College of Obstetricians and Gynaecologists (RCOG), 2006.
35. Cepni I, Ocal P, Erkan S, Saricali FS, Akbas H, Demirkiran F; Comparison of transvaginal sonography, saline infusion sonography and hysteroscopy in the evaluation of uterine cavity pathologies. *Australian and*



- NewZealand journal of Obstetrics and Gynaecology, 2005; 45(1): 30-5.
36. Dzotsenidze TN, Davarashvili DI, Nikolaishvili TG, Peradze DG, Datunashvili ED; Contrast sono hysterosalpingography in the study of endometrial abnormalities and tubal patency in infertile patients. Georgian Med. News., 2006; 139:61-3.
37. Hamed HO, Shahin AY and Elsamman AM; Hysterosalpingo-contrast sonography versus radiographic hysterosalpingography in the evaluation of tubal patency. Int. J. Gynaecol. Obstet., 2009; 105(3): 215-7.
38. Friberg B and Joergensen C; Tubal patency studied by ultrasonography. A pilot study. Acta Obstet. Gynecol. Scand., 1994; 73(1): 53-5.
39. Thomas K and Simms I; Chlamydia trachomatis in subfertile women undergoing uterine instrumentation. How we can help in the avoidance of iatrogenic pelvic inflammatory disease?, Hum. Reprod., 2002; 17: 1431 - 2.
40. Killick S R; Using HyCoSy as a screening test - UK multicentre study. Hum. Reprod., 1995; 10(1): 234 - 8.
41. Royal College of Obstetricians and Gynaecologists; The management of infertility in tertiary care. London, UK: RCOG press, 2000.
42. Exacoustos C, Zupi E, Carusotti C, Lanzi G, Marconi D and Arduini D; Hysterosalpingo-contrast sonography compared with hysterosalpingography and laparoscopic dye pertubation to evaluate tubal patency. J. Am. Assoc. Gynecol. Laparosc., 2003; 10(3): 367-72.