

## Research Article

# Highly Active Antiretroviral Therapy: Effects on Foetal Parameters, Kidney and Spleen of the Dams

<sup>1</sup>Ayeni O.J., <sup>\*1</sup>Ogunlade B., <sup>2</sup>Akunna G.G., <sup>3</sup>Enye L.A., <sup>4</sup>Alao A.A

<sup>1</sup>Department of Anatomy, College of Medicine of the University of Lagos, Idi Araba, Lagos, Nigeria.

<sup>2</sup>Department of Anatomy, Lagos State University College of Medicine (LASUCOM) Ikeja, Lagos, Nigeria.

<sup>3</sup>Department of Anatomy, College of Health Sciences, Afe Babalola University, Ado-Ekiti, Ekiti, Nigeria

<sup>4</sup>Department of Heamatology and Blood transfussion, Ladoke Akintola University Teaching Hospital , Ogbomosho, Oyo, Nigeria.

**Corresponding author**

**Ogunlade B**

Email: [samlad4dr@yahoo.com](mailto:samlad4dr@yahoo.com)

**Abstract:** This study was conducted to investigate the histomorphological effect of the highly active antiretroviral therapy combination of Zidovudine, Lamivudine and Nevirapine administration on kidney and spleen of pregnant wistar rats, fetal parameters and heamatological indices (white blood cell count and packed cell volume). Experiment was performed using animal models in Department of Anatomy, College of Medicine of the University of Lagos, Idi Araba, Lagos, Nigeria between February, 2012 to July, 2012. Cyclic female Sprague Dawley rats weighing 120 to 150g with at least three regular 4-day cycles were divided into four main groups after successful mating comprising of ten rats each. Group 1(G1) was used as control group and were treated with distilled water. Group 2 (G2) received 1.9mg/kg body weight of fixed dose combination of Zidovudine, Lamivudine and Nevirapine . Group 3 (G3) received 3.8mg/kg body weight of the fixed dose combination. Group 4 (G4) received 5.8mg/kg body weight of the fixed dose combination. The administration was done from 1-day of pregnancy to the 20<sup>th</sup> day of pregnancy. The maternal kidney, spleen and blood samples were taken for histo-morphologic and hematologic analysis in all groups. Foetal parameters such as the crown rump length, tail length and umbilical weight were also assessed. Results obtained revealed that the administration of the fixed dose combination of Zidovudine, Lamivudine and Nevirapine to pregnant rats produces no significant difference in the body weight and fetal outcomes when compared with the control group. There was a significant increase in the white blood cell and a decrease in packed cell volume within the experimental groups from group 2 to group 4 when compared with the control group. Also, there was no significant difference in the histoarchitecture of the spleen and kidney between G1 and G2 whereas the G3 and G4 presents mild to moderate derangement of the histoarchitecture of the organs respectively. From the study it can be concluded that fixed dose combination of Zidovudine, Lamivudine and Nevirapine do not have obvious/gross deleterious effects during pregnancy only at minimal dose.

**Keywords:** HAART drug, Foetal parameters, Heamatological indices, Kidney, Spleen

## INTRODUCTION

A virus reported by Montagnier was said to be present in opportunistic infections that was caused by pneumocystis carinii associated to malignant neoplasias as the Kaposi's sarcoma [1-3]. It was later refer to as the Human Immunodeficiency Virus (HIV) responsible for the Acquired Immunodeficiency Syndrome (AIDS) [4].

This life threatening infection soon spread out and was referred to as the world most pandemics disease [5]. Human immunodeficiency syndrome (HIV) is the greatest crisis the world faces today (WHO, 2000). HIV is most prevalent among persons of reproductive age about one third of whom desire to have children [6]. Researchers have found that Nigeria with a zero prevalence of 4.6% has an estimated number of 2.95 million of people living with HIV/AIDS (7). One of the routes by which the infection can spread is via mother – to –child transmission (MTCT). HIV-1 transmissions from mother to child could occur in utero, intrapartum

or postnatally through breastfeeding [8-9]. Evidences for both early and late utero transmission have been documented [10-11].

HIV/AIDS survival has been enhanced by medical therapy called antiretroviral drugs. The use of antiretroviral therapy (ART) and highly active antiretroviral therapy (HAART) changed HIV management from that of uniformly fatal disease to that of chronic disease [11].

Antiretroviral drugs reduce viral replication and can reduce mother-to-child transmission of HIV either by lowering plasma viral load in pregnant women or through post exposure prophylaxis in their newborns [12]. Women receive ART drugs during pregnancy as part of potent combination regimens to treat HIV infection and/or prophylaxis to prevent HIV infection in infants. Researchers found that ART regimens for childbearing age category of women should be selected carefully considering possibility of a planned or

unintended pregnancy since ART drugs may be taken in the first trimester of pregnancy before it is recognized.

In 2000, World Health Organization recommended regimens to prevent MTCT which included Nucleoside analogue reverse transcriptase inhibitors (NRTIs) such as Zidovudine and Lamivudine and the Non-nucleoside reverse transcriptase inhibitor (NNRTI) Nevirapine.

Later it was found that combination of antiretroviral therapy (ART) is the cornerstone of management of patients with HIV infection. Although ART can reduce viral load to undetectable level, improve immunity and prolong survival of patients, ART drugs are associated with many adverse effects that may be severe and affect patient adherence and quality of life [13]. Although triple combination regimens are widely used in industrialized countries for preventing MTCT in women, their safety and effectiveness have not been assessed in resource constrained settings. With the increasing use of combination therapies, drug-drug interactions causing significant health risks are becoming more common [14].

Information is still lacking on the effects of short courses of ART drugs to prevent MTCT on the long term health of infected mother and that of her infant as there are physiological changes that occur during pregnancy which affects absorption, distribution, metabolism and elimination of drugs. While access to services in preventing mother – to-child transmission of HIV has increased, the total number of children being born with HIV has also decreased but HAART in pregnancy has been associated with higher rate of prematurity, pre- eclampsia and gestational diabetes [15].

There are physiological changes associated with pregnancy which increases intracellular nucleotide exposure [16]. Hence, potential risk for adverse outcomes associated with the use of antiretroviral therapy during pregnancy should be considered. Therefore, this study was aimed at investigating the effect of HAART regimen (Zidovudine, Lamivudine and Nevirapine) on foetal parameters and the histomorphology and selected hematological indices in pregnancy using animal model.

## RESEARCH DESIGN AND METHODOLOGY

### Drugs and Source

The three combinations of antiretroviral drugs required for the study were obtained from the AIDS prevention initiative in Nigeria (APIN), Lagos University Teaching Hospital, Idi Araba, Lagos, Nigeria. The drugs were produced by AUROBINDO pharma limited, Unit 111, Survey No 313, Bachhupally Village, Quthubullapur Mandal, Range Reddy District (A.P) India with National Agency for Food Drug

Administration and Control (NAFDAC) reg. No. 04-9498 for Lamivudine, Zidovudine and Nevirapine® combinations respectively.

### Animals

Sixty (60) female and thirty (30) male adult wistar rats were obtained from a breeding stock maintained in the animal house of the college of health sciences, Ladoke Akintola University of Technology (LAUTECH), Ogbomosho. The animals were housed in well ventilated wire wooden cages in the animal facility of the department of Anatomy, College of Medicine of the University of Lagos, Idi Araba, Lagos State, Nigeria. The rats were maintained under standard natural photoperiodic condition of twelve hours of light alternating with twelve hours of darkness (i.e.L:D;12h:12h photoperiod) at room temperature (25-26c) and humidity of 65±5. They were allowed unrestricted access to water and rat chow, they were acclimatized for 7 days before the commencement of the experiment. The weights of the animals were estimated using an electronic analytical and precision balance (BA210S, d=0.0001g) (Satorius GA, Goettingen, Germany). The rats weighing 230– 260 g, were mated in the proportion of 2 females for 1 male during 2 h. Pregnancy was verified according to Hamilton & Wolfe (1938); the finding of spermatozoa in vagina was taken as an indication of pregnancy (day 0).

Experimental procedures involving the animals and their care were conducted in conformity with international national and institutional guidelines for the care of laboratory animals in biomedical research and use of laboratory animals in bio-medical research promulgated by the Canadian council of animal care [17].

### Experimental Procedure

Forty pregnant rats were then randomly divided into 4 groups and treated from the 1<sup>st</sup> up to the 20th day of gestation as follows: Group G1 (control), treated with drug vehicle (distilled water); Group G2 (exp.1) were treated with 1ml of 1.9mg/kg b.w. of nevirapine, zidovudine and lamivudine; Group G3 (exp.2) were treated with 3.8mg/kg b.w. of nevirapine, zidovudine and lamivudine; Group G4 (exp.3) were treated with 5.7mg/kg b.w. of nevirapine, zidovudine and lamivudine. Drugs and vehicle were given once a day at 08:00 h by gavage. Body weight gain was monitored by weighing the animals at days 0, 7th, 14th and 20th of pregnancy using an electronic analytical and precision balance (BA210S, d=0.0001g) (Satorius GA, Goettingen, Germany).

### Animal Sacrifice and Sample Extraction

Animals were sacrificed twelve hours after the last treatment, the rats were at the time of sacrifice first weighed and then cervical dislocation was carried out. Blood samples were collected into heparinized

bottles and later centrifuged (Uniscop SM112) at 3000 g for 30 min. Hematological analyses Packed Cell Volume (PCV) and total White Blood Cell Count (WBC) were carried out according to the methods described by Dacie and Lewis (1991). The abdominal cavity of each rat was opened up through a midline abdominal incision. The living fetuses and their placentas were carefully removed, loosely passed onto filter paper to remove excess liquid and weighed to the nearest of 0.1 mg. The kidney and spleen was excised and weighed with an electronic analytical and precision balance. The kidney and spleen of each animal was fixed in 10% formol-saline for histological examination. (BA 210S, d=0.0001- Sartoriusen GA, Goettingen, Germany).

#### Histological Procedures and Analysis

This was done as described by Ogunlade *et al* [18]. Briefly, the organs were cut on slabs about 0.5cm thick and fixed in 10% formol saline for a day after which they were transferred to 70% alcohol for dehydration. The tissues were passed through 90% alcohol and chloroform for different durations before they were transferred into two changes of molten

paraffin wax for 20min each in an oven at 57<sup>0</sup> C. Serial sections of 5µm thick were obtained from a solid block of tissue and were stained with haematoxylin and eosin stains, after which they were passed through a mixture of equal concentration of xylene and alcohol. Following clearance in xylene, the tissues were oven- dried. Photomicrographs were taken with a JVC colour video digital camera (JVC, China) mounted on an Olympus light microscope (Olympus UK Ltd, Essex,UK) to demonstrate the cytoarchitecture of the kidney and spleen.

#### Statistical Analysis

All data are expressed as Mean±SEM (standard error of mean). Significant differences were tested using ANOVA. Values of p<0.05 were considered statistically significant [19-20].

### RESULTS

#### Body weight

The mean body weight gain of the pregnant rats treated with antiretroviral combinations drug has no significant differences compared with the control group that received distilled water for 20 days (table 1).

**Table 1: Body weight gain of pregnant rats treated with antiretroviral drugs during the entire gestation.**

Group	0	7 <sup>th</sup>	14 <sup>th</sup>	20 <sup>th</sup>
Group 1	172.5±2.5	180.8±2.5	192.5±1.2	204.5±1.2
Group 2	175.0±2.3	183.5±1.5	195.8±2.8	215.5±1.4
Group 3	180.5±1.0	192.5±2.3	207.6±2.3	228.5±1.6
Group 4	183.0±1.5	203.1±2.5	218.5±1.5	232.7±1.5

Data are given in grams (mean ± SD).

No significant differences were noticed among the groups within each pregnancy period.

#### Foetal outcomes

The foetal parameters shows no statistically significant difference in the crown-rump length, tail

length, foetal body weight, placental weight and number of foetuses as compared to that of the control group, (table 2).

**Table 2: Foetal outcomes of rats treated with combined HAART drug during the entire gestation.**

Parameters	Group 1	Group 2	Group 3	Group 4
Foetal weight	2.30±0.3	2.20±0.2	1.80±0.3	1.90±0.2
Number of foetuses	9.00±0.1	9.00±0.1	9.00±0.2	10.00±0.1
Placental weight	0.57±0.1	0.50±0.1	0.54±0.2	0.50±0.15
Crown- rump length	4.20±0.3	4.10±0.2	4.30±0.1	4.20±0.2
Tail length	1.10±0.1	1.20±0.3	1.20±0.2	1.30±0.1
Number of placenta	9.00±0.1	9.00±0.1	9.00±0.2	10.00±0.1
Umbilical length	2.40±0.3	2.20±0.5	2.40±0.2	2.30±0.3

Data are given in grams (mean ± SD).

No significant differences were noticed among the groups within each pregnancy period.

#### Hematological parameters

Administration of the combination of the drug caused a significant percentage increase in white blood cell count when compared to the control group. However, the

antiretroviral combination administered caused overall significant (p<0.05) decrease in the packed cell volume compared to the control group, (table 3).

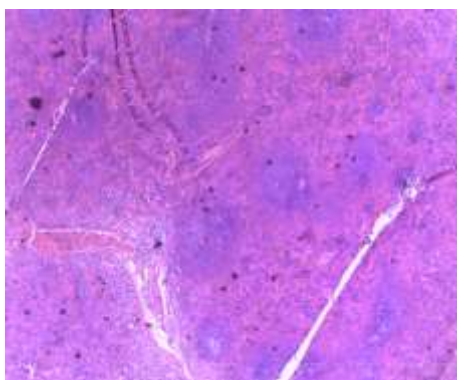
**Table 3: Hematological indices in pregnant rats treated with antiretroviral drugs as compared with the control group**

Groups	WBC count (%)	PCV count (%)
Group 1	13.0±1.0	86.0±2.5
Group 2	43.0±1.0**	50.0±1.3*
Group 3	46.8±2.0**	62.7±1.5**
Group 4	52.5±1.0**	67.1±2.0**

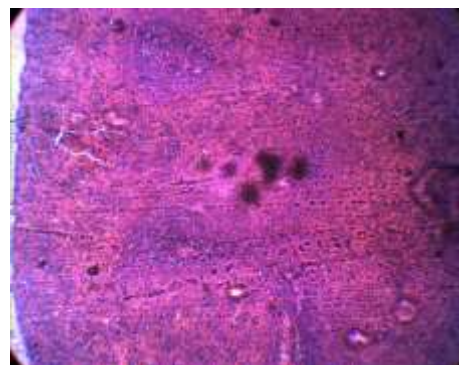
Values are Mean±SD for 6 rats in each group. \* Indicates significant difference (p<0.05) when compared to the control group. WBC: White Blood Cell count, PCV: Packed Cell Volume

**Histopathology Of The Spleen**

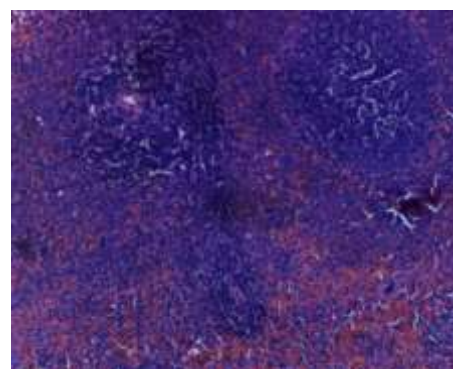
In these results, there were significant changes between the experimental groups and the control group. It was observation that quantity and duration of HAART consumption produce a marked alteration in the micro architecture of spleen morphology. In the representative section of the control group, all observations were in accordance with the normal splenic architecture consisting of areas of white pulp with germinal center and surrounding lighter marginal zone, and red pulp (Figure 1). In group B that was given 1.9MG/KG of HAART, the microscopic features show little or no difference as compared with that of control group. The white pulp was intact with visible germinal center and the red pulp at a minimal dose (Figure 2). In group C that receives 3.8MG/KG of HAART, the micro architecture shows visible white pulp not greatly separated due to mild expanded red pulp (Figure 3). In group D that receives 5.7MG/KG of HAART, the microscopic appearance shows the area of white pulp been much separated by marked expansion of the red pulp, there is extensive vascular and cellular congestion, cell fragmentation and increased vascularity (Figure 4).



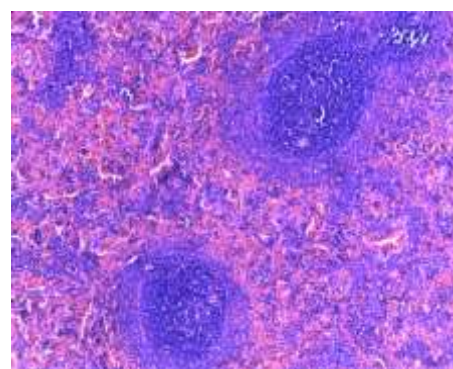
**Fig.1: Control group X 100MG showing intact splenic tissue.**



**Fig.2: Group B X 100MG showing intact red and white pulps.**



**Fig.3: Group C X 100MG showing white pulp with increase vascularity in red pulp.**

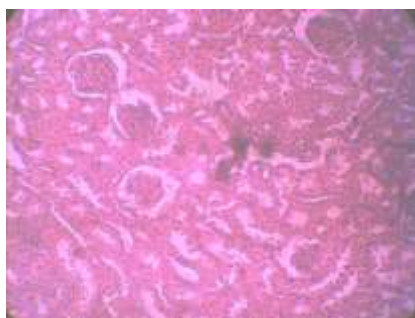


**Fig.4: Group D X 100MG showing white pulp surrounded by extensive red pulp.**

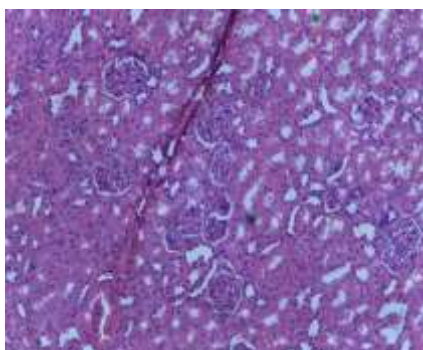


### Histopathology of the Kidney

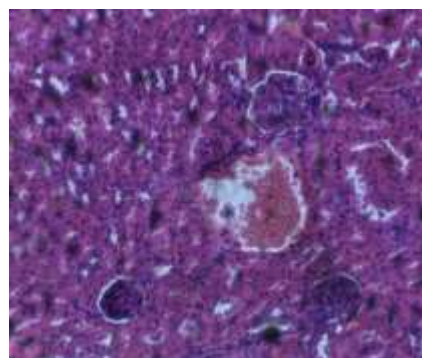
In these results, it was observed that the administration of HAART combination drug produce a notable distortions to the histoarchitecture of the kidney within the experimental groups (especially in the higher dose) compared to the control group. In the control group, normal renal architecture was observed showing intact cortex and medulla, visible bowman's capsule lined with outer parietal layer (squamous capsular cells) and inner visceral layer (podocyte cells), urinary space, proximal convoluted tubules and distal convoluted tubules was also observed (Figure 5). In group B that receive 1.9MG/KG of HAART, the microscopic features show little or no difference as compared with that of control group since there were visible cortex and medulla with prominent bowman's capsule lined with squamous capsular cells.(Figure 6). In group C that receives 3.8MG/KG of HAART, the micro architecture shows cortex and medulla with mild nodular necrosis visible (Figure 7).In group D that receives 5.7MG/KG of HAART, the microscopic appearance shows derangement in the cortex and medulla with moderate nodular necrosis surrounding the Bowman's capsule (Figure 8).



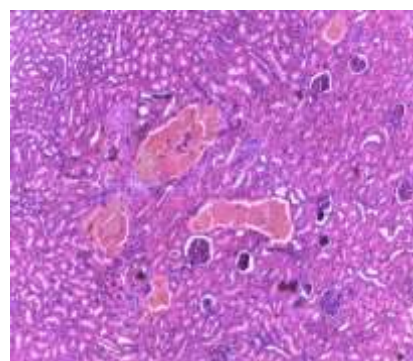
**Fig. 5: Micrographs of group A, showing intact bowman's capsule, proximal and distal convoluted tubules.**



**Fig. 6: Micrographs of group B, showing intact bowman's capsule, proximal and distal convoluted tubules.**



**Fig. 7: Micrographs of group C, showing nodular necrosis within the Bowman's capsule.**



**Fig. 8: Micrographs of group D, showing prominent nodular necrosis within the deranged Bowman's capsule.**

### DISCUSSION

This research was carried out to ascertain the safety of HAART drugs (fixed dose combination of Zidovudine, Lamivudine and Nevirapine) use during pregnancy on the mother and unborn child in a resource limited settings. W.H.O recommended the use of fixed dose combination of Zidovudine, Lamivudine and Nevirapine to prevent mother to child transmission in a resource limited settings [21]. Studies on highly active antiretroviral drug combination of Zidovudine, Lamivudine and Nelfinavir on fertility parameters shows no significant statistical difference regarding preimplantation loss and implantation efficiency value, fetal viability values and number of fetuses when compared with the control [22].

Infants born to mothers taking HAART have been reported to have smaller birth weight compared to HIV-negative mothers. In addition, Wei *et al.* [23] also reported decreasing values of fetal parameters compared to the control group when HAART combination of Zidovudine, Lamivudine and Nelfinavir was administered during pregnancy. But in our study, there was no decrease in fetal parameters during the entire gestation period of the animal. Though, the United States Food and Drug Agency, (2010) reported increased embryotoxicity and fetal malformation and

embryo lethality in various studies in which near to lethal dose of Zidovudine and Lamivudine was used. This present study indicates no significant statistical difference in the fetal parameters such as crown-rump length, tail length, fetal weight, placental weight and umbilical length when the fixed dose combination of Zidovudine, Lamivudine and Nevirapine was administered throughout the course of pregnancy. No significant statistical difference in weight of female rats was observed in this study although other studies that used near to lethal dose reported differently. Ernesto Antonio *et al.*, 2002; while He Y *et al.*, 2011 reported that the use of HAART can prevent mother to child transmission of HIV but does not influence the growth and development of the baby in humans. Zidovudine, in isolation has been associated with hematologic toxicity including neutropenia and severe anemia especially in patients with advanced HIV diseases [23].

In this study, significant statistical difference was observed as there was a significant increase in the white blood cell count and a decrease in packed cell volume. In pregnancy, increase in cardiac output, plasma volume, red cell mass and glomerular filtration rate occurs [24-25]. Poirier *et al.*, [26] explained that acute kidney injury can occur as a result of severe mitochondrial dysfunction and lactic acidosis induced by nucleoside reverse transcriptase inhibitors (NRTIs) class in which Zidovudine and Lamivudine is member. In addition, it was reported that non specific metabolic complications may increase the risk of vascular kidney diseases in patients on HAART [27]. Poirier *et al.*, [26] also reported that after the initiation of Nevirapine containing regimen, acute renal failure is usually observed. In this study, no significant difference was observed except for the experimental group that received the highest dose of the combination therapy where derangement of the cortex and medulla occur and moderate nodular necrosis was observed. Among the side effects explained by the United States Food and Drug Agency (2010) on chronic usage of Zidovudine, Lamivudine containing regimen is splenomegaly.

In our findings, it was the experimental animals that received the highest dose that presented with vascular and cellular congestion. Other experimental groups present mild to moderate changes in the splenic histo-architecture.

## CONCLUSION

Within the limits of experimental error, this research work have demonstrated that the use of fixed dose combination of Zidovudine, Lamivudine and Nevirapine during pregnancy does not have an adverse effect on the maternal histo- architecture of the kidney and spleen at minimal dose. It is also clear in our investigation that fixed dose combination of Zidovudine, Lamivudine and Nevirapine increases the white blood cell count and a decrease in the packed cell volume. Fetal parameters such as placental weight,

umbilical length, tail length, fetal weight and crown rump length of Sprague Dawley rat fetuses are not adversely affected by in utero exposure to the fixed dose combination of Zidovudine, Lamivudine and Nevirapine. It was therefore concluded that fixed dose combination of Zidovudine, Lamivudine and Nevirapine do not have obvious/gross deleterious effects during pregnancy only at minimal dose.

## REFERENCES

1. Gottlieb MS, Schoroff R, Schanker M and Weisman JD; Pneumocystis carinii pneumonia and mucosal candidiasis in previously healthy homosexual men. N. Engl. J. Med., 1981; 305: 1425-31.
2. Masur H, Michelis MA, Greene JB and Onorato I; An outbreak of community-acquired *Pneumocystis carinii pneumonia*. N. Engl. J. Med., 1981; 305:1431-8,.
3. Siegal FP, Lopez C and Hammer GS; Severe acquired immunodeficiency in male homosexuals, manifested by chronic perinatal ulcerative herpes simplex lesions. N. Engl. J. Med., 1981; 305:1439-44.
4. <http://www.unaids.org/worldaidsday/2002/presentation/epiupdate-2002-en.doc>
5. Pontes RDV, Amed AM; Simões MJ, Oliveira-Filho RM, Simões RS and Kulay Jr. L; Effect of lamivudine on the rat pregnancy outcome. Int. J. Morphol., 2005; 23(3):205-208.
6. Bashi J, Balestre E, Messou E, Maiga M, Coffie PA, Zannou DM *et al.*; Time trends in demographic and clinical characteristics of adult patients on HAART initiation in West Africa. Med. Mal. Infect., 2009.
7. Federal ministry of health, Department of Public Health National HIV/STDs Control Program, 2009.
8. Wolinsky SM, Wike CM, Korber BTM, Hutto C, Parks WP, Rosenblum LL, Kunstman KJ, Furtado MR and Munoz JL; Selective transmission of human immunodeficiency virus type-1 variants from mothers to infants. Science, 1992; 255:1134-1137.
9. Pasquier C, Cayrou C, Blancher A, Tourne-Petheil C, Berrebi A, Tricoire J, Puel J and Izopet J; Molecular evidence for mother-to-child transmission of multiple variants by analysis of RNA and DNA sequences of human immunodeficiency virus type 1. Journal of Virology, 1998; 72: 8,493-8,501.
10. Peckham C and Gibb D; Mother-to-child transmission of the human immunodeficiency virus. N. Engl. J. Med., 1995; 333: 298-302.
11. Kuhn L and Stein ZA; Mother-to-infant HIV transmission: timing risk factors and prevention. Paediatric Perinatal Epidemiology, 1995; 9:1-29.
12. Lucas GM, Chaisson RE and Moore RD; Highly active antiretroviral therapy in a large

- urban clinic: Risk factors for virologic failure and adverse drug reactions. *Ann. Int. Med.*, 1999; 131: 81-87.
13. Montessori V, Press N, Harris M, Akagi L and Montaner JS; Adverse effects of antiretroviral therapy for HIV infection. *Can. Med. Assoc. J.*, 2004; 170: 229-238.
  14. Lewis W, Haase CP, Raidel SM, Russ RB, Sutliff RL, Hoit BD and Samarel AM; Combined antiretroviral therapy causes cardiomyopathy and elevates plasma lactate in transgenic AIDS mice, *Lab Invest*, 2001; 81:1527-36.
  15. Palella FJJ, Delaney KM, Moorman AC, Loveless MO, J. Fuhrer *et al.*; For the HIV outpatient study investigators. Declining morbidity and mortality among patients with advanced human immunodeficiency virus infection. *N. Eng. J. Med.*, 1998; 338: 853-860.
  16. Kise J, Anderson P, Weinberg A, Fletcher C, Flaherty J and K Scarsi; Lamivudine Triphosphate and Zidovudine Triphosphate Concentrations in HIV-Infected Women throughout pregnancy and post-partum. *CROI Paper J.*, 2012; 1014.
  17. Canadian Council of Animal Care 1985. Guide to the handling and use of experimental animals. Ottawa: Ont.; 2 United States NIH publications. 85- 23:45-47.
  18. Dacie JV and Lewis SM; *Practical Hematology*. 7th Edn., Edinburgh, Churchill Livingstone, England, 1991: 37-85.
  19. Ogunlade B, Saalu LC, Ogunmodede OS, Akunna GG, Adeeyo OA, Ajayi GG; The salutary role of *Allium cepa* extract on the liver histology, liver oxidative status and liver marker enzymes of rabbits submitted to alcohol- induced toxicity. *American journal of Biochemistry and Molecular Biology*, 2012; 2 (2): 67-81, 2012.
  20. Bangboye EA, *A Companion of Medical Statistics*. Fobam Publishers, Ibadan, 2002.
  21. Zar JH; *Biostatistical Analysis*. Prentice-Hall, USA, 1984: 620.
  22. WHO Library Cataloguing-in-Publication Data Preferred antiretroviral medicines for treating and preventing HIV infection in younger children: Report of the WHO Paediatric Antiretroviral Working Group. World Health Organization; 2005.
  23. Wei X, Ghosh SK, Taylor ME, Johnson VA, Emini EA *et al.*; Viral dynamic in human immunodeficiency virus type 1 infection. *Nature*, 1995; 373: 117-122.
  24. Umar RA, Hassan SW, Ladan MJ, Matazu IK, Shehu B *et al.*; Adverse hepatic effects associated with administration of antiretroviral drugs (nevirapine, lamivudine and stavudine) to albino rats: Implication for management of patients with HIV/AIDS. *Asian J. Biochem.*, 2008; 3: 19-25.
  25. Sulkowski MS, Drug-induced liver injury associated with antiretroviral therapy that includes HIV-1 protease inhibitors. *Clin. Infect Dis.*, 2004; 38: S90-S97.
  26. Poirier MC, Olivero OA, Walker DM and Walker VE; Perinatal genotoxicity and carcinogenicity of anti-retroviral nucleoside analog drugs. *Toxicol. Appl. Pharmacol.*, 2004; 199:151-61.
  27. Tuomala RE, Shapiro DE and Mofenson LM; Antiretroviral therapy during pregnancy and the risk of an adverse outcome. *N. Engl. J. Med.*, 2002; 346:1863-70.