

Research Article

Histogenesis of Human Cerebellar Cortex

Dr. Angela A. Viswasom¹, Dr. Abraham Jobby²,

¹Associate Professor of Anatomy, Travancore Medical College, Kollam -691589.

²Department of Forensic Medicine, Travancore Medical College, Kollam-691589

Corresponding author

Dr. Angela A. Viswasom

E-mail: dangelakrishnan@yahoo.com

Abstract: The present study was conducted on specimens of cerebellum obtained from fetal autopsy. The study was done to identify the presence of the External Granular layer which acts as the precursor of the molecular, Purkinje and internal granular layers of the cerebellum. A comparison was done with a cerebellar specimen obtained from a two year old child to suggest that the external granular layer disappears after birth and its persistence leads to the formation of medulloblastoma.

Keywords: External granular layer, Foetus, Medulloblastoma

INTRODUCTION

Approximately at the end of the first embryonic month the cerebellum consists of a lamella rich in cells, which, towards the ventricle is covered with ependyma and towards the meninges passes over into a narrow marginal layer poor in cells.

At the end of the first embryonic month the following layers can be distinguished in the cerebellar lamella

1. The matrix, rich in cells developing out of the ventricular germ zone.
2. Intermediary layer on the outside of the matrix less rich in nuclei of cells.
3. A cortical layer with poor cellularity in cells.
4. A non-nucleated narrow marginal covering, which towards the pial sheath is bordered by glia membrana limitans.

Towards the end of the second embryonic month the intermediate layer becomes sparse in cell number, while, the cell number in the cortical area increases with the total cellular matrix originating from the ventricular matrix. The non-nucleated marginal layer also develops further.

About the middle of the third embryonic month there begins to appear on the surface of the cerebellum a dense layer of cells called external granular layer. This external granular layer arises from an area of closely packed cells called germinal bud.

Hess was probably the first to describe the external granular layer of the cerebellum. He thought that the cells of the external granular layer are destroyed and the material thus freed forms the "molecular substance".

Obersteiner [1] described the external granular layer more accurately and it was thus called

Obersteiner's layer. He distinguished two layers. He observed that the cells in the outer layer form the basal membrane and change into glia or become atrophied, while cells of the inner layer enter into the molecular layer and migrate through this into the inner granular layer.

According to Schaper [2] the external granular layer occurs in animals such as teleosts, birds and mammals, which possess a well developed cerebellum, but is lacking in those beings in which the cerebellum is a simple or folded lamella. According to him, the first germ layer is reduced to a simple ependymal layer after its nuclear material produces essentially only glia and cerebellar nuclei. Schaper observed a secondary germ layer close to the surface, which builds up the molecular layer, Purkinje cell layer and elements of inner granular layer.

Schaper [2] said that the external granular layer is composed of "indifferent cells" capable of differentiating into nerve cells and glial cells.

Popoff [3] stated that cells of the external granular layer are precursors of Purkinje cells and not all cells of the internal granular layer originate from it.

Berliner [4] substantiated the observations of Schaper. He stated that the external granular layer attained maximum development by the 3rd fetal month and decreases till the 5th month during which the surface of the cerebellum develops.

According to Jakob [5] the external granular layer, at the time of appearance consists of small, round or polygonal cells with an abundance of chromatin and narrow protoplasmic margin. The inner nuclei, the medulla and portion of cortex develop from ventricular germ zone. The external granular layer develops into

the molecular layer with ganglionic cells and inner granular layer.

Kershmann [6] demonstrated that there is a constant migration of cells from the external granular layer, but the character of cells emerging from the layer at different ages varies. At the time of birth the migrating cells are almost exclusively round or oval.

Raaf *et al.* [7] observed that the external granular layer does not decrease rapidly in width until shortly after birth. From then onwards until the tenth postnatal month the decrease is rapid. From the tenth to the twentieth postnatal months the decrease is slow until it completely disappears.

Yamaguchi *et al.* [8] studied the histological development of the human cerebellum and observed three stages in the development of internal granular layer of the foetus.

1. The primary or undifferentiated stage (before 18 weeks of gestation): In this stage the internal granular layer was hardly distinguishable from layer of immature Purkinje cell.
2. The secondary or intermediate stage (from 18 weeks of gestation to 35 weeks of gestation): In this stage the internal granular layer was clearly visible and almost stable in thickness in all parts.
3. The tertiary or developing stage (35 to 40 weeks of gestation): In this stage the internal granular layer showed dramatic increase in thickness as the formation of cerebellar folia proceeds.

MATERIALS AND METHODS

Human cerebellum obtained from post mortem specimens were the material used for the present study. The light microscopic structure of human cerebellum, with special reference to the number and arrangement of layers, was studied in detail. Specimens from ten foetuses were studied. The fetal specimen included discarded still born babies from hospitals. This was compared to cerebellar specimens obtained from two year old and above.

Methodology

Human cerebellum was obtained from the autopsies. Entire cerebellar hemispheres were dissected out of the posterior cranial fossae.

Dissected out specimens were subjected to routine histological processing [9]. The paraffin blocks thus obtained were serially sectioned at a thickness of 10µm

for staining with Haematoxylin and Eosin and 20-25µm thickness for special stains like Cresyl Fast Violet staining to demonstrate Nissl granules.

SMounted sections were observed under low power, high power and Oil Immersion objectives of binocular microscope with built in illumination for presence of external granular layer and its disappearance.

RESULTS

A 5-month-old foetus showed a well-developed external granular layer covering the outer surface. The external granular layer consists of spherical cells with a darkly staining nucleus almost completely fitting the cell. No obvious folial pattern was detected (Fig. 1). The rest of the cells appeared to be arranged without a definite sequence in a single sheet. These cells were also spherical but their nucleus did not stain as darkly as observed in the external granular layer. At certain sites these rounded cells were seen to be arranged in the form of anastomosing cords. None of the layers were distinguishable. Lacunae filled with clumps of red blood cells resembling primordia of blood vessels were observed in large numbers throughout the section.

The sections from the full term foetuses were better differentiated. The external granular layer was seen as clear as that in the five month old foetus. Folia could be observed in this specimen though it was not as prominent as that in adult (Fig.2). The cytoarchitecture resembled that of an adult cerebellum with ill-defined versions of the molecular layer, Purkinje cell layer and internal granular layer. The Purkinje cell layer was observed as a layer at the interface of the internal granular and molecular layer. The cells appeared elongated when compared to the rest of the cells and were darkly staining (Fig.3). At certain sites these cells demonstrated dendrites and its branching pattern. The characteristic flask shaped contour of the Purkinje cell was not observed. The molecular layer had few cells when compared to the internal granular layer. The molecular layer was definitely more cellular than its adult counterpart. The internal granular layer consists of rounded cells, which were arranged, in pattern of increasing density towards the periphery. A white matter core was not distinguishable and the whole area appeared cellular. Staining with Luxol Fast Blue did not yield positive results. Lacunae filled with clumps of red blood cells were seen clearly.

Specimen collected from a two and a half year old child showed complete disappearance of external granular layer. The definite folial pattern was obvious. The three layers of the cerebellar cortex and the inner core of white matter were seen clearly (Fig.4).

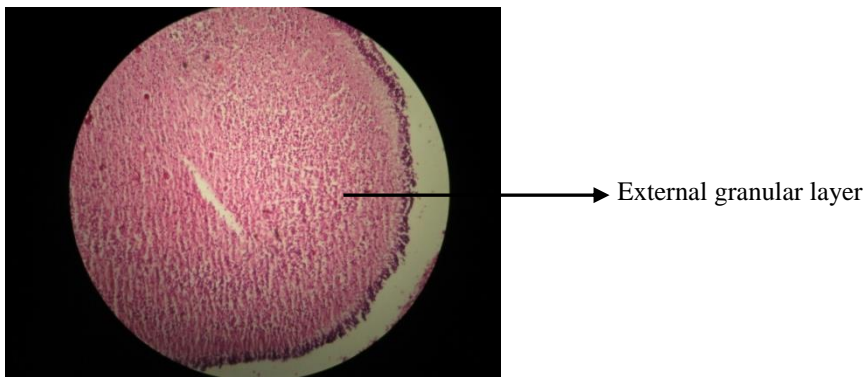


Fig. 1: 5-month-old foetus (M), Fix-Bouins fluid, H and E stain X100, Section shows external granular layer. Note the absence of folial pattern and arrangement of cells as a single sheet without a definite pattern.

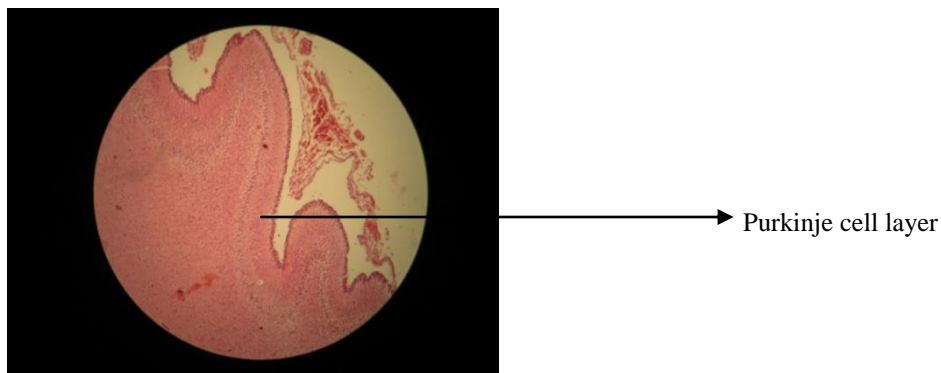


Fig. 2: Full term foetus (M), Fix-Bouin's fluid, Hand E stain, X100, section shows folial pattern, external granular layer, arrangement of Purkinje cells at the interface

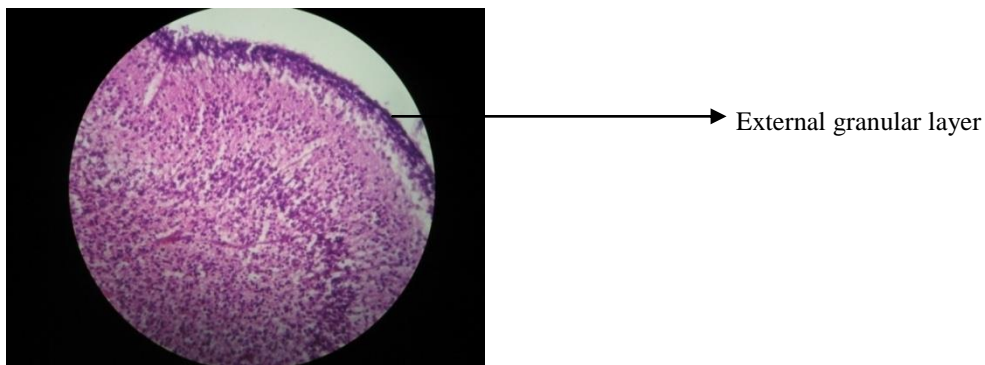


Fig. 3: Full term foetus (M), Fix-Bouin's fluid, H and E stain, X400, section shows external granular layer and arrangement of elongated cells resembling Purkinje cells.

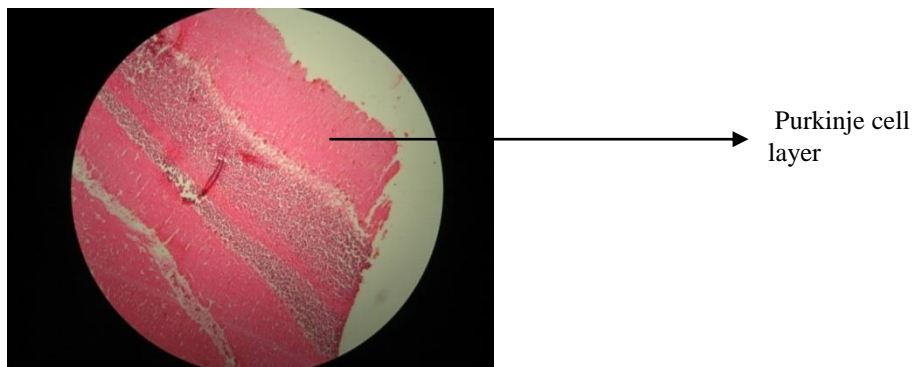


Fig. 4: Two and a half year old (F), Fix -Bouin's fluid, H and E stain, X100, section shows a well defined white matter bundle, internal granular layer, Purkinje cells layer molecular layer. Note the absence of external granular layer.

DISCUSSION

Microscopic sections from foetuses showed a well-developed external granular layer. The section from a 5-month-old foetus did not show any obvious folial pattern. The rest of the cells in the cortex appeared to be arranged as a single sheet and none of the layers were distinguishable. The external granular layer was also clearly seen in the section obtained from a full term foetus. Folia could be seen but were not as prominent as that of an adult. The rest of the cytoarchitecture resembled that of an adult cerebellum with ill-defined versions of the molecular layer, Purkinje cell layer and granular layer. These findings are in conformity with Yamaguchi *et al.* [8] who stated that in the primary stage *i.e.* Up to 18-20 weeks of gestation the cerebellar microscopy appears as a superficial layer of densely packed undifferentiated cells called external granular layer with a deeper sheet of cells with no clear morphology. In the secondary stage the internal granular layer becomes clear and is stable in thickness up to 35 weeks of gestation, after which the thickness starts increasing with the formation of cerebellar folia.

The external granular layer consists of closely packed cells. Sections obtained from two and half year old child did not show the external granular layer which confirms the findings of Raaf *et al.* [7] who stated that the external granular layer persists up to 18-20 months of age. Derek *et al.* [10] observed that the external granular layer virtually ceases to exist after 12-18 months. The present study showed that the external granular layer did not persist beyond two and a half years. According to Schienker [11], the cells of external granular layer of cerebellum can remain postnatally and form the basis for the origin of medulloblastoma. Christos *et al.* [12] in his study of human cerebellum also observed that medulloblastoma, one of the most common malignant central nervous system tumours in children are traceable to cerebellar embryogenesis.

The sections from the foetus showed a white matter core when stained with Haematoxylin and Eosin. Special staining with Luxol Fast Blue did not reveal a central core of white matter. Luxol Fast Blue is specific for the myelin sheath. In foetus, since myelination is not complete, the white matter core did not take up the stain.

REFERENCES

1. Obersteiner H; Der feinese Bau der Kleinhirnrinde beim Menschen und bei Tieren. *Biol Zentralb*, 1883; 3:145-155.
2. Schaper-Alfred; Die morphologische and histologische Entwicklung des kleinhirns der Teleostier. *Anat Anz*, 1894; 9: 489-501.
3. Popoff S; Zur Frage uber die histogenese der Kleinhirnrinde. *Biol. Zentralb*, 1895; 15: 745-752.
4. Berliner., Kurt; Beitrage zur histologic and Entwicklungsgergeschichte des Kleinhirns nebst Bemerkungen uber die entwicklung der Funktions- tuchtigkeit desselben. *Arch f Mikr Anat*, 1905; 66: 220-269.
5. Jakob A; Die feinere Anatomie des Kleinhirns, die Kleinhirnrinde. In *Handbuch der mikroskopischen Anatomie des Menschen*. Edited by von Mollendorff, Berlin, 4: 745-771.
6. Kershman J; The medulloblastoma, a study of human embryos. *Arch Neurol and Psychiatry*, 1938; 40: 937-967.
7. Raaf J, Kernohan JW; A study of the external granular layer in the cerebellum. *American Journal of Anatomy*, 1947; 12: 151-172.
8. Yamaguchi K., Goto N, Nara T; Development of human cerebellar granular layer: a morphometric study. *No To Hattal Su*, 1992; 24 (2): 327-334.
9. Mc Manus JFA, Mowry RW; Staining methods. *Histologic and Histochemical*; Paul B Hoeber, Inc. Med. Divn of Harper and Brothers, 1960: 423.
10. Derek RG, John LE; Quantitative morphological studies of developing human cerebellar cortex in various disease states. *Arhcives of diseases in childhood*, 1976; 51: 964.
11. Scheinker I; Zur Frage der Pathogenese und Pathologie der Medulloblastome. *Mschr Psychiat Neurol.*, 1939; 101: 103-113.
12. Christos DK., Luis Del Valle, Augustin L; On the neuronal / neuroblastic nature of medulloblastoma: a tribute to Pio del Rio Hortega and Moises Polak. *Acta neuropathol.*, 2003; 105:1-13.