

## Case Report

### Primary Non-Hodgkin's Lymphoma of Ascending Colon in a Child with Non Obstruction: a Case Report

Ahirwar Chandraprakash<sup>1</sup>, Verma Vijay Kumar<sup>2</sup>, Ahamed Shamim<sup>3</sup>, Abhijeet Patil<sup>4</sup>

<sup>1</sup>Assistant Professor, Department of Radiodiagnosis, Gandhi Medical College, Bhopal, India.

<sup>2</sup>Associate Professor, Department of Radiodiagnosis, Gandhi Medical College, Bhopal, India.

<sup>3</sup>Resident, Department of Radiodiagnosis, GMC, Bhopal.

<sup>4</sup>Assistant Professor, Department of Radiodiagnosis, Gandhi Medical College, Bhopal, India

#### Corresponding author

Dr. Ahirwar Chandraprakash

E-mail: [drchandraprakashradiologist@gmail.com](mailto:drchandraprakashradiologist@gmail.com)

**Abstract:** Primary tumors of the gastrointestinal tract are rare in children and represent less than 5% of all pediatric neoplasm. Non-Hodgkin's lymphoma (NHL) remains the most common malignancy of the GI tract in children. Primary non-Hodgkin's lymphoma (NHL) of the gastrointestinal tract is the most common extranodal lymphoma in pediatric age group. Yet, the overall incidence is very low. We report a case of primary lymphoma of bowel in a child who presented with non obstructive complaints.

**Keywords:** Non-Hodgkin's lymphoma, ascending colon, non obstructive complaints, CT imaging.

#### CASE REPORT

A 10 year girl child presented with complaints of on and off abdominal pain over a year. There was no history of vomiting or altered bowel movements. Local examination revealed a palpable non tender mass in the right iliac fossa region. Routine blood investigations revealed no significant abnormalities.

*X-ray abdomen* showed a homogenous soft tissue density mass lesion in the right iliac fossa, with mass

effect and displacement of the bowel loops. *USG* showed a homogenously hypoechoic mass lesion in relation to the ascending colon and caecum. *CT abdomen* with oral and IV contrast showed a circumferential thickening involving ascending colon and the caecum with preservation of a central patent lumen (*Figure- 1a* and *1c*). No evidence of retro peritoneal lymph nodes was seen. Liver and spleen were of normal attenuation with no discrete lesions.

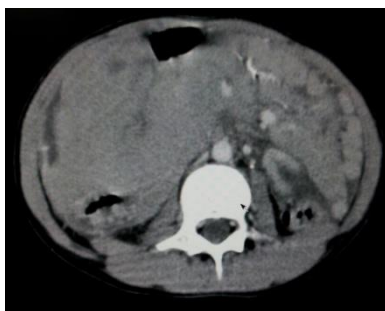

Fig.: 1a

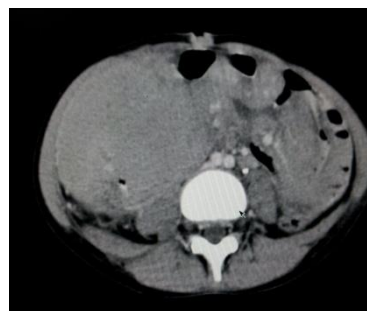

Fig.: 1b

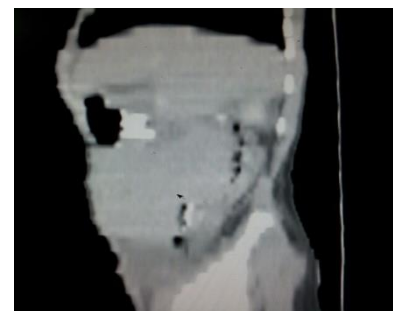

Fig.: 1c

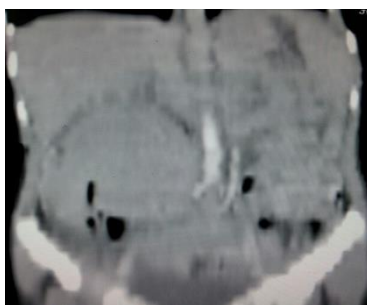


Fig.: 1d

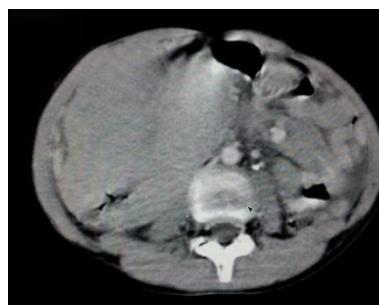

Fig.: 1e

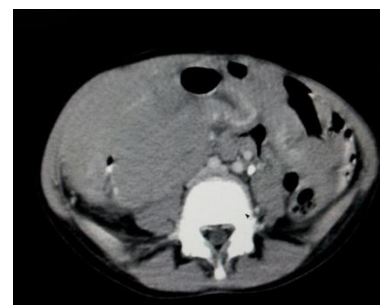

Fig.: 1f

Resection of involved segment of bowel with ilio-transverse anastomosis was done and patient was referred for chemotherapy. *Histopathology* of the resected segment confirmed the diagnosis of NON HODGKIN LYMPHOMA; DIFFUSE LARGE B-CELL type (DLBCL). The tumor was STAGE II according to the St. Jude's system for childhood NHL.

## DISCUSSION

According to criteria developed by Dawson and colleagues, primary lymphoma of GI tract includes cases with no superficial adenopathy at diagnosis, no mediastinal adenopathy at chest radiography, normal blood cell counts, no involvement of liver and spleen, and involvement of only regional lymph nodes at laparotomy [1]. Primary GI malignancies are a rarity in children, with limited information from Asian population [2]. The peak age for NHL of GI tract in children is 5–15 years [3]. Unlike adult patients in whom stomach is the most frequent site, small and large intestines are the most commonly involved sites in pediatric age group [4]. There is a female predominance with male to female ratio ranging from 7:1 to 1.8–2.5: 1 in various studies [5, 6].

The commonest presenting symptom is reported to be abdominal pain (81.4%), followed by abdominal swelling, vomiting, constipation, diarrhea, and intestinal obstruction [6]. Nearly 50% of children with GI NHL have tumor infiltrates confined to GI tract with possible regional lymph node involvement [5].

The diagnostic workup for gastrointestinal lymphoma, like any other form of non-Hodgkin's lymphoma, is definitive by tissue diagnosis. Cross-sectional imaging is necessary to determine the distribution, severity, and staging to implement appropriate therapy. Imaging techniques most often used include ultrasound, CT, PET/CT, gallium scintigraphy, and bone scintigraphy. Ultrasound is used initially if a child presents with an abdominal or pelvic mass. CT would often follow ultrasound to allow a more global assessment for bowel and visceral involvement as well as tumor staging. Because of concerns about radiation risk to oncology patients, particularly in children, with repeat imaging examinations, the role of MRI is likely to increase.

Recently PET/CT has become the preferred functional imaging technique both for initial staging and for evaluation response to treatment in children with lymphoma because of a shorter interval between injection and imaging, completion of the studies in only a few hours, and improved image quality. PET/CT has been shown to reveal disease sites that were not previously identified, leading to upstaging of the disease [7]. PET/CT also has better dosimetry, which is

particularly important when imaging children, in comparison with gallium scintigraphy [8].

The approach to extensive gut lymphoma varies widely amongst physicians. A conservative approach consists of limited resection of obstructed or perforated segment, followed by whole abdomen radiation. However, several authors have argued for aggressive surgical debulking of all intestinal lymphomas, including stage III or IV disease [9]. Radical tumor resection followed by chemotherapy in early disease, and limited or no resection followed by polychemotherapy in advanced disease may be the justified approach. However, recent studies have proposed the use of chemotherapy alone as an effective treatment option in primary GI lymphoma in all stages [10]. Despite controversies regarding treatment, the disease stage at presentation remains the most important criterion determining survival [11]. Histologic type of the disease did not affect the survival.

## CONCLUSION

Pediatric primary gastrointestinal lymphoma is a rare pathology, where CT is not diagnostic but comes more than handy for disease staging and management.

## REFERENCES

1. Dawson I, Cornes J, Morson B; Primary malignant lymphoid tumors of the intestinal tract. Report of 37 cases with a study of factors influencing prognosis. *Br J Surg.*, 1961; 49: 80–89.
2. Khurshed A, Ahmed R, Bhurgrri Y; Primary gastrointestinal malignancies in childhood and adolescence: An Asian perspective. *Asian Pac J Cancer Prev.*, 2007; 8: 613–617.
3. Bethel CA, Bhattacharyya N, Hutchinson C, Ruymann F, Cooney DR; Alimentary tract malignancies in children. *J Pediatr Surg.*, 1997; 32: 1004–1008.
4. Jacobson MA, Hutcheson AC, Hurray DH, Metcalf JS, Thiers BH; Cutaneous involvement by Burkitt lymphoma. *J Am Acad Dermatol.*, 2006; 54: 1111–1113.
5. Ladd AP, Grosfeld JL; Gastrointestinal tumors in children and adolescents. *Semin Pediatr Surg.*, 2006; 15: 37–47.
6. Morsi A, Abd El-Ghani Ael-G, El-Shafiey M, Fawzy M, Ismail H, Monir M; Clinicopathological features and outcome of management of pediatric gastrointestinal lymphoma. *J Egypt Natl Canc Inst.*, 2005; 17: 251–259.
7. Jadvar H, Connolly LP, Fahey FH, Shulkin BL; PET and PET/CT in pediatric oncology. *Semin Nucl Med.*, 2007; 37: 316–331.

8. Bar-Shalom R, Mor M, Yefremov N and Goldsmith SJ; The value of Ga-67 scintigraphy and F-18 fluorode-oxyglucose positron emission tomography in staging and monitoring the response of lymphoma to treatment. *Semin Nucl Med.*, 2001; 31:177-190.
9. Herrmann R, Panahon AM, Barcos MP, Walsh D, Stutzman L; Gastrointestinal involvement in non- Hodgkin's lymphoma. *Cancer.* 1980; 46: 215–222.
10. Raina V, Sharma A, Vora A, Shukla NK, Deo SV, Dawar R; Primary gastrointestinal non-Hodgkin lymphoma chemotherapy alone an effective treatment modality: Experience from a single center in India. *Indian J Cancer*, 2006; 43: 30–35.
11. Zinzani PL, Magagnoli M, Pagliani G, Bendandi M, Gherlinzoni F, Merla E et al.; Primary intestinal lymphoma: Clinical and therapeutic features of 32 patients. *Haematologica.*, 1997; 82: 305–308.