

Symptomatic Medial Humeral Epicondylar Fracture Nonunion – Case Report

Rachid Maanouk*, A. Baroudi, Y. Slaoui, H. Abid, M. El Idrissi, A. El Ibrahimy, A. El Mrini

Department of Orthopedic, University Hospital Center HASSAN II Fez, 30000 fez, Morocco

DOI: [10.36347/sajs.2020.v06i03.007](https://doi.org/10.36347/sajs.2020.v06i03.007)

| Received: 10.02.2020 | Accepted: 16.02.2020 | Published: 18.03.2020

*Corresponding author: Rachid Maanouk

Abstract

Case Report

Symptomatic nonunion of medial humeral epicondylar fractures is a rare entity. Surgical technique can be difficult because of anatomical, biomechanical factors such as the high tension and the torsional forces applied from the flexor-pronator tendon origin. In the literature, there are a few cases of humeral medial epicondyle treated by open reduction and internal fixation. We described the case of one patient with symptomatic medial humeral epicondyle nonunion who underwent open reduction and internal fixation with excellent clinical evolution after one year of follow-up from time of surgery. The purpose of this study is to evaluate the outcome of open reduction and internal fixation of a medial epicondyle nonunion fragment about one case and review of littérature.

Keywords: Symptomatic nonunion, epicondylar fractures, Surgical technique.

Copyright © 2020: This is an open-access article distributed under the terms of the Creative Commons Attribution license which permits unrestricted use, distribution, and reproduction in any medium for non-commercial use (NonCommercial, or CC-BY-NC) provided the original author and source are credited.

INTRODUCTION

Fractures of the medial humeral epicondyle are relatively common in children [1]. Non-displaced medial epicondyle fractures of humerus are best treated by conservative methods. Intra-articular displaced fractures, fractures with ulnar nerve entrapment, and unstable fractures should be treated with open reduction and internal fixation (ORIF) [1-3]. There are some controversies about the treatment methods of displaced extra-articular fractures of humeral medial epicondyle. Nonunion rates of displaced extra-articular medial humeral epicondyle fractures are reported as high as 90% however most of them remain asymptomatic without any functional deficit [4, 5]. Although not common, symptomatic medial humeral epicondyle nonunion could be disabling for patients with a painful and instable medial collateral ligament (MCL) deficient elbow. Moreover missed incarceration of the medial epicondyle with ulnar nerve entrapment in the joint can lead to chronic painful stiff elbow with ulnar nerve neuropathy [6]. Another controversy is about the treatment of symptomatic medial condyle non-union. Excision of the fragment is recommended in several reports however excision is not a solution for instability [4, 7]. Satisfactory results were reported with ligamentous repair with the excision of the fragment [4, 7]. Although achieving osseous union with ORIF is difficult due to small fragment size and hardware prominence, it is the optimal way to restore distal

humerus anatomically and therefore obtain normal biomechanics of the elbow joint.

The purpose of this study is to evaluate the outcome of open reduction and internal fixation of a medial epicondyle nonunion fragment about one case and review of littérature.

CASE PRESENTATION

We report the case of a patient admitted to the orthopedic department of the Hassan II hospital center in Fès. She is a 27 year old patient, student, with no pathological history, who presents an old trauma of the right elbow, due to a fall in height with direct reception, the patient did not initially consult. 3 years later the patient consults for right elbow pain with VAS at 5/10, and paraesthesia on the territory of the ulnar nerve. The clinical examination objectified a limitation of the mobility of the right elbow to 10° -110°, with pain on palpation of the medial epicondylar, instability in valgus and without sensory-motor deficit in particular of the ulnar nerve. MEPS (Mayo Elbow Performance Score) at 40 and Q-DASH (Disability of Arm, Shoulder, and Hand) score at 72.7.

Standard frontal and lateral radiographs showed non-union of the epitrochlea with a small fragment displaced infero-anterior (Figure-1).

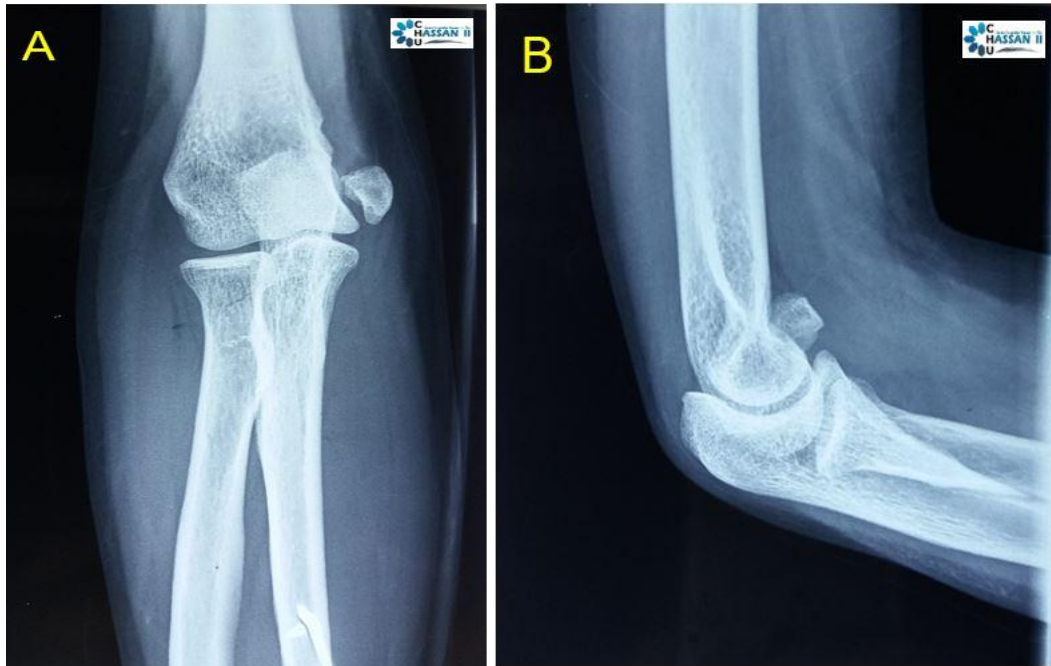


Fig-1: Standard frontal (A) and lateral (B) radiographs showed non-union of the medial humeral epicondylar fracture

In the operating room, in lateral decubitus under general anesthesia with a tourniquet on the root of the limb (Figure-2).

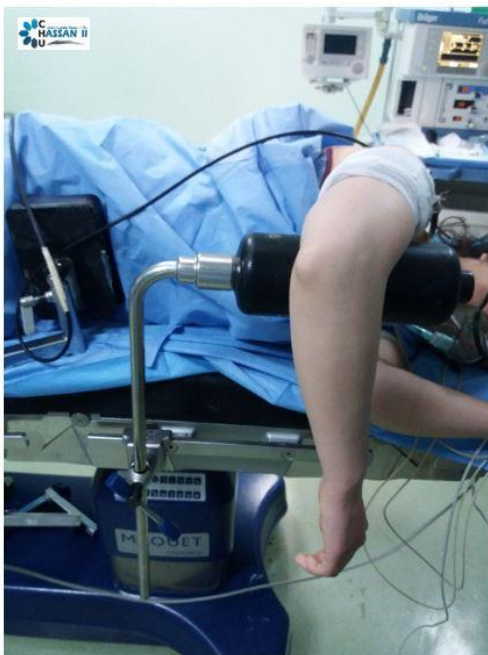

Fig-2: Installation of the patient in lateral decubitus

Via the postero-internal approach of the right elbow, she initially benefited from an anterior transmuscular release and transposition of the ulnar

nerve which was incarcerated in an interfragmatory fibrosis (Figure-3).

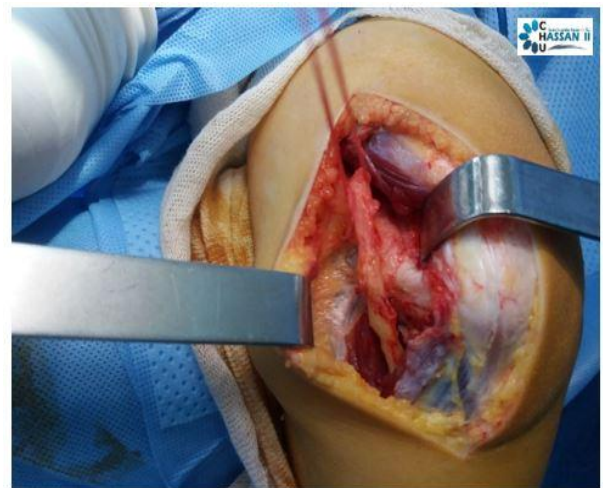


Fig-3: Release of the ulnar nerve

Then in a second phase of a reduction of the fragment of the epitrochlea after re-awakening (Figure-4) and fixing by a cancellous screw 3.5 associated with a graft of cancellous bone taken from the olecranon (Figure-5). Immobilization with a bandage elbow to the body for 3 weeks was performed.

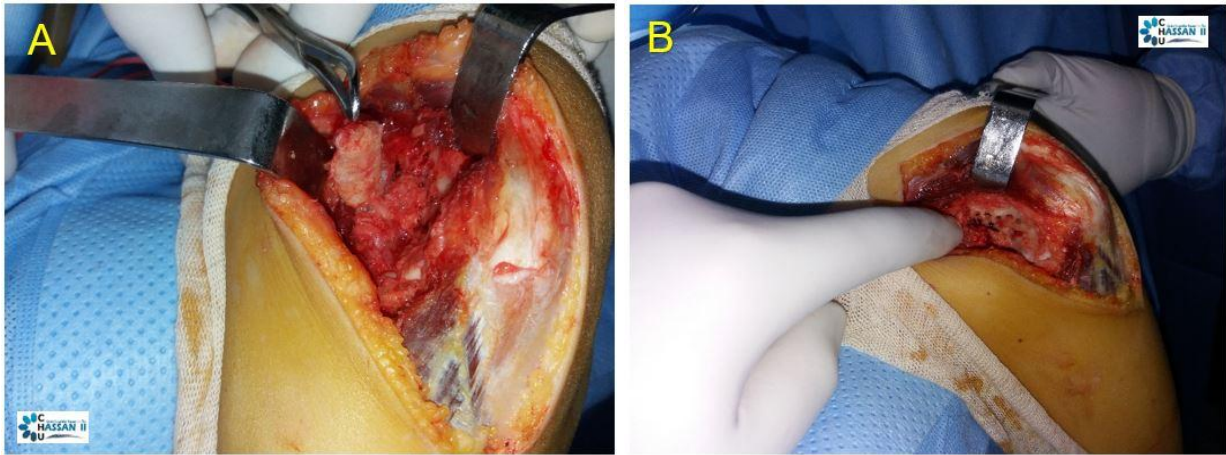


Fig-4: Re-Awakening of the fragment of the epitrochlea (A) and the medial side of the humerus (B)

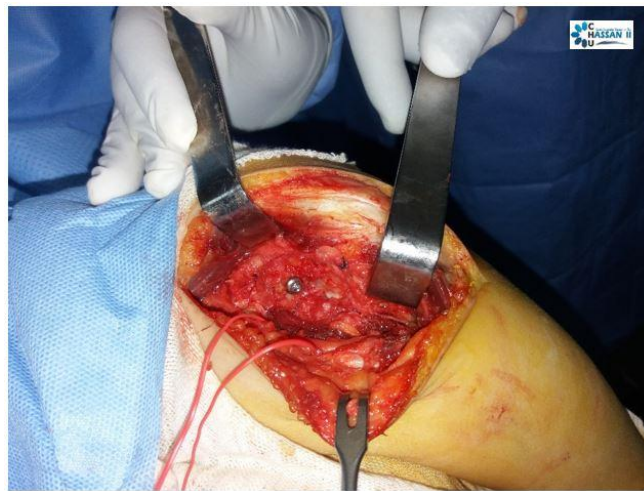


Fig-5: Fixation of the medial epicondylar by a cancellous screw 3.5

The immediate post-operative follow-ups were simple, functional rehabilitation was started after 3 weeks. The evolution was marked by the disappearance of the pain with a marked reduction in paraesthesia of the ulnar nerve.

Radiology has objectified a consolidation of the fragment of the medial epicondylar after 3 months of follow-up (Figure-6).

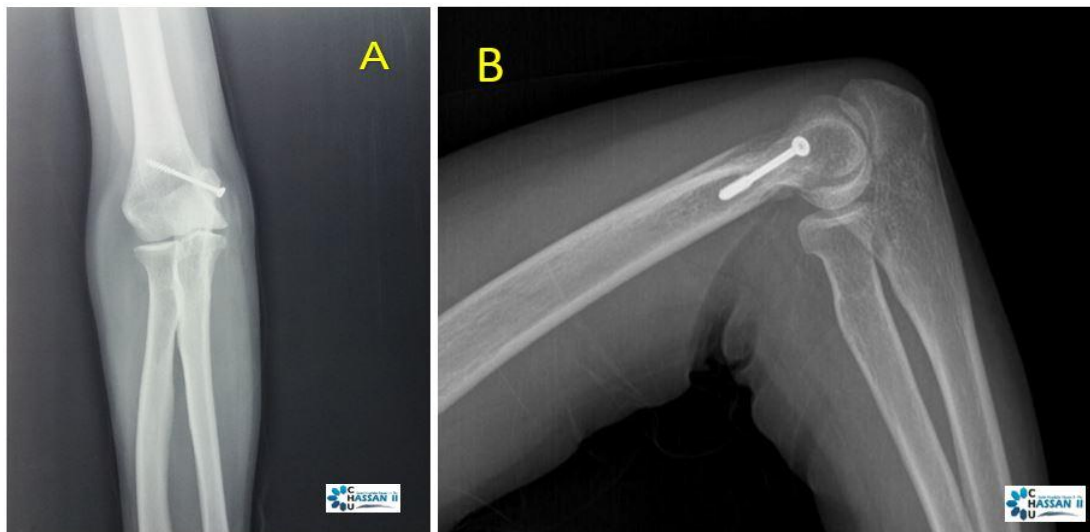


Fig-6: Standard frontal (A) and lateral (B) radiographs showed a consolidation of the fragment of the medial epicondylar

After 15 months of follow-up the patient was satisfied with the surgical treatment with disappearance of pain (EVA score at 0), a MEPS score (Mayo Elbow Performance Score) at 85 and Q-DASH score (Disability of Arm, Shoulder, and Hand) to 9.1.

DISCUSSION

Conservative management often serve well in case of acute injuries, non-displaced or minimally displaced fractures (according to Wilkins classification) [8] or Papavasiliou [9] type 1 fracture, i.e., small degree of avulsion of the epicondylar fragment. Although the frequency of non-union or fibrous union in these conservatively treated patients is fairly high [1, 10-12], most patients remain asymptomatic. Although rare, only a small percentage of these patients remain symptomatic, according to an established nonunion [1, 13], probably because of greater impact of injuries leading to severe soft tissue injuries and dislocations. This category of patients poses a great challenge in the management of these fractures.

There have been controversies in the surgical management of these fractures. Fowles *et al.*, [14] reported good results in three patients who had had excision of the epicondyle for the treatment of an old fracture with entrapment of the fragment in the elbow joint, which was almost ankylosed at the time of surgery. After surgery, the range of motion of the elbow improved a great deal in all three patients, but the maximum duration of follow-up was only 20 months.

Gilchrist *et al.*, [15], on the basis of his experience with five patients, reported that excision of the non-union fragment and repair of the medial collateral ligament to the distal humerus can provide satisfactory outcomes in these patients.

Vidisha S. Kulkarni *et al.*, [16], reported a retrospective study consisted of 14 patients. After open reduction and internal fixation (ORIF), patients reported an improvement in visual analogue pain score from a mean of 7.29 ± 1.3 to 0.21 ± 0.4 , and the difference was statistically significant ($p=0.001$). Mean postoperative Quick DASH (Disability of Arm, Shoulder, and Hand) score was 5.21 ± 7.2 . Mean Mayo Elbow Performance Score was 96.7 ± 6.1 . Improvement in arc of motion was statistically significant ($p=0.001$). Bony union was achieved in 13 patients and one patient had a fibrous union.

Similarly, a study by Smith *et al.*, with ORIF by one or two cannulated screws in 8 children of medial humeral epicondyle nonunion showed improved outcomes, and pain relief without any complication [17].

Mehmet Erdil *et al.*, [18] reported a retrospective study consisted of 4 patients with Symptomatic nonunion of humeral medial epicondyle,

we used one 4.0 mm cannulated screw for fixation with a mixture of spongious chips bone allograft and 5 ml DBM for bone grafting. they had significant improvements with MEPS and q-DASH scores and elbow range of motion in a mean follow-up of 13.75 months. There were no surgical complications and no patient had a weakness and/or instability. Osseous union was achieved which was documented with postoperative plain radiographs.

CONCLUSION

In conclusion, According to our results and after review of literature, symptomatic medial epicondyle fracture nonunion can be treated with one cannulated screw accompanied by ulnar nerve transposition. Open reduction and internal fixation gives excellent clinical and functional outcome. Excellency of the outcome is dependent on careful dissection medially, to find out incarcerated medial epicondyle without crushing it, secure anatomic reduction of the fragment, proper release of the contracture in long standing cases and early mobilization. The preferred method of internal fixation demands further comparative studies with larger sample size.

REFERENCES

1. Farsetti P, Potenza V, Caterini R, Ippolito E. Long-term results of treatment of fractures of the medial humeral epicondyle in children. *Journal Bone Joint Surgery Am*, 2001;83-A(9):1299–305.
2. Beaty JH, Kasser JR. Fractures involving the medial epicondylar apophysis. In: Beaty JH, Kasser JR, editors. *Fractures in children*. 6th ed. Philadelphia, PA: Lippincott Williams and Wilkins; 2006, 629–42
3. Woods GW, Tullos HS. Elbow instability and medial epicondyle fractures. *Am J Sports Med*, 1977;5:23–30.
4. Farsetti P, Potenza V, Caterini R. Long-term results of treatment of fractures of the medial humeral condyle in children. *J Bone Joint Surg [Am]*, 2001;83: 1299–305.
5. Josefsson PO, Danielsson LG. Epicondylar elbow fracture in children: 35 year follow-up of 56 unreduced cases. *J Shoulder Elbow Surg*, 1986;57: 313–5.
6. Tarallo L, Mugnai R, Fiacchi F, Adani R, Zambianchi F, Catani F. Pediatric medial epicondyle fractures with intra-articular elbow incarceration. *J Orthop Traumatol*, 2015;16(2):117–23.
7. Gilchrist AD, McKee MD. Valgus instability of the elbow due to medial epicondyle nonunion: treatment by fragment excision and ligament repair – a report of 5 cases. *Orthop Scan*, 2002;11:493–7
8. Ke W. Fractures involving the medial epicondylar apophysis. In: Rockwood CA

- Jr WK, King RE, editors. Rockwood and Wilkins' fractures in children. 3rd ed. Philadelphia, PA: JB Lippincott; 1991:509–828.
9. Papavasiliou VA. Fracture-separation of the medial epicondylar epiphysis of the elbow joint. *Clin Orthopaedics Related Res*, 1982(171):172–4.
 10. Josefsson PO, Danielsson LG. Epicondylar elbow fracture in children: 35-year follow-up of 56 unreduced cases. *Acta Orthop Scand*, 1986;57(4):313–5.
 11. Dias JJ, Johnson GV, Hoskinson J, Sulaiman K. Management of severely displaced medial epicondyle fractures. *J Orthop Trauma*, 1987;1(1):59–62.
 12. Hines RF, Herndon WA, Evans JP. Operative treatment of medial epicondyle fractures in children. *Clin Orthop Related Res*, 1987(223):170–4.
 13. Erdil M, Bilsel K, Ersen A, Elmadag M, Tuncer N, Sen C. Treatment of symptomatic medial epicondyle non-union: case report and review of the literature. *Int J Surg Case Reports*, 2012;3(9):467–70.
 14. Fowles JV, Kassab MT, Moula T. Untreated intra-articular entrapment of the medial humeral epicondyle. *J Bone Joint Surg Br*, 1984;66(4):562–5.
 15. Gilchrist AD, McKee MD. Valgus instability of the elbow due to medial epicondyle non-union: treatment by fragment excision and ligament repair--a report of 5 cases. *J Shoulder Elbow Surg*, 2002;11(5):493–7.
 16. Kulkarni VS, Arora N, Gehlot H, Saxena S, Kulkarni SG, Bajwa S. Symptomatic medial humeral epicondylar fracture non-union-rare presentation of a relatively common injury. *Injury*. 2017 Aug 1;48:S50-3.
 17. Smith JT, McFeely ED, Bae DS, Waters PM, Micheli LJ, Kocher MS. Operative fixation of medial humeral epicondyle fracture nonunion in children. *J Pediatr Orthop*, 2010;30(October–November (7)):644–8
 18. Erdil M, Bilsel K, Ersen A, Elmadag M, Tuncer N, Sen C. Treatment of symptomatic medial epicondyle nonunion: Case report and review of the literature. *International journal of surgery case reports*. 2012 Jan 1;3(9):467-70.