

Parathyroid Adenoma with Brown Tumor of Tibia and Acute Pancreatitis – A Rare Case

Dr. Sneha Hemachandran^{1*}, Dr. Rohit K², Dr. Amit Kumar C Jain², Dr. (Brig) Rajagopalan S³

¹Resident, Department of General Surgery, Rajarajeswari Medical College and Hospital, Bangalore, India

²Associate Professor, Department of General Surgery, Rajarajeswari Medical College and Hospital, Bangalore, India

³Head of Department and Professor, Department of General Surgery, Rajarajeswari Medical College and Hospital, Bangalore, India

DOI: [10.36347/sasjs.2020.v06i03.014](https://doi.org/10.36347/sasjs.2020.v06i03.014)

| Received: 09.03.2020 | Accepted: 16.03.2020 | Published: 21.03.2020

*Corresponding author: Dr. Sneha Hemachandran

Abstract

Case Report

Parathyroid Adenoma is subset of parathyroid proliferative disorders which includes parathyroid hyperplasia, parathyroid adenoma and parathyroid carcinoma. Patients usually present with evidence of primary hyperparathyroidism and raised serum calcium and serum parathyroid hormone levels. We report an interesting and unique case of parathyroid adenoma with brown tumor of tibia and acute pancreatitis.

Keywords: Parathyroid Adenoma, Brown Tumor, Acute Pancreatitis, Primary Hyperparathyroidism.

Copyright @ 2020: This is an open-access article distributed under the terms of the Creative Commons Attribution license which permits unrestricted use, distribution, and reproduction in any medium for non-commercial use (NonCommercial, or CC-BY-NC) provided the original author and source are credited.

INTRODUCTION

Parathyroid adenomas are the most common cause of primary hyperparathyroidism. 80% - 85% of primary hyperparathyroidism is caused by parathyroid adenoma followed by primary parathyroid hyperplasia (15%) and parathyroid carcinoma (5%). The symptoms produced by hyperplasia of parathyroid glands have been commonly classified into a) skeletal changes b) urinary changes c) biochemical changes (hypercalcemia) [1].

Brown tumor is a non-neoplastic giant cell lesion characterized by elevated circulating levels of parathyroid hormone (PTH). This tumor represents the terminal stage of bone remodeling processes in hyperparathyroid state. It is usually an uncommon lesion occurring with the frequency of 4.5% in primary hyperparathyroidism (HPT) and 1.5-1.7% in cases of secondary HPT, with overall incidence of 0.1% [2]. The causes of pancreatitis are largely dominated by gallstones and alcohol. Primary hyperparathyroidism (PHPT) is rarely associated with the development of pancreatitis.

CASE PRESENTATION

A 48-year-old female patient presented with chief complaints of pain left leg of 2 months and inability to bear weight on the left leg following a fall 1 month earlier. No significant past history. Physical examination revealed tenderness along the middle 1/3rd of tibia. No other significant finding. X-ray leg revealed

a unicortical fracture of left tibia along a homogenous benign tumor like lesion. MRI left leg showed expansile thick walled lytic lesion in the diaphysis of tibia, features in favor of Fibrous dysplasia with pathological fracture anterior cortex of shaft.

Biochemical assay and blood analysis revealed an increased value of serum PTH-2137pg/ml (normal range: 50-300 pg/ml), serum calcium-17.2 mgs/dl (normal range: 8.5-11.0 mg/dl), Normal Total Vitamin D -38.3ng/ml (normal range: >30ng/ml), Increased serum ALP -665 U/L (normal range: 20-140 U/L), Urine routine revealed calcium oxalate crystals.

With suspicion of PTH USG neck was done which reported well defined oval hypoechoic lesion posterior to thyroid gland on right side- Parathyroid adenoma. MRI neck showed a homogeneously enhanced lesion in the right supraclavicular area- parathyroid adenoma.

Patient underwent Parathyroid adenoma excision. Following surgery PTH and serum calcium levels were found to be normal within 2 days after surgery. Patient then developed features of Acute abdomen on Post-operative day 3, NCCT abdomen and pelvis was done which showed features of Acute Pancreatitis with pleural effusion. It also revealed bilateral renal calculi 12x6mm (left side) and 10x7mm (right side) with no obstructive features. Investigations revealed, Serum amylase-1225 U/L Serum Lipase- 688 U/L Serum Calcium 11.2 mg/dl. Patient was managed

conservatively with adequate fluids and regular monitoring following which the patient improved symptomatically. On post-operative day 14 blood values revealed Serum amylase - 45 U/L serum lipase - 56 U/L PTH - 112 pg/ml. Bone biopsy of the lytic lesion on the tibia was done which showed presence of

many multinucleated giant cells of osteoclast with interstitial hemorrhage, and clusters of hemosiderin laden macrophages. A slab was applied for the unicortical fracture and patient was discharged and advised to review once in 2 weeks for follow up.

	Pre-operative	Post-operative Day 2	Post-operative Day 14
1.PTH	2137pg/ml	145pg/ml	112pg/ml
2.Sr.Ca	17.2mg/dl	9.4mg/dl	8.2mg/dl

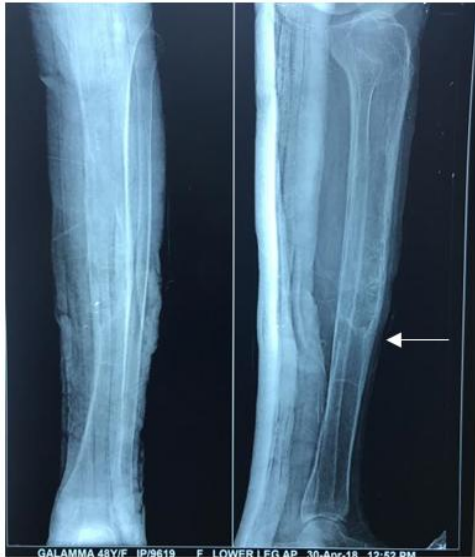

Fig-1: Unicortical Fracture of tibia

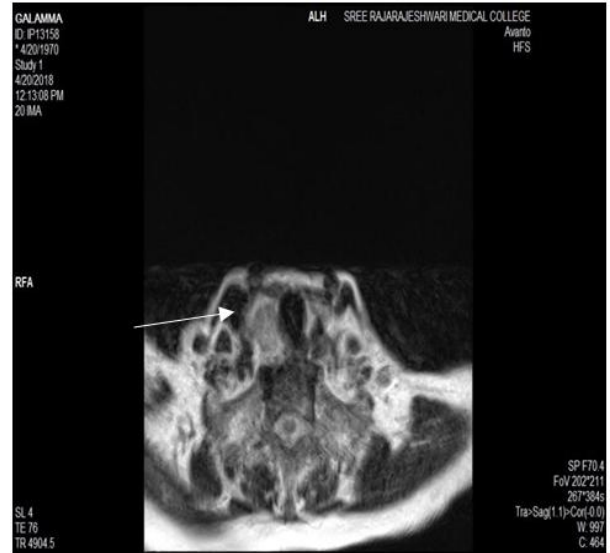


Fig-2: MRI Neck showing Parathyroid adenoma

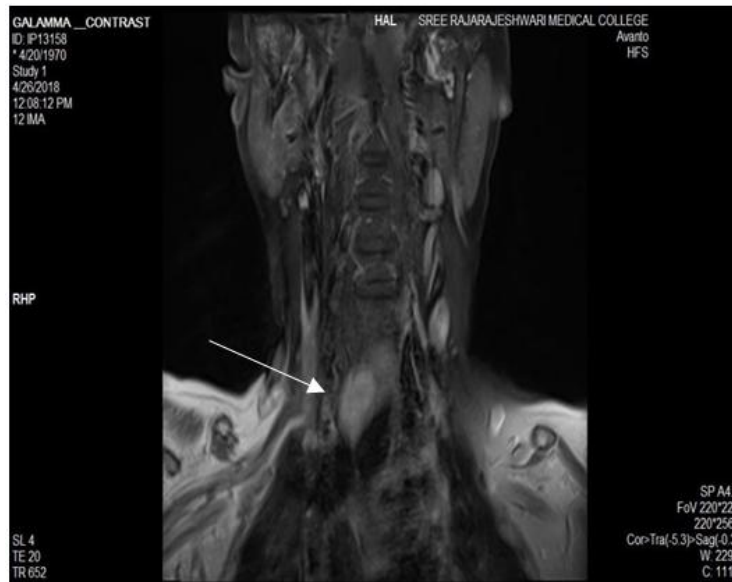

Fig-3: MRI neck showing Parathyroid Adenoma

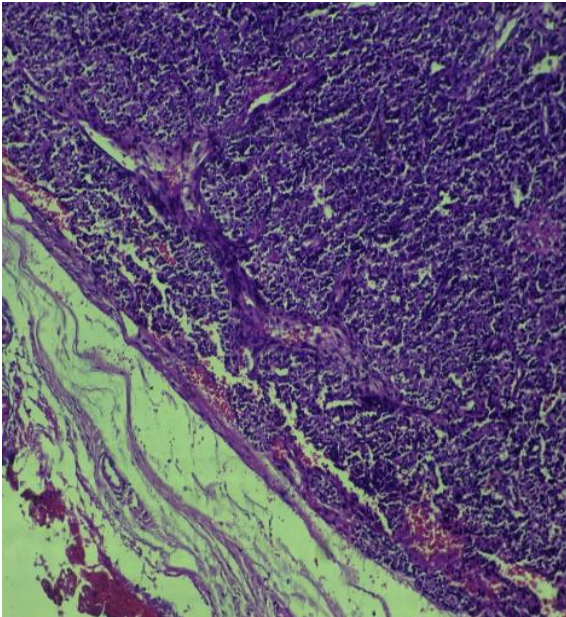


Fig-4: Parathyroid Adenoma showing lack of adipocytes

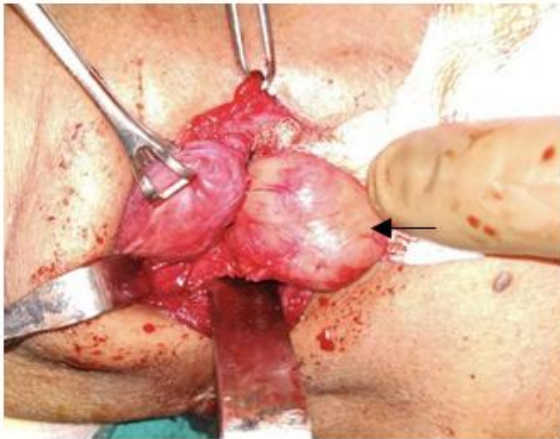


Fig-5: Parathyroid Adenoma Identified posterior to the right inferior pole of thyroid

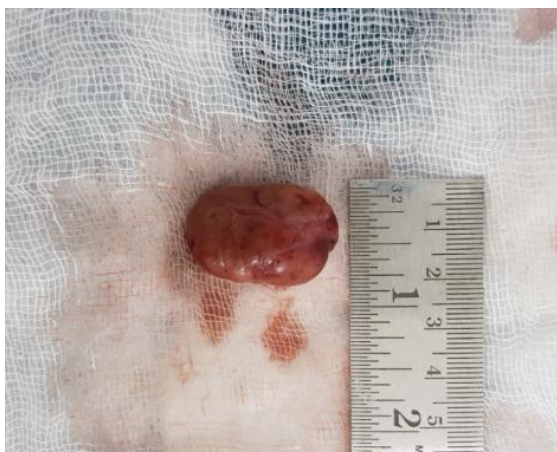

Fig-6: Parathyroid Adenoma (post excision)

DISCUSSION

Hyperparathyroidism is divided into primary, secondary, and tertiary hyperparathyroidism. Most parathyroid hyperplasia is an outcome of secondary hyperparathyroidism due to renal disease. Primary hyperparathyroidism occurs due to hyperplasia, benign or malignant neoplasm of one or more parathyroid gland. Secondary hyperparathyroidism is caused as a result of hypocalcemia, vitamin D deficiency or secondary to chronic renal insufficiency, that acts as a stimulus for PTH production. Tertiary hyperparathyroidism is the autonomous secretion of parathyroid hormone in the setting of long-standing renal disease which results in hypercalcemia. The fourth type of HPT has been recognized, which occurs due to elevated PTH levels synthesized in patients with malignant diseases [3].

Preoperative localization of the hyper-functioning parathyroid gland/glands is considered very important prior to definitive surgical management [4]. Several diagnostic localization methods, both invasive and noninvasive exists, which range from ultrasound, CT scans, magnetic resonance imaging, Tc99m SestaMIBI scintigraphy and PET scanning in the preoperative setting and gamma probe and intraoperative parathyroid hormone assays in the intraoperative setting. Preoperative localization studies with two concurrent imaging techniques (combined ultrasound and Tc99m SestaMIBI scintigraphy) are increasingly becoming popular as they enable minimally invasive surgical approaches [5]. Nuclear imaging with parathyroid scintigraphy is the primary and standard method used for preoperative localization. The sensitivity of Tc99m SestaMIBI scintigraphy in detecting parathyroid adenomas has been reported to range from 70% to 100% [6, 7]. Even though the role of 18F-FDG PET/CT scans in identifying parathyroid carcinomas is well established, its use in the localization of parathyroid adenomas has yet to be widely utilized [8]. A recent study reported that clinicians should possibly consider PET-CT as a second line modality when conventional imaging fails to localize the hyper functioning parathyroid gland [9]. Since the above mentioned modalities were unavailable in our hospital setting, we proceeded ahead with surgery.

The prevalence of pancreatitis secondary to PHPT is reported to be <10% [10, 11]. The discovery of a pancreatic disease increases by 33 the risk of having a PHPT [12], while the existence of PHPT would multiply by a factor of 10 to 30 the risk of pancreatitis [12-14]. Pancreatitis occurs at an advanced stage of parathyroid disease [13], which would explain the low prevalence of this association in the developed countries, PHPT being diagnosed earlier.

The mean age at diagnosis is variable, but patients are older than those with only PHPT [12, 15]. They are young adults in midlife in the cases described in India and Latin America [12, 16, 17], while patients were older (60–70 years) in the United States and France [15, 18]. The mechanism of pancreatitis during PHPT remains controversial but may be related to hypercalcemia¹⁵. Shah suggested that a high calcium level in more than 1.3 times normal was associated with a risk of occurrence of an AP [19]. During PHPT, serum calcium is generally higher in patients with pancreatitis than those who have only PHPT [12, 18, 20]. Hypercalcemia would act by several mechanisms: increased level of calcium in pancreatic juice at the origin of activation of trypsinogen to trypsin; activation of pancreatic enzymes through the lysosomal system and hydrolases; calcium precipitation and formation of protein plugs responsible for upstream pancreatitis. Indeed, mutation of SPINK1 gene (Serine Protease Inhibitor Kazal type I) and CFTR gene (Cystic Fibrosis Transmembrane Conductance Regulator) was found more often in patients with PHPT who developed an AP [20].

Surgical excision of the hyper functioning gland is the treatment of choice for parathyroid adenomas [21]. The surgical approach for an inferior giant parathyroid adenoma extending on to the mediastinum can be cumbersome and may require a full collar incision or occasionally a median sternotomy. Our case demonstrates that a focused trans-cervical excision of parathyroid adenoma is a viable approach for resection of small tumors and should be considered prior to a formal neck exploration or sternotomy. Further it is believed that following aggressive medical management of acute pancreatitis, parathyroidectomy can improve the clinical outcome and prevent further recurrences of pancreatitis [11].

PTH plays a key role in calcium and phosphate balance between extracellular fluid and bones. Brown tumor is relatively an uncommon lesion associated with HPT, which results in an abnormal osteoclastic and osteoblastic activity resulting in resorption and fibrous replacement of the bone.² Brown tumor is more commonly found in ribs, clavicles, pelvis, femur and facial bones. Brown tumor mimics giant cell lesions and it can be distinguished from the latter based upon the clinical history and biochemical profile of the patient indicating HPT [22]. Histopathologically, brown tumor reveals multinucleated giant cells in a background of spindle cell proliferation along with a large amount of hemosiderin deposition, vascularity and hemorrhage giving brown appearance to this lesion [2, 22]. The treatment of brown tumor mainly focuses on correction of the underlying disorder and maintenance of normal PTH and serum calcium levels. Long-term follow-up of such lesion is mandatory as variable clinical behavior of the lesion following normalization of the PTH and serum calcium levels has been reported [23].

Ultra sonographic scan, CT scan and full body skeletal survey in conjunction with complete biochemical analysis can be carried out to assess the pathological parathyroid gland and extent of lesions in long bones. The management of the brown tumor should involve early diagnosis, complete biochemical assay and full body skeletal survey followed by normalization of PTH, serum calcium and phosphorus levels and parathyroidectomy. In the absence of any pathology of anatomic parathyroid, ectopic sites should be assessed.

CONCLUSION

This is a rare case of Parathyroid Adenoma associated with 3 entities – Pancreatitis, Brown Tumor and Bilateral Renal Calculi, usually not seen together. Clinicians need a keen eye to investigate and diagnose a case of parathyroid adenoma as it presents with a variety of symptoms as parathyroid adenoma has multiple facets, if only one facet is focused on the rest will be missed. It is an easily manageable case provided a clinician is aware of the different presentations of parathyroid adenoma and also needs a multidisciplinary approach.

ABBREVIATIONS

- **PTH-** Parathyroid Hormone
- **HPT-** Hyperparathyroidism
- **PHPT-** Primary Hyperparathyroidism
- **AP-** Acute Pancreatitis
- **CP-** Chronic Pancreatitis

REFERENCES

1. Albrigh F, Reifenstein EC. The Parathyroid Glands and Metabolic Bone Disease. Williams and Wilkins, 1948.
2. Soundarya N, Sharada P, Prakash N, Pradeep GL. Bilateral maxillary brown tumors in a patient with primary hyperparathyroidism: Report of a rare entity and review of literature. *Journal of oral and maxillofacial pathology: JOMFP*. 2011 Jan;15(1):56.
3. Selvi F, Cakarer S, Tanakol R, Guler SD, Keskin C. Brown tumour of the maxilla and mandible: A rare complication of tertiary hyperparathyroidism. *Dentomaxillofac Radiol*, 2009;38:53–8.
4. Garas G, Poulasouchidou M, Dimoulas A, Hytioglou P, Kita M, Zacharakis E. Radiological considerations and surgical planning in the treatment of giant parathyroid adenomas. *Ann R Coll Surg Engl*, 2015;97:e64–6.
5. Sukan A, Reyhan M, Aydin M, Yapar AF, Sert Y, Canpolat T, et al. Preoperative evaluation of hyperparathyroidism: The role of dual-phase parathyroid scintigraphy and ultrasound imaging. *Ann Nucl Med*, 2008;22:123–31.
6. Phitayakorn R, McHenry CR. Incidence and location of ectopic abnormal parathyroid glands. *Am Journal Surg*, 2006;191:418–23.

7. Santiago Chinchilla A, Ramos Font C. Muros de Fuentes MA, Navarro-Pelayo Láinez M, Palacios Gerona H, Moreno Caballero M, et al. False negative of the scintigraphy with 99m-Tc-sestamibi in parathyroid carcinoma with associated brown tumors. *Contributions of the 18F-FDG-PET/CT*. *Rev Esp Med Nucl*. 2011;30(3):174-9.
8. Neumann DR, Esselstyn CB, MacIntyre WJ, Go RT, Obuchowski NA, Chen EQ, Licata AA. Comparison of FDG-PET and sestamibi-SPECT in primary hyperparathyroidism. *Journal of Nuclear Medicine*. 1996 Nov 1;37(11):1809-14.
9. Kluijfhout WP, Vriens MR, Valk GD, Barth RE, Rinkes IH, de Keizer B. 18F-Fluorocholine PET-CT enables minimal invasive parathyroidectomy in patients with negative sestamibi SPECT-CT and ultrasound: a case report. *International journal of surgery case reports*. 2015 Jan 1;13:73-5.
10. Kunte AR, Dube VS, Balwantkar SS, Kulkarni KK. Parathyroid adenoma in a young female presenting as recurrent acute pancreatitis with a brown tumour of the mandible—A case study. *International journal of surgery case reports*. 2015 Jan 1;7:10-5.
11. Tun-Abraham ME, Obregón-Guerrero G, Romero-Espinoza L, Valencia-Jiménez J. Acute pancreatitis associated with hypercalcaemia. *Cirugía y Cirujanos (English Edition)*. 2015 May 1;83(3):227-31.
12. Jacob JJ, John M, Thomas N, Chacko A, Cherian R, Selvan B, Nair A, Seshadri MS. Does hyperparathyroidism cause pancreatitis? A South Indian experience and a review of published work. *ANZ journal of surgery*. 2006 Aug;76(8):740-4.
13. Bai HX, Giefer M, Patel M, Orabi AI, Husain SZ. The association of primary hyperparathyroidism with pancreatitis. *Journal of clinical gastroenterology*. 2012 Sep;46(8):656-661.
14. Vera C, Díez M, San Román R, Ratia T, Granell J. Primary hyperparathyroidism and acute pancreatitis. *Endocrinología y Nutrición*, 2013;60(5):275-276.
15. Curto C, Caillard C, Desurmont T, Sebag F, Brunaud L, Kraimps JL, Hamy A, Mathonnet M, Bresler L, Henry JF, Mirallié E. Pancréatite aiguë et hyperparathyroïdie primaire: étude multicentrique de l'Association francophone de chirurgie endocrinienne. *Journal de Chirurgie*. 2009 Jun 1;146(3):270-4.
16. Gupta AK, Madnani M, Mistry J, Soni H, Shah A, Patel KS, Mehta N, Dileep P, Chandra S, Haribhakti S. Primary hyperparathyroidism with pancreatitis: experience of management in 5 patients with review of literature. *Indian Journal of Gastroenterology*. 2014 Sep 1;33(5):484-6.
17. Janka-Zires M, Hernández-Calleros J, Gómez-Pérez FJ, Uscanga-Domínguez LF, Pelaez-Luna MC, Almeda-Valdés P. Decrease in the prevalence of pancreatitis associated with primary hyperparathyroidism: experience at a tertiary referral center. *Revista de Investigación Clínica*. 2015 May 15;67(3):177-81.
18. Khoo TK, Vege SS, Abu-Lebdeh HS, Ryu E, Nadeem S, Wermers RA. Acute pancreatitis in primary hyperparathyroidism: a population-based study. *The Journal of Clinical Endocrinology & Metabolism*. 2009 Jun 1;94(6):2115-8.
19. Shah VN, Bhadada SK, Bhansali A, Behera A, Bhattacharya A, Nahar U, Bhasin D, Vadera B. Effect of gender, biochemical parameters & parathyroid surgery on gastrointestinal manifestations of symptomatic primary hyperparathyroidism. *The Indian journal of medical research*. 2014 Feb;139(2):279-284.
20. Felderbauer P, Karakas E, Fendrich V, Bulut K, Horn T, Lebert R, Holland-Letz T, Schmitz F, Bartsch D, Schmidt WE. Pancreatitis Risk in Primary Hyperparathyroidism: Relation to Mutations in the: SPINK1: Trypsin Inhibitor (N34S) and the Cystic Fibrosis Gene. *American journal of gastroenterology*. 2008 Feb 1;103(2):368-74.
21. Haldar A, Thapar A, Khan S, Jenkins S. Day-case minimally invasive excision of a giant mediastinal parathyroid adenoma. *The Annals of The Royal College of Surgeons of England*. 2014 Jul;96(5):e21-3.
22. Triantafillidou K, Zouloumis L, Karakinaris G, Kalimeras E, Iordanidis F. Brown tumors of the jaws associated with primary or secondary hyperparathyroidism. A clinical study and review of the literature. *Am J Otolaryngol*, 2006;27:281-6.
23. Daniels JS. Primary hyperparathyroidism presenting as a palatal brown tumor. *Oral Surg Oral Med Oral Pathol Oral Radiol Endod*, 2004;98:409-13.