

## Case Report: Gallbladder Adenomyomatosis (ADM)

Soumeya Ettahiri<sup>1\*</sup>, Tarik Souiki<sup>1</sup>, Karim Ibn Majdoub<sup>1</sup>, Imane Toughrai<sup>1</sup>, Khalid Mazaz<sup>1</sup>

<sup>1</sup>Department of General and Visceral Surgery, Hassan II University Hospital of Fez, Fez, Morocco

DOI: [10.36347/sasjs.2022.v08i07.004](https://doi.org/10.36347/sasjs.2022.v08i07.004)

| Received: 14.06.2022 | Accepted: 26.07.2022 | Published: 30.07.2022

\*Corresponding author: Soumeya Ettahiri

Department of General and Visceral Surgery, Hassan II University Hospital of Fez, Fez, Morocco

### Abstract

### Case Report

Adenomyomatosis (ADM) of the gallbladder (GB) is a benign disease, defined by an enlargement of the mucosal epithelium which invaginates into the interstices of a thickened muscle forming so-called Rokitansky-Aschoff sinuses. Three forms exist: segmental, fundic and more rarely diffuse. The etiopathogenesis is not yet elucidated, but chronic inflammation of the gallbladder wall seems to be involved. Prevalence of ADM in cholecystectomy specimens is estimated between 1% and 9% with a balanced sex ratio. ADM gallbladder is usually asymptomatic, however it can manifest as hepatic colic, even in the absence of associated gallstones. The preoperative diagnosis is mainly based on ultrasound (US) which identifies intra-parietal pseudo-cystic images and "comet tail" artifacts. MRI with MRI cholangiography sequences is the reference examination with characteristic "string of pearls" images. If the clinical picture is symptomatic or in case of tumor suspicion, cholecystectomy is then justified the discovery of ADM on a cholecystectomy specimen does not require special monitoring.

**Keywords:** Adenomyomatosis (ADM), gallbladder, benign disease, string of pearls.

Copyright © 2022 The Author(s): This is an open-access article distributed under the terms of the Creative Commons Attribution 4.0 International License (CC BY-NC 4.0) which permits unrestricted use, distribution, and reproduction in any medium for non-commercial use provided the original author and source are credited.

## CASE REPORT

We report a case of a 54 years old patient with no history of surgery; he was symptomatic and reported a hepatic colic. The abdominal CT-scan revealed focal mural thickening of the gallbladder wall. A liver MRI showed an intramural cystic formation in the vesicular fundus. Laparoscopic cholecystectomy was performed. Histological examination confirmed the diagnosis of GA.

## DISCUSSION

Gallbladder (GB) adenomyomatosis (ADM) is a benign, acquired anomaly, characterized by hypertrophy of the mucosal epithelium that invaginates into the interstices of a thickened muscularis forming so-called Rokitansky-Aschoff sinuses [1]. There are three forms of ADM: segmental, fundal and more rarely, diffuse.

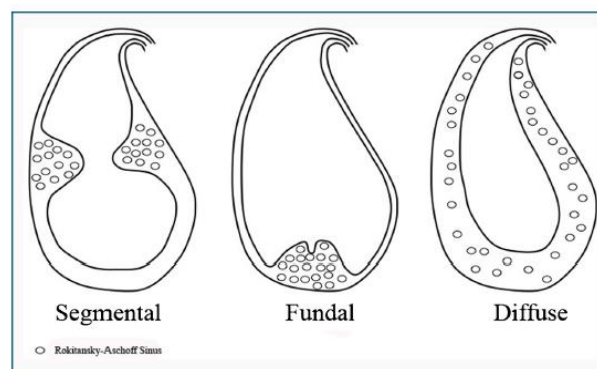


Figure 1: Diagram of the different macroscopic forms of adenomyomatosis

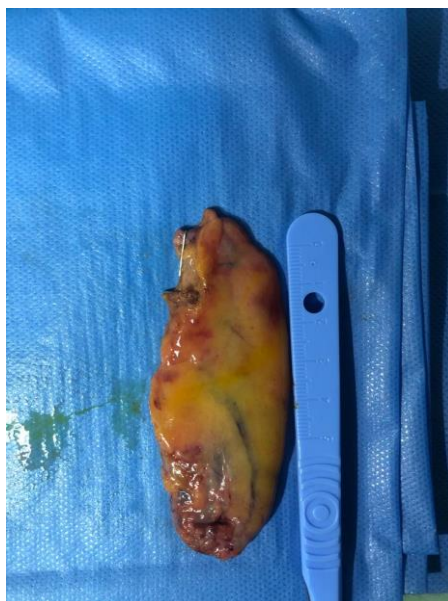
Etiology and pathogenesis are not well understood but chronic inflammation of the GB is a necessary precursor. Prevalence of ADM in cholecystectomy specimens is estimated between 1%

and 9% with a balanced sex ratio; the incidence increases after the age of 50 [2].

ADM, can be asymptomatic, or manifest as abdominal pain or hepatic colic, even in the absence of associated gallstones (50% to 90% of cases). It can also be revealed by an attack of acalculous cholecystitis.

Pre-operative diagnosis is based mainly on ultrasound (US), which identifies intra-parietal pseudocystic images and “comet tail” artifacts. MRI with MRI cholangiography sequences is the reference examination with characteristic “pearl necklace” images.

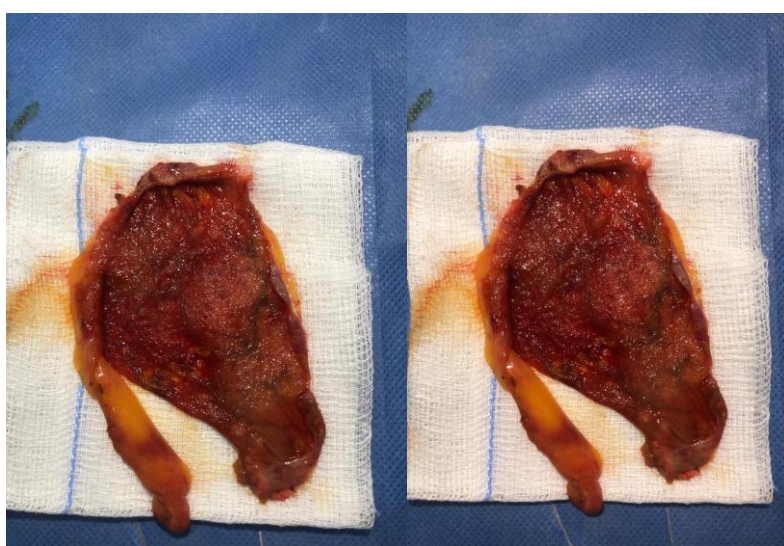
Symptomatic ADM is an indication for cholecystectomy, which results in complete disappearance of symptoms. Asymptomatic ADM is not an indication for surgery, but the radiological diagnosis must be beyond any doubt. If there is any diagnostic doubt about the possibility of GB cancer, a cholecystectomy is justified. The discovery of ADM in a cholecystectomy specimen does not require special surveillance.



## PATHOLOGICAL FINDINGS

There are three macroscopic forms of ADM: The segmental form (> 60%), located between the GB neck and fundus, which constitutes a true cholecystic diaphragm that separates the GB into two

communicating zones; the fundal form (30%) which is limited to the GB fundus with a dimple overlying an area of fundal wall thickening, the rare diffuse form (<5%), which corresponds to parietal thickening involving the entire GB wall [3].



## CLINICAL PRESENTATION

ADM is usually or pauci-symptomatic. Rarely, ADM can manifest itself as authentic biliary colic-type

pains in the right hypochondrium [4]. These pains, which have also been reported in patients without lithiasis, usually last from a few minutes to few hours

and resolve spontaneously. Often patients report non-specific digestive disorders (fatty food intolerance, flatulence, nausea, vomiting) that become progressively more frequent [5, 6]. It is not uncommon for patients to describe pain of many years duration before the connection with ADM is evoked. In these cases of nonspecific symptomatology, ADM remains a diagnosis of exclusion since no specific sign can implicate ADM [10].

ADM can also be revealed by a first attack of acalculous cholecystitis.

CT scan has a sensitivity of 50–75% for the diagnosis of ADM. It typically shows a thickened wall with a pseudo-cystic aspect and intramural calcifications.

However, this examination does not perform well to differentiate ADM from GB cancer, in contrast

to MRI, which is now the gold standard modality ADM [11]. Indeed, MRI and cholangio-MRI sequences make it possible to precisely locate ADM by visualizing intramural cystic images (hyper-T2) in “pearl necklace” configuration [8]. These images are pathognomonic of ADM. Thus, cholangio-MRI sequences are very useful for the differential diagnosis of cancer, with sensitivity greater than 80% [7, 9]. Other signs should have been sought, including enhancement in the arterial phase. Classically, ADM has no parietal contrast enhancement unlike GB carcinoma, but this is not very discriminating. Finally, with ADM, there is no evidence of peri-cholecystic infiltration or invasion of adjacent organs [12]. If there is focal thickening of the GB wall without calcified or cystic elements, radiologic imaging is less useful. Here, MRI cannot discriminate between GB cancer and ADM.

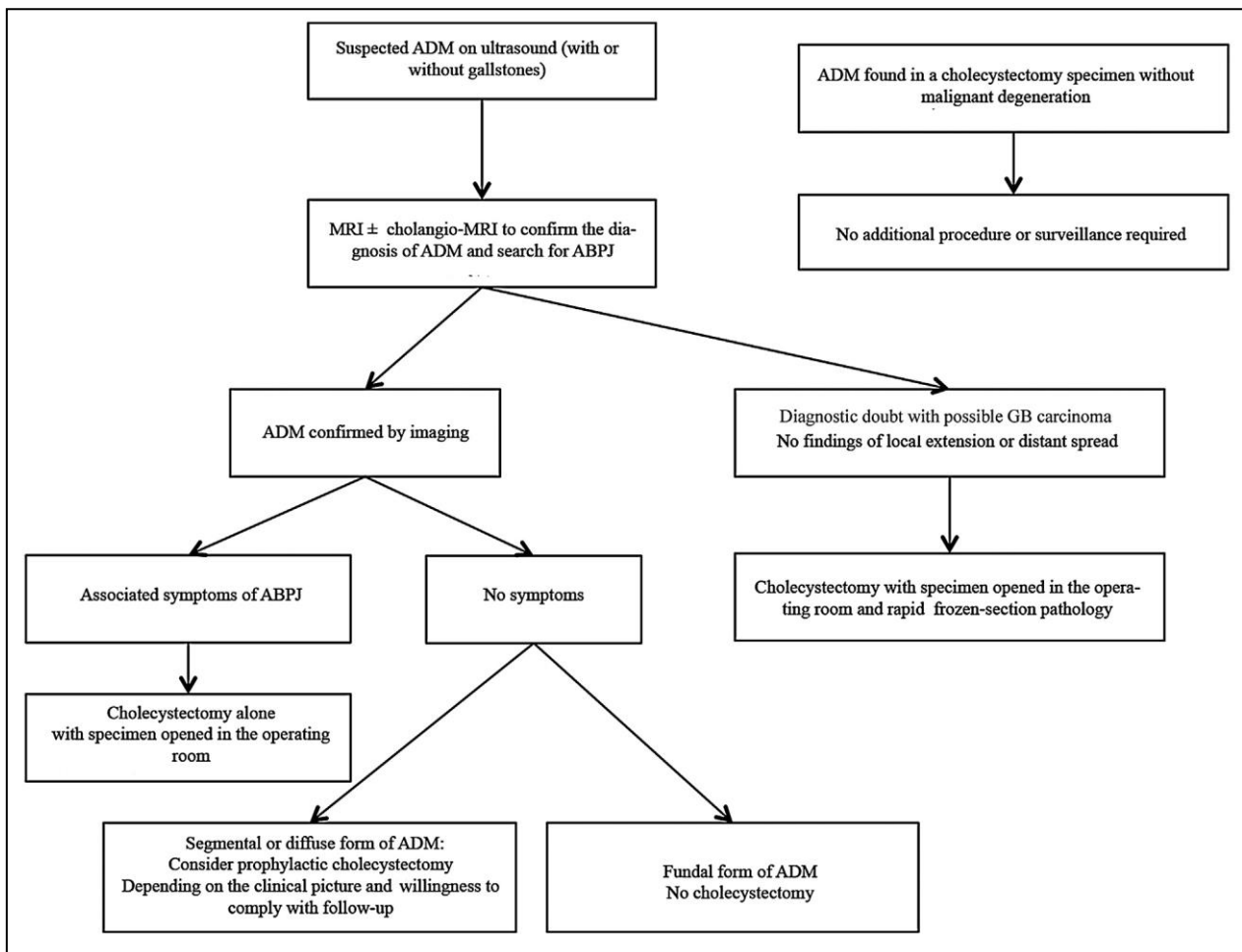


Figure 2: Algorithm for management of ADM

## CONCLUSION

ADM is a benign entity, generally discovered fortuitously by imaging or after cholecystectomy. The pathological diagnosis is based on the presence of a thickened wall with RAS.

The radiological examination of certainty is the cholangio-MRI; in fact it specifies the seat of the ADM and rules out the differential diagnosis, which is gallbladder cancer.

ADM theoretically does not require any specific treatment. Some authors speak of an association between ADM and cancer but preventive cholecystectomy is not recommended.

## REFERENCES

1. JA, J. (1960). Hyperplastic cholecystoses; Hickey lecture, 1960. *The American Journal of Roentgenology, Radium Therapy, and Nuclear Medicine*, 83, 795-827.
2. Ootani, T., Shirai, Y., Tsukada, K., & Muto, T. (1992). Relationship between gallbladder carcinoma and the segmental type of adenomyomatosis of the gallbladder. *Cancer*, 69(11), 2647-2652.
3. Nishimura, A., Shirai, Y., & Hatakeyama, K. (2004). Segmental adenomyomatosis of the gallbladder predisposes to cholecystolithiasis. *Journal of hepato-biliary-pancreatic surgery*, 11(5), 342-347.
4. Terada, T. (2008). Gallbladder adenocarcinoma arising in Rokitansky–Aschoff sinus. *Pathology international*, 58(12), 806-809.
5. Stokes, M. C., Burnette, R., Ballard, B., Ross, C., & Beech, D. J. (2007). Adenomatous hyperplasia of the gallbladder. *Journal of the National Medical Association*, 99(8), 959-961.
6. Meguid, M. M., Aun, F., & Bradford, M. L. (1984). Adenomyomatosis of the gallbladder. *The American journal of surgery*, 147(2), 260-262.
7. Bang, S. H., Lee, J. Y., Woo, H., Joo, I., Lee, E. S., Han, J. K., & Choi, B. I. (2014). Differentiating between adenomyomatosis and gallbladder cancer: revisiting a comparative study of high-resolution ultrasound, multidetector CT, and MR imaging. *Korean Journal of Radiology*, 15(2), 226-234.
8. Kim, M. J., Oh, Y. T., Park, Y. N., Chung, J. B., Kim, D. J., Chung, J. J., & Mitchell, D. G. (1999). Gallbladder adenomyomatosis: findings on MRI. *Abdominal imaging*, 24(4), 410-413.
9. Haradome, H., Ichikawa, T., Sou, H., Yoshikawa, T., Nakamura, A., Araki, T., & Hachiya, J. (2003). The pearl necklace sign: an imaging sign of adenomyomatosis of the gallbladder at MR cholangiopancreatography. *Radiology*, 227(1), 80-88.
10. Bevan, G. (1970). Acalculous adenomyomatosis of the gallbladder. *Gut*, 11(12), 1029-1034.
11. Mariani, P. J., & Hsue, A. (2011). Adenomyomatosis of the gallbladder: the “good omen” comet. *The Journal of Emergency Medicine*, 40(4), 415-418.
12. Pellino, G., Sciaudone, G., Candilio, G., Perna, G., Santoriello, A., Canonico, S., & Selvaggi, F. (2013). Stepwise approach and surgery for gallbladder adenomyomatosis: a mini-review. *Hepatobiliary & Pancreatic Diseases International*, 12(2), 136-142.