

Rare Complication of a Hernia in the Linea Alba: Generalized Peritonitis Due to Perforation by a Chicken Bone Incarcerated in the Hernia

Anas Belhaj*, Mohamed Fdil, Mourad Badri, Mohammed Lazrek, Younes Hamdouni Ahmed, Zerhouni, Tarik Souiki, Imane Toughraï, Karim Ibn Majdoub Hassani, Khalid Mazaz

Visceral and Endocrinological Surgery Service II, Chu Hassan II, Fes, Morocco

DOI: [10.36347/sasjs.2020.v06i03.016](https://doi.org/10.36347/sasjs.2020.v06i03.016)

| Received: 05.03.2020 | Accepted: 13.03.2020 | Published: 23.03.2020

*Corresponding author: Anas Belhaj

Abstract

Case Report

Small intestine perforation by a foreign body is a rare cause of secondary peritonitis. We report the case of peritonitis due to an exceptional mechanism; a small perforation by incarceration of a bony flap in the small bowel due to the existence of a hernia of the white line.

Keywords: Peritonitis, white line hernia, fragment of bone, incarceration.

Copyright @ 2020: This is an open-access article distributed under the terms of the Creative Commons Attribution license which permits unrestricted use, distribution, and reproduction in any medium for non-commercial use (NonCommercial, or CC-BY-NC) provided the original author and source are credited.

INTRODUCTION

Acute peritonitis is the acute inflammation of the peritoneal serosa. It can either be generalized to the large peritoneal cavity, or localized, following a bacterial or chemical peritoneal attack. It can be primitive or secondary [1] and cause are multiple. It is a very serious pathology, linked to high morbidity and mortality levels in developing countries like ours.

Among these causes, perforation by a foreign body (coins, metallic objects, fish bones, bony shingles) which most often occurs in the ileocecal region [2]. However, a perforation of the small bowel with a bone flap following its blockage at the level of a hernia of the white line has never been reported.

CASE REPORT

An 84 years old patient, known to have been carrying a hernia of the white line for 7 years, was admitted to the emergency room in a table of general abdominal pain evolving for five days, with episodes of vomiting, and other signs.

Patient was conscious, with a temperature at 38.8 ° C, a pulse at 120 bpm, accelerated breathing rate at 22 cycles / min, and coldness of the extremities. The abdominal examination found a slight distension with generalized abdominal sensibility and the presence a hernia of the white line, which seemed to be reducible with a collar of 3 cm with on inflammatory signs. The rest of the clinical examination was otherwise normal.

The biological assessment showed a leukocytosis at 16500 element / mm³ and a CRP at 250. The abdomen x-ray returned without abnormality. We completed by an abdominal CT-scan which objectified a small distension of 4cm upstream of a zone of disparity of caliber at the level of a hernia of the white line, with a hyper-density image at the level of hernial sac (foreign body). It also showed the pneumoperitoneum at the level of the right flank associated to an intra-peritoneal effusion of medium abundance and enhancement of peritoneal sheets (figure1, 2).

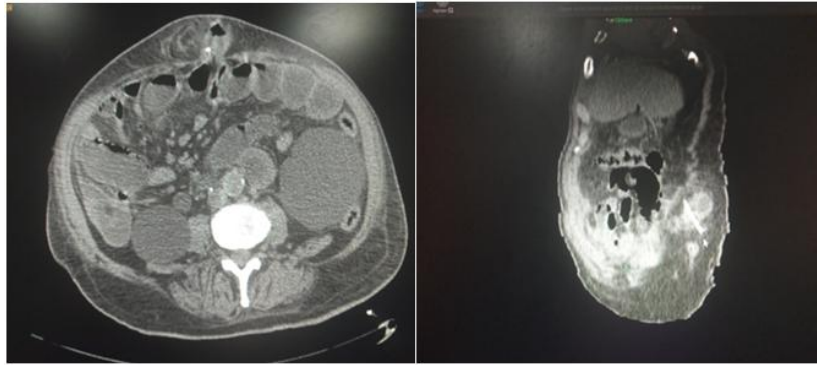


Fig-1, 2: CT-scan images that shows hernia with the pneumoperitoneum

The diagnosis of peritonitis by small intestinal perforation by a foreign body was retained. After the conditioning measures, we decided to operate the patient, and surgical exploration showed off the

presence of a white line hernia with a 4 cm collar, containing a viable small bowel loop, strangulated and perforated by a chicken bone splint of 4cm. (figures 3 and 4).

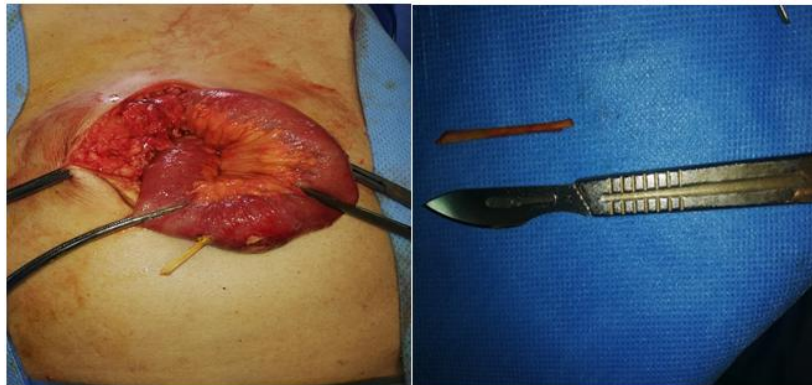

Fig-3 and 4: Showed off the presence of a white line hernia with a 4 cm collar and chicken bone splint

There was also around 1L and a half of a purulent peritoneal effusion. We started by extracting the bone splint (bone fragment of chicken), then performed an abundant peritoneal toilet, and transformed the perforation into stomy, located 1.3 m from the ileo-cecal valve and two meters from the Treitz angle. We finally put on a drainage of the peritoneal cavity. During surgery, the patient installed severe hypotension, reason why he was given on vasoactive drugs.

DISCUSSION

Acute peritonitis is a very frequent pathology; it occupies the third place of the acute surgical abdominal emergencies after appendicitis and intestinal obstruction. It remains a delicate situation with a high mortality rate when treatment is delayed [4], like the case of our patient.

In addition, acute peritonitis is most often due to digestive tract origin, (like appendicitis, gastro-duodenal ulcer perforation, sigmoiditis or strangulated hernia) or biliary origin (cholecystitis). The clinical table is made of à peritoneal syndrom: severe abdominal pain, (initially localized then quickly generalized) sometimes "stabbing".

And vomiting with modification in bowel (sub-occlusion). The general signs are immediately important: very high fever, tachycardia, dyspnea, oliguria. In the extreme cases, there may be a septic shock with multi-visceral failure (elderly or immunocompromised patients). On examination, the pathognomonic abdominal sign is spontaneous, permanent, painful, invincible contracture of the abdominal wall, sometimes very discreet, even absent in the elderly. Biologically, an inflammatory syndrome is always obvious [3].

Peritonitis is an emergency requiring therapeutic medical and surgical management. The medical treatment is based on conditioning, in case of alteration of the major vital functions, with good vascular filling, in addition to antibiotics adapted to the digestive flora. Surgical treatment has several objectives: treatment of the responsible organ, excision (appendix, gall bladder, sigmoid) or repair (stomach, duodenum, small intestine), with a large peritoneal lavage until obtaining a clean cavity, stomies temporary if small bowel, colic or rectal lesions [4]. The prognosis essentially depends on the patient's age, general condition, delayed diagnosis and the nature of the lesions.

Our case is particular, because only a few cases of peritonitis by small intestinal perforation by foreign body have been reported in the literature. The ingestion of foreign body occurs in particular in children, elderly subject (problem of dentition), sometimes in psychiatric patients, or in case of bad eating habits (too fast meal, cough ...).

The foreign body can perforate the digestive tract and cause peritonitis [6], or obstruct the digestive lumen leading to occlusion [7], or other less common miscellaneous complications (digestive hemorrhage).

CONCLUSION

Secondary acute peritonitis is a very common condition, of multiple causes, among them there is a rare cause, which is small intestinal perforation by a foreign body. The diagnosis must be rapid because it can quickly lead to death. Incarceration of a foreign body in the small intestinal lumen due to the existence of a hernia of the white line can lead to a perforation and consequently a peritonitis.

REFERENCES

1. Aubert F, Guittard L'essentiel médical de poche 2ème éd. Paris: EDITION marketing/ ellipse; 1995.
2. Dray X, Cattan P. Foreign bodies and caustic lesions. *Best Pract Res Clin Gastroenterol.* 2013; 27:679–89.
3. Abrege D'hepato-Gastro-Enterologie Et De Chirurgie Digestive 3ème édition - Partie « Connaissances » - © par la CDU-HGE - Editions Elsevier-Masson - Septembre 2015, Chapitre 34 - Item 352 -UE 11
4. Montravers, Allyn J, Olinca A. Prise en charge des péritonites *Journal des Anti-infectieux.* 2011; 13(1) : 25-33
5. Pronostic des peritonites G. Troché, *Médecine et Maladies Infectieuses.* 1995;25(5): 20-37.
6. Panafrique medical journal, Images in medicine Péritonite par perforation grêlique secondaire à une arête de poisson Karim Ibn Majdoub Hassani, Imane Toughrai.
7. Panafrique medical journal, Images in medicine Une occlusion intestinale aiguë par un os de poulet, Ammar Mahmoudi, Mabrouk Abdelali.