

Research Article

Histopathology of Appendectomy Specimen: A 5 Year Study

Shaveta Sharma, Deepti Mahajan, Mohsin-ul-Rasool*, Shazia Bashir, Ather Hafiz, Mir Wajahat

Department of pathology, SKIMS, Srinagar, J & K, India

***Corresponding author**

Dr. Mohsin-ul-Rasool

Email: drmohsinrasool@gmail.com

Abstract: A 5 year study was performed to determine the patterns of lesions (non-neoplastic and neoplastic), to study their detailed morphological features and to correlate the clinical diagnosis with the histopathological diagnosis of the appendectomy specimens. Histopathological records of resected appendices were reviewed over a period of 5 years. In each case, a brief clinical history and physical examination along with the evaluation of available relevant investigations was carried out. Out of 440 appendectomy specimens, 98.6% were found to be involved by non-neoplastic lesions and 1.4% was found to be involved by neoplastic lesions. Histopathological diagnosis of acute appendicitis was made in 64% of clinically diagnosed acute appendicitis cases. In rest of the cases; diagnosis other than acute appendicitis was made. In 5.7% cases, no significant abnormality was seen histopathologically and these were labeled as normal appendices thus accounting for negative appendectomy rate of 5.7%. The present study provides a fair insight into the histological patterns of lesions in appendectomy specimens.

Keywords: Appendicitis, non-neoplastic, neoplastic, appendectomy, histopathological diagnosis

INTRODUCTION

Appendicitis is a very common surgical emergency and has a lifetime risk of 7%. It is approximately 1.4 times greater in men than in women [1]. Misdiagnosis and delay in surgery can lead to complications like perforation and finally peritonitis. Therefore certain scoring systems like Alvarado Scoring System are established which aid in the diagnosis of acute appendicitis, provides high degree of positive predictive value and thus diagnostic accuracy [2]. Appendiceal tumors are unusual accounting for 0.4% of all gastrointestinal tract malignancies. An estimated 1% of all appendectomy specimens contain a neoplasm. The majority of appendicular tumors are carcinoids while the remaining 10-20% is mucinous cyst adenocarcinoma, adenocarcinoma, lymphomas, paraganglioma and granular cell tumor [3]. Not only has the pathologic diagnosis of acute inflammation, at times unusual findings such as incidental tumors highlighted the importance of pathologic analyses of every single resected appendix.

Aims and Objectives

- To study the patterns of lesions (non-neoplastic and neoplastic) in the appendectomy specimens.
- To study the detailed morphological features of the different non-neoplastic and neoplastic lesions i.e. both benign and malignant.

- To correlate the clinical diagnosis with the histopathological diagnosis of the appendectomy specimens.

MATERIALS AND METHODS

The present study was conducted in the Post Graduate Department of Pathology, Government Medical College, Jammu. Histopathological records of resected appendices were reviewed retrospectively over a period of 4 years from December 2005 to November 2009 and prospectively over a period of one year from December 2009 to November 2010. In each case, a brief clinical history and physical examination along with the evaluation of available relevant investigations was carried out. The specimens were fixed in 10% buffered formalin. A detailed gross examination of the appendectomy specimens was carried out. Sections were taken for histology. Following the grossing of the specimens, tissue processing was done in an automatic tissue processor. Staining was done using Hematoxylin and Eosin staining procedure⁴. Special staining procedures like PAS (Periodic Acid Schiff), Toluidine Blue was carried out wherever required.

RESULTS

A total of 440 cases were studied. Maximum number of cases i.e. 68.2% were of emergency appendectomy followed by interval appendectomy comprising of 31.8%. The most common position in which appendix seen intraoperative was retrocaecal

(56.8%) and the least common was pelvic position (1.8%).Maximum number of appendectomies were performed in young patients. The youngest patient was seven years old and the oldest was sixty-five years of age. Overall, a greater number of appendectomies (68.2%) were performed in males than in females (31.8%).Many patients presented with multiple and overlapping clinical symptoms. The most common symptom was right iliac fossa pain seen in 310 patients (70.5%), followed by generalized pain abdomen, 55(12.5%) and fever, 45(10.2%). Intestinal obstruction was seen in only 2(0.5%) patients. The most common lesion seen in males was acute appendicitis seen in 188(42.7%) cases whereas the most common lesion seen in females was acute appendicitis with periappendicitis seen in 75(17.04%) cases.Grossly, mucosal congestion was the most common finding seen in 203(46.14%) cases. The neoplasms identified in appendectomy specimens were carcinoids, mucinous cystadenoma and mucinous cystadenocarcinoma. Four cases of carcinoid tumors were seen. Most of the patients were young in the age group of 20-30years (table 1). One case of mucinous cystadenoma was seen. The patient was male about 60years of age. One case of mucinous cystadenocarcinoma was seen. The patient was female of 47 years of age. In the present study, the

most common clinical diagnosis for which appendectomy was done was acute appendicitis. A total of 300 cases were received with this diagnosis. On histopathological analyses, 192 cases (64%) were diagnosed as acute appendicitis (fig. 1), 47 (15.6%) were diagnosed as acute appendicitis with periappendicitis, 24(8%) were diagnosed as early acute appendicitis, 2 (0.6%) each were diagnosed as Mucocele and endometriosis, 3(1%) were diagnosed as chronic fibrosing appendicitis, 4(1.3%) were diagnosed as carcinoids (fig. 2) and 1 (0.3%) was diagnosed as mucinous cystadenoma. Twenty-five cases (8.3%) were diagnosed as normal appendices (table 1). Fifty-six cases presenting clinically as appendicular lump were received. Of these, thirty-eight were found to have early acute appendicitis histopathologically. Ten specimens were found to have acute appendicitis and were diagnosed as chronic fibrosing appendicitis. Eighty-two cases of perforation peritonitis were received. A diagnosis of acute appendicitis with periappendicitis was made in 81 cases (98.7%) and one case (1.2%) was diagnosed as acute appendicitis (table 2). Two cases of intestinal obstruction were received. One case was diagnosed as acute appendicitis (50%) and one was diagnosed as mucinous cystadenocarcinoma.

Table 1: Age-wise distribution of various lesions encountered in appendectomy specimens

Lesions	Age Groups (years)			
	0-20	21-40	41-60	61-70
Early Acute Appendicitis	28	27	5	2
Acute appendicitis	64	115	20	5
Acute appendicitis with periappendicitis	70	40	14	4
Chronic fibrosing appendicitis	3	4	3	1
Mucocele		2		
Carcinoid tumor	2	2		
Mucinous cystadenoma			1	
Mucinous cystadenocarcinoma			1	
Endometriosis		2		
Normal appendix	13	7	5	
Total	180	199	49	12

Table 2: Distribution of the appendectomy specimens as per their nature

Specimen	No. of cases (n=440)	Percentage (%)
Non-neoplastic lesions	434	98.64
Neoplastic lesions	6	1.36

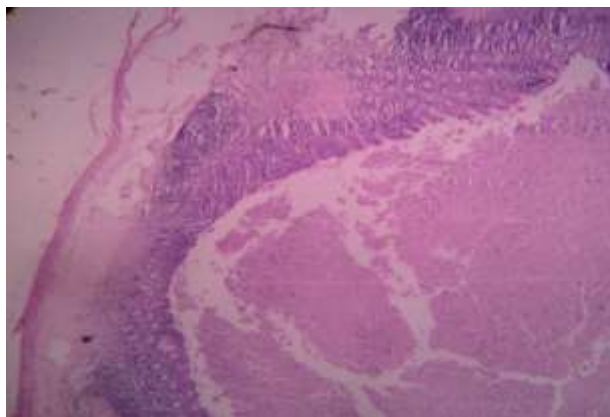


Fig. 1: Microphotograph of appendix shows dilated lumen filled with vegetative matter and acute inflammatory infiltrate within the wall (H&E 10x)

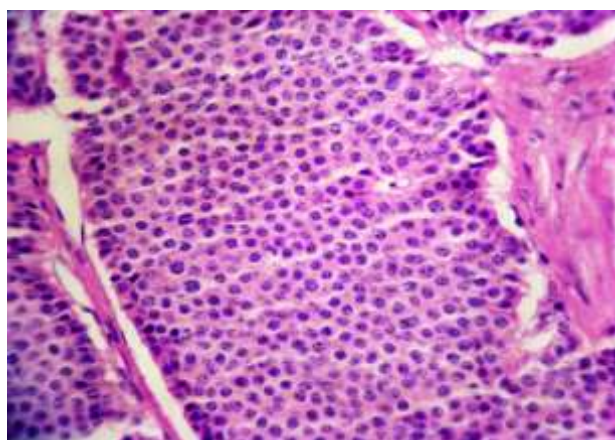


Fig. 2: Microphotograph of carcinoid tumor with cell showing salt & pepper chromatin (H&E-40x)

DISCUSSION

The current study is a five year study comprising of four year retrospective and one year prospective period and presents the data on histopathological analyses of 440 appendectomy specimens received in the Department of Pathology, Government Medical College, Jammu. The histopathological examination of the appendix serves two purposes. First it allows the diagnosis of acute appendicitis to be confirmed; second, histopathological examination may disclose additional pathologies that may not be evident intraoperatively which may impact patient management. In the present study, emergency appendectomy was the preferred approach in maximum number of cases (68.2%), followed by interval appendectomy (31.8%). Deakin and Ahmed⁵ have also reported that emergency appendectomy was the management of choice in most cases. Appendices were found to be mostly retrocaecal in position during operation observed in (56.8%) of cases. Pelvic position was the least common position observed in only 1.8% cases. In contrast to the present study, Golalipour *et al.* [6] and Ahmed *et al.* [7] reported pelvic position to be the most predominant position seen in 33.3% and 51.2% cases, respectively. Maximum number of patients (30.2%) who underwent appendectomy were in the age group of 21-30

years. Marudanayagam *et al.* [8] also reported that most of the appendectomies (64.58%) were performed in the second decade of life. A greater percentage of appendectomies (68.2%) were performed in males as compared to females (31.8%). These findings are in concordance with those of Nabipour [9] and Makaju *et al.* [10]. In the present study of 440 appendectomy specimens, 434 (98.6%) were found to be involved by non-neoplastic lesions and only 6 (1.4%) cases were involved by neoplastic lesions. Blair *et al.* [11] in their retrospective study also reported that 80% of appendectomy cases were found to be involved by non-neoplastic (inflammatory) lesions. Neoplasms were seen in 4% of cases. In rest (16%) of appendices, normal histology was seen. Both neoplastic and non-neoplastic lesions were observed to be more common in males as compared to females. Zulfikar *et al.* [12] in their retrospective study recorded 323 cases of appendectomy. Of these, 196 (60.7%) were males and 127 (39.3%) were females. The most common presenting symptom with which the patients sought hospital admission was right iliac fossa pain followed by generalized abdominal pain. Edino *et al.* [13] in their study also concluded that abdominal pain was the most common presenting symptom of the patients. Mucosal congestion was the most common abnormal finding seen grossly (46.4%), followed by fecolith presence in

the appendiceal lumen (13.5%). Majid *et al.* [14] studied 250 appendectomy cases and reported that mucosal congestion was the commonest finding seen in 218(87.2%) cases. Acute appendicitis constituted the most common histopathological lesion for which appendectomy was done and was seen in 46.36% of cases. These findings are in agreement with those of Chang [15], Blair *et al.* [11] and Edino *et al.* [13]. Acute appendicitis with periappendicitis constituted the second most common lesion (29.1%) for which appendectomy was done. In contrast Mukherjee *et al.* [16] detected only 7.8% of acute appendicitis with periappendicitis histopathologically. Early acute appendicitis constituted the third most common lesion seen in 13.86% cases. Nabipour [9] also reported that early acute appendicitis is not an uncommon finding and reported 9.2% of such cases in his study. Chronic fibrosing appendicitis was seen in 2.5% of cases in the present study. In contrast Edino *et al.* [13] in their study reported 17% cases of chronic fibrosing appendicitis. In the present study, diagnosis of Mucocele was made in just 2 (0.4%) of cases. Papaziogas *et al.* [17] also made such an observation in their study spanning over 20 years. Diagnosis of endometriosis was made in just 2 (0.4%) cases in the present study. Gustofson *et al.* [18] studied 133 female patients and found endometriosis to be present in 4 (3%) cases. Only a single case of mucinous cystadenoma was diagnosed in the present study accounting for 0.2% of the total cases. Similarly, Marudanayagam *et al.* [8] in their retrospective analysis of 2660 cases reported mucinous cystadenoma to be present in 0.6% of the cases. A diagnosis of carcinoid tumor was made in 4 (1.1%) cases. Similarly, of *et al.* [19] found carcinoid in only 7(0.47%) cases. Mucinous cystadenocarcinoma of the appendix was the only malignant lesion encountered in the present study seen in a single case of 45 years old female thus confirming the view that appendix is mostly involved by benign conditions. Similarly, Jones and Paterson [20] reported that primary malignant tumors of the appendix i.e. cystadenocarcinoma were found in only 0.1% of all appendectomies. In the present study, histopathological diagnosis of acute appendicitis was made in 64% of clinically diagnosed acute appendicitis cases. In rest of the cases, diagnosis other than acute appendicitis was made and in 25 (5.7%) cases, no significant abnormality was seen histopathologically and these were labeled as normal appendices, thus accounting for negative appendectomy rate of 5.7%. Negative appendectomy rate was higher in females, especially of reproductive age group(4.5%) as compared to males (1.13%). Such difference was attributed to conditions like ovarian and tubal pathologies that mimic features of acute appendicitis clinically. Connor *et al.* [21] in their retrospective study of 7970 cases showed a discrepancy between the surgeon's opinion of the macroscopic appearance of the appendix and the pathologist's opinion in 14.5% of their cases and most of these were neoplastic conditions. Similarly, Joshi and Manandhar [22] in their clinico-pathological co-relation found

discrepancy in 14% of cases and in 86% of cases a histopathological diagnosis of acute appendicitis was made in clinically diagnosed acute appendicitis cases. Therefore in contrast to present study, higher negative appendectomy rates were reported in other studies but like present study, most of the negative appendectomies were performed in females of reproductive age group. Thus, the current study spanned the entire gamut of pathological processes that involve the appendix and provides a fair idea about the clinic pathological correlation in appendectomy specimens.

REFERENCES

1. Craig S. Appendicitis acute. *Acta Paediatr.*, 2001; 90(6):649-651.
2. Khan I, Rehman AU; Application of Alvarado scoring system in diagnosis of acute appendicitis. *J Ayub Med Coll Abbottabad.*, 2005; 17(3): 41-44.
3. Mahteme H, Sugarbaker PH; *Br J Surg.*, 2004; 91(9):1168-1173.
4. Wilson I, Gamble M; The Hematoxylin and eosins: In Bancroft JD, Gamble M editors; *Theory and Practice of Histological Techniques*, 5th edition, Churchill Livingstone 2002: 325-344.
5. Deakin DE, Ahmed I; Is interval appendectomy after resolution of adult inflammatory appendix mass necessary? *Surgeon*, 2007; 5(1):45-50.
6. Golalipour MJ, Arya B, Azarhoosh R, Jahanshahi M; Anatomical variations of vermiform appendix in South East Caspian sea. *J Anat Soc India*, 2003;52(2):141-143.
7. Ahmed I, Asgeirsson KS, Beckingham IJ Lobo DN; The position of the vermiform appendix at laparoscopy. *Surg Radiol Anat.*, 2003; 29(2):165-168.
8. Marudanayagam R, Williams GT, Rees BI; Review of the pathological results of 2660 appendectomy specimens *Gastro.*, 2006; 41(8):745-749.
9. Nabipour F; Histopathological feature of acute appendicitis in Kerman, Iran from 1997 to 2003. *Am J Environ Sci.*, 2005; 1(2):130-132.
10. Makaju R, Mohammed A, Shakyl A; Acute Appendicitis: Analyses of 518 histopathologically diagnosis cases in the Kathmandu University Hospital, Nepal. *Kathmandu Univ Med J.*, 2010; 8(2):227-230.
11. Blair NP, Bugis SP, Turner LJ, MacLeod MM; Review of pathological diagnosis of 2216 appendectomy specimens. *Am J Surg.*, 1993; 165(5):618-620.
12. Zulfikar I, Khanzada TW, Sushel C, Samad A; Review of the pathologic diagnoses of appendectomy specimens. *Annals of King Edward Medical University*, 2009; 15(4):168-170.

13. Edino ST, Mohammed AZ, Ochicha O, Anumah M; Appendicitis in Kano, Nigeria: A 5 year review of pattern, morbidity and mortality. *Annals of African Medicine*, 2004; 3(1): 38-41.
14. Majid S, Imran AA Khan SA; Morphological variations in appendectomy specimens. *Pak J Pathol.*, 2005; 16(2): 58-60.
15. Chang AR; An analysis of the pathology of 3003 appendices. *Aust N Z J Surg.*, 1981; 51(2):169-178.
16. Mukherjee A, Schlenker E, LaMasters T, Johnson M, Brunz J, Thomas E; Periappendicitis: Is it a clinical entity? *Am Surg.*, 2002; 68(10): 913-916.
17. Papaziogas B, Koutelidakis I, Tsiaousis P, Goula OC, Lakis S, Atmatzidis S *et al.*; Appendiceal mucocele. A retrospective analysis of 19 cases *Gastrointest. Cancer*, 2007; 38(2):141-147.
18. Gustofson RL, Kim N, Liu S, Stratton P; Endometriosis and in appendix-a case series and comprehensive review of the literature. *Fertility and Sterility*, 2006; 86(2):267-502.
19. In't Hof KH, van der Wal HC, Kazemier G, Lange JF; Carcinoid tumor of the appendix. Analyses of 1485 consecutive emergency appendectomies. *J Gastrointest Surg* 2008; 12(8):1436-1438.
20. Jones MW and Paterson AG; The correlation between gross appearance of the appendix at appendectomy and histopathological examination. *Ann R Coll Surg Engl.*, 1988; 70(2):93-94.
21. Connor SJ, Hanne GB, Frizelle FA; Appendiceal tumors. Retrospective clinicopathologic analyses of appendiceal tumors from 7970 appendectomies. *Diseases of the Colon and Rectum*, 1998; 41(1):75-80.
22. Joshi BR, Manandhar K; Clinical correlation of acute appendicitis with histopathological diagnosis: A prospective study. *PMJN* 2009 ;(8) 55-59.