

## Verrucous Carcinoma of the Wrist: A Case Report

Agouzzal Ahmed Anis<sup>1\*</sup>, M. Darfaoui<sup>1</sup>, F. E. Ballouk<sup>1</sup>, N. Kadri<sup>1</sup>, M. Bennani<sup>1</sup>, B. Mahrouch<sup>1</sup>, A. Sabiq<sup>1</sup>, I. Zaytoun<sup>1</sup>, S. Kandry Rody<sup>1</sup>, A. El Omrani<sup>1</sup>, M. Khouchani<sup>1</sup>

<sup>1</sup>Radiation Oncology Department – Mohammed VI Teaching Hospital – Marrakech, Morocco

DOI: [10.36347/sjmcr.2022.v10i08.019](https://doi.org/10.36347/sjmcr.2022.v10i08.019)

| Received: 11.07.2022 | Accepted: 17.08.2022 | Published: 19.08.2022

\*Corresponding author: Agouzzal Ahmed Anis

Radiation Oncology Department – Mohammed VI Teaching Hospital – Marrakech, Morocco

### Abstract

### Case Report

A 49 years old male patient, with no particular pathological history, presented for two years with an exophytic, hyperkeratotic infiltrating lesion of the palm side of the left wrist with muscular atrophy of the hand and blockage of the wrist joint, with no palpable enlarged lymph nodes. A magnetic resonance imaging of the hand was performed, showing a loss of substance of the anterior side of the wrist and the hand associated with an infiltration of the subcutaneous soft tissues and muscles of the thenar eminence with Long palmar tendon sheathing. The patient was treated by surgery consisting on a wrist and forearm Amputation and Histological examination finally concluded to a verrucous carcinoma with clear resection margins. The evolution was favorable, with no recurrence after 13 months of follow-up.

**Keywords:** Verrucous carcinoma, Hand, Management.

Copyright © 2022 The Author(s): This is an open-access article distributed under the terms of the Creative Commons Attribution 4.0 International License (CC BY-NC 4.0) which permits unrestricted use, distribution, and reproduction in any medium for non-commercial use provided the original author and source are credited.

## INTRODUCTION

Verrucous carcinoma is a low-grade, well differentiated uncommon variant of squamous cell carcinoma [1]. It typically affects the oral cavity, larynx, genitalia, oesophagus, and rarely the skin. Skin verrucous carcinoma is a slow-growing, exophytic tumor with a broad base [2]. Ninety percent of verrucous carcinomas of the skin are located on the feet, and rarely found on the hands [3]. We report the case of a large verrucous carcinoma on a man's wrist who was treated by amputation.

## CASE REPORT

A 49 years male patient, a chronic smoker, presented a large papillomatous mass on the wrist.

History revealed that the symptoms began two years earlier after a minor trauma by a small nodule that was initially localized on the left palm. He was referred for surgical management. Physical examination revealed a focal ulcerated keratotic papillomatous epidermal proliferation that was about 3 cm × 2 cm in size. After a radiological examination that confirmed that the lesion was restrained in the skin, the patient underwent surgical excision of the whole lesion with 10 mm margins.

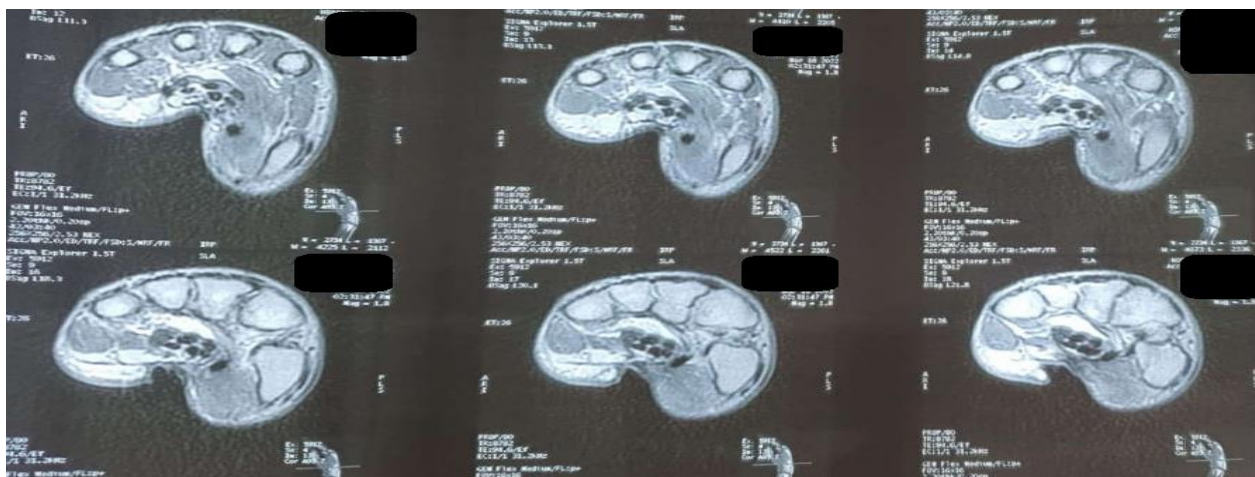
Two years later, similar lesions grew along the wrist. The clinical examination revealed a hard infiltrating hyperkeratotic lesion of the palm side of the left wrist with muscular atrophy of the hand and blockage of the wrist joint (figure 1). A full-body skin examination was otherwise unremarkable. There was no lymphadenopathy.

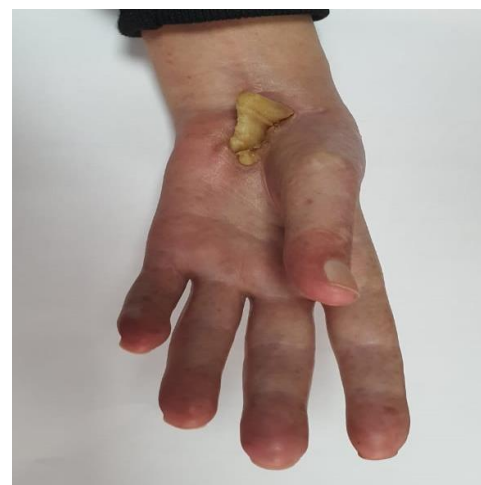

Figure 1: Hyperkeratotic lesion measuring 5 cm long with a wide non-ulcerated base

For locoregional staging of the mass, a magnetic resonance imaging of the hand (MRI) was performed, showing a loss of substance of the anterior side of the wrist and the hand associated with an

infiltration of the subcutaneous soft tissues and muscles of the thenar eminence with Long palmar tendon sheathing (figure 2). A CT scan of the chest, abdomen, and pelvis revealed no evidence of metastasis.



**Figure 2:** loss of substance of the anterior side of the wrist and the hand associated with an infiltration of the subcutaneous soft tissues and muscles of the thenar eminence

The patient was treated by surgery consisting on a wrist and forearm amputation and Histological examination finally concluded to a verrucous carcinoma with clear resection margins.

## DISCUSSION

Verrucous carcinoma is an uncommon, slow-growing, well-differentiated, low-grade epidermal carcinoma. The term verrucous carcinoma includes different nosological entities. Ackerman initially discussed it in the oral cavity in 1948 [2]. Classically, verrucous carcinoma is described as a rare tumor. Almost all the cases described in the literature are in men in their sixties. In addition to the feet, verrucous carcinoma has also been reported on the hands, fingers, buttocks, penis, knees, and mucous membranes (oral and nasal cavity, larynx, pharynx, and esophagus) [4, 5].

The etiological factor of verrucous carcinoma is not known but can develop in areas of chronic inflammation. HPV has been identified as a promoting factor, especially HPV 11 and 16 in plantar lesions. In our patient, HPV testing was not performed [6, 7]. The lesion seems to have developed after a minor injury, not appearing to be a causal lesion.

The tumor characterized clinically by an exophytic verruciform appearance and may become ulcerated [8]. CV has a predominantly local invasion [9] and a painful course with progressive and regular increase in size, budding, invasion of subcutaneous tissue and functional impotence. subcutaneous tissues and functional impotence. In the literature, bone involvement is described in about 10% of cases and metastatic lymph node involvement in 4-5% of cases

[10-12]. To assess local and systemic spread, however, diagnostic imaging tools are required, as our case demonstrates.

Histologically, the diagnosis can be difficult because of the misleading benign aspect of the tumour with very few cellular and nuclear atypia and low mitotic activity [13]. It can be challenging to identify the invasive proliferation that can be restrained in a small portion of the samples and repeated biopsies may be required to establish the diagnosis.

Surgery is the first-line treatment .The optimum treatment method is total surgical excision. Local excision is possible, but exposes to the risk of recurrences [14]. Therefore, it seems preferable to propose limb amputation especially if the tumor is extensive and if the general condition permits. Adequate functional and cosmetic outcomes should be present in addition to complete tumor excision. Amputation should therefore be considered not only in instances of bone invasion but also when tumor size prevents normal function of the remnant of the affected area. Other techniques have been proposed without having shown their their effectiveness (electrodessiccation, curettage, vitamin C, etc.) high dose, topical fluorouracil, intra-arterial injections of bleomycin , intralesional interferon, cryotherapy, laser) [9, 15, 16]. Lymphadenectomy should only be carried out in suspected situations due to the low prevalence of lymph node metastases [17, 18].

Radiation radiotherapy is contraindicated or not recommended because of the risk of anaplastic transformation [19, 20, 21]. This side effect has been described in patients with oral and nasal cavity verrucous carcinoma but not in patients with cutaneous

verrucous carcinoma of the hand. Immunotherapy with ipilimumab or anti-PD-1 antibodies like nivolumab and pembrolizumab may be employed [2].

## CONCLUSION

Skin verrucous carcinoma is a less common form of squamous cell carcinoma with a better prognosis. The preferred treatment is extensive local excision. Although radiotherapy was described, it was ineffective. Prospective randomized trials are needed to establish the indications of each treatment modality.

## BIBLIOGRAPHY

- Ridge, J. A., Glisson, B. S., Lango, M. N., & Feigenberg, S. (2008). Head and neck tumours. In: Pazzur R, Wagman LD, Camphausen KA, Hoskins WJ, editors. *Cancer Management: A Multidisciplinary Approach*. 11<sup>th</sup> ed. London: W.B. Saunders.
- Ackerman, L. V. (1948). Verrucous carcinoma of the oral cavity. *Surgery*, 23(4), 670-678.
- Gertler, R., & Werber, K. D. (2009). Management of verrucous carcinoma of the hand: a case report. *International journal of dermatology*, 48(11), 1233-1235.
- Maciburko, S. J., Townley, W. A., Hollowood, K., & Giele, H. P. (2012). Skin cancers of the hand: a series of 541 malignancies. *Plastic and reconstructive surgery*, 129(6), 1329-1336.
- Schiavon, M., Mazzoleni, F., Chiarelli, A., & Matano, P. (1988). Squamous cell carcinoma of the hand: fifty-five case reports. *The Journal of hand surgery*, 13(3), 401-404.
- Schwartz, R. A. (1995). Verrucous carcinoma of the skin and mucosa. *J Am Acad Dermatol*, 32, 1-21.
- Gayraud, L., Canillot, S., Balme, B., Rivoalan, F., & Perrot, H. (1991). Epithélium cuniculatum sur ulcération chronique du pied. *Les Nouvelles dermatologiques*, 10(2), 211-213.
- Faure, M., Hermier, C., & Thivolet, J. (1980). Épithélioma cuniculatum. *Ann Dermatol Venereol*, 107, 183-187.
- Wastiaux, H., & Dreno, B. (2008). Recurrent cuniculatum squamous cell carcinoma of the fingers and virus. *Journal of the European Academy of Dermatology and Venereology: JEADV*, 22(5), 627-628.
- Ho, J., Diven, D. G., Butler, P. J., & Tyring, S. K. (2000). An ulcerating verrucous plaque on the foot. *Archives of dermatology*, 136(4), 547-552.
- Martin, F., Dalac, S., & Lambert, D. (1995). Le carcinome verruqueux: situation nosologique, à propos de quatre cas. In *Annales de dermatologie et de vénéréologie* (Vol. 122, No. 6-7, pp. 399-403).
- Gayraud, L., Canillot, S., Balme, B., Rivoalan, F., & Perrot, H. (1991). Epithélium cuniculatum sur ulcération chronique du pied. *Les Nouvelles dermatologiques*, 10(2), 211-213.
- Brown, S. M., & Freeman, R. G. (1976). Epithelioma cuniculatum. *Arch Dermatol*, 112, 1295-1296.
- McKee, P. H., Wilkinson, J. D., Black, M. M., & Whimster, I. W. (1981). Carcinoma (epithelioma) cuniculatum: a clinico-pathological study of nineteen cases and review of the literature. *Histopathology*, 5(4), 425-436.
- Verret, J. L., & Avenel, N. (1986). Diagnostic case: epithelioma cuniculatum. In *Annales de dermatologie et de venereologie* (Vol. 113, No. 4, pp. 361-362).
- Aird, I., Johnson, H. D., Lennox, B., & Stansfeld, A. G. (1954). Epithelioma cuniculatum a variety of squamous carcinoma peculiar to the foot. *Journal of British Surgery*, 42(173), 245-250.
- Risse, L., Negrier, P., Dang, P. M., Bedane, C., Bernard, P., Labrousse, F., & Bonnetblanc, J. M. (1995). Treatment of Verrucous Carcinoma with Recombinant Alfa-Interferon. *Dermatology*, 190(2), 142-144.
- Kahn, J. L., Blez, P., Gasser, B., Weill-Bousson, M., Vetter, J. M., & Champy, M. (1991). Carcinoma cuniculatum. Apropos of 4 cases with orofacial involvement. *Revue de Stomatologie et de Chirurgie Maxillo-faciale*, 92(1), 27-33.
- Delahaye, J. F., Janser, J. C., Rodier, J. F., & Auge, B. (1994). Cuniculatum carcinoma. 6 cases and review of the literature. *Journal de Chirurgie*, 131(2), 73-78.
- Ichimiya, M., Yoshikawa, Y., Hamamoto, Y., & Muto, M. (2004). Verrucous carcinoma. *The Journal of Foot and Ankle Surgery: Official Publication of the American College of Foot and Ankle Surgeons*, 43(4), 271-273.
- Day, F., Kumar, M., Fenton, L., & Gedye, C. (2017). Durable response of metastatic squamous cell carcinoma of the skin to ipilimumab immunotherapy. *Journal of Immunotherapy*, 40(1), 36-38.