

Correlation between Current Histopathological Grading and Anatomical Location of Mucoepidermoid Carcinoma of Salivary Glands

Ahamed, S^{1*}, Alam, M. M², Gain, S. K³

¹Dr. Shaheen Ahamed, Assistant Professor, Department of Oral and Maxillofacial Surgery, Dental Unit, Rajshahi Medical College, Rajshahi, Bangladesh

²Dr. Mohammad Morshed Alam, Assistant Professor, Department of Oral and Maxillofacial Surgery, Dental Unit, Chattogram Medical College, Chattogram, Bangladesh

³Dr. Sumanta Kumar Gain, Assistant Professor, Department of Oral and Maxillofacial Surgery, Dhaka Dental College Hospital, Dhaka, Bangladesh

DOI: 10.36347/sjds.2022.v09i07.004

| Received: 14.07.2022 | Accepted: 22.08.2022 | Published: 27.08.2022

*Corresponding author: Dr. Shaheen Ahamed

Assistant Professor, Department of Oral and Maxillofacial Surgery, Dental Unit, Rajshahi Medical College, Rajshahi, Bangladesh

Abstract

Original Research Article

Introduction: Mucoepidermoid carcinoma (MEC) is a kind of salivary cancer with a wide range of biologic activity. Mucoepidermoid tumors are the only kind of cancer where histologic grading and clinical behavior features are linked. Given the relative rarity of this disease, while being the most prevalent of the salivary gland malignancies, this is a common problem in the MEC literature. The aim of the study was to observe the correlation of MEC histopathological grading and anatomical location. **Methods:** This observational descriptive cross-sectional multi-center study was conducted at the Department of Oral and Maxillofacial Surgery, Dhaka Dental College Hospital, Dhaka, Department of Otolaryngology & Head Neck Surgery, Dhaka Medical College Hospital, Dhaka, and Department of Otolaryngology-Head Neck Surgery, Bangabandhu Sheikh Mujib Medical University, Dhaka, Bangladesh. The study duration was 1.5 years, from July 2011 to December 2012. A total of 20 patients attending the study centers with diagnosed case of mucoepidermoid carcinoma of salivary glands was selected for the study following inclusion and exclusion criteria. **Result:** 40% of the participants were from the age group of 31-40 years, while another 30% were under the age of 21 years. 70% of the participants were female. Histological grading of the participants revealed 9 low grade, 8 intermediate grade, and 4 high-grade MEC tumor cases. High-grade tumor MEC had an association with increasing age and male gender. The swelling was a common clinical feature among all the participants, whereas ulceration was observed in 75% of high-grade tumor patients. Parotid gland was the most common location at 45%, followed by 30% tumors occurring at the palate. Among the 9 parotid gland carcinomas, 55.6% were from MEC intermediate grade, 33.3% from low grade and the remaining 11.1% from MEC high grade by histological grading. Among the 6 carcinomas of the palate, 50% were low grade, 33.3% were intermediate grade, and 16.7% were from MEC high grade. Among the 3 maxilla carcinoma cases, grade distribution was equal, with 1 patient belonging to each histological grades. Among the submandibular gland carcinomas, 50% were low grade and 50% were high grade. **Conclusion:** The study showed a correlation of the anatomical location of tumor with their histological grading, with different locations of tumor having different prevalence of histological grading. Anatomical location of the tumor also seemed to be affected by the gender of patients, although no significant association was recorded.

Keywords: Histological, Tumor, Carcinoma, Anatomical, Salivary.

Copyright © 2022 The Author(s): This is an open-access article distributed under the terms of the Creative Commons Attribution 4.0 International License (CC BY-NC 4.0) which permits unrestricted use, distribution, and reproduction in any medium for non-commercial use provided the original author and source are credited.

INTRODUCTION

Although mucoepidermoid carcinoma accounts for less than 10% of all salivary gland tumors, it accounts for around 30% of all malignant salivary gland tumors. About half of the cases include the main salivary glands; more than 80% involve the parotid gland, 8-13% involve the submandibular gland, and 2-4% involve the sublingual gland. MEC is most usually

found on the palate in the minor salivary glands, although it can also be present in the retromolar region, the floor of the mouth, buccal mucosa, lip, and tongue [1]. The central osseous origin of this is extremely uncommon, accounting for just approximately 2% to 4% of all MEC. It is the most prevalent kind of malignant salivary gland tumor in children and teenagers under the age of 20. The frequency of

mucoepidermoid carcinomas is highest in the third to fifth decades of life, with an equal gender representation seen. The yearly case count is 0.44. Per 100,000 people [2]. MEC often manifests as a single, hard, and painless lesion in the main salivary glands. Despite their modest size, sublingual gland lesions can cause discomfort. Superficial intraoral neoplasms may appear blue-red and resemble a mucocele or vascular lesion. Papillary mucosa may produce palatal tumors. Cortical bone is occasionally superficially eroded. As with other malignant neoplasms, more than half of patients with this carcinoma are aware of the tumor for less than 6 months. Two-thirds of people are asymptomatic. Some patients indicate that the lump grew quickly, while others suffer discomfort, hemorrhage, dysphagia, trismus, and facial paralysis. The clinical characteristics of each can vary substantially and are crucial in determining grade. Low-grade tumors are typically less than 3.0 cm in diameter and develop slowly. Patients are typically aware of their presence for 3 to 6 years. Most tumors do not become ulcerated or become ulcerated only after a long period of time, causing the patient to seek therapy. The AFIP grading system, the modified Healey system, and the Brandwein system are the three most prevalent grading systems [3]. All categories evaluate a comparable collection of cytomorphologic and architectural criteria, as well as perineural and angio-lymphatic invasion. MEC is more common among adults between the ages of 40-60 years, and has a slight female prevalence among the affected [4, 7]. MEC is generally thought to occur from the reserve cells located in the salivary glands, and is made up from mucus, intermediate cells and epidermoid [6]. MEC often manifests as a slow-growing, painless swelling that lasts for a long time. In aggressive MEC, pain and ulceration are common, especially when the facial nerve is involved. Many western studies have been conducted to research the causes and effects of MEC of the salivary glands, but such studies are scarce in our demographic. The present study was conducted to observe the relation of histopathological grading of MEC among participants with their anatomical locations.

OBJECTIVE

General Objective

- To observe the correlation of MEC histopathological grading and anatomical location.

METHODS

This observational descriptive cross-sectional multi-center study was conducted at the Department of Oral and Maxillofacial Surgery, Dhaka Dental College Hospital, Dhaka, Department of Otolaryngology & Head Neck Surgery, Dhaka Medical College Hospital, Dhaka, and Department of Otolaryngology-Head Neck Surgery, Bangabandhu Sheikh Mujib Medical University, Dhaka, Bangladesh. The study duration was 1.5 years, from July 2011 to December 2012. A total of 20 patients attending the study centers with diagnosed case

of mucoepidermoid carcinoma of salivary glands was selected for the study following inclusion and exclusion criteria. General information including the patient's name, age, sex, and address was recorded in a performed questionnaire. Informed written consent was obtained from all the participants, and ethical approval was also obtained from the respective study hospitals. Clinical parameters including patients' age, gender, symptoms, tumor site, size, and duration were recorded. A histopathological examination was performed according to the protocol published by the Brandwein system [1]. This algorithm is recommended as the current standard because of its enhanced predictability and proven reproducibility with characteristic features. The grading schema assigned points to various histologic features, including the pattern of infiltration, vascular invasion, and bony invasion. Low-grade tumors have a score of 0; Intermediate grade, 2-3 points; and high grade, >4 points. Data was collected using a pre-made questionnaire and analyzed using SPSS v16 software. Descriptive statistics were generated to see the distribution of baseline characteristics of the patient. A two-sided $p < 0.05$ level of significance was selected for all analyses.

Inclusion Criteria

- Patients histologically diagnosed with mucoepidermoid carcinoma of salivary gland neoplasm
- Patients who had given consent to participate in the study.

Exclusion Criteria

- Have not given consent to be included in the study.
- Lesion histological diagnosed as mucoepidermoid carcinoma of salivary gland neoplasm with suspicion.
- Salivary gland swelling which are diagnosed with other neoplastic diseases and non-neoplastic lesion confirmed by histopathology.
- Psychotic or handicraft patients having mucoepidermoid carcinoma of salivary gland neoplasm.
- Exclude those affected with other chronic diseases etc.

RESULTS

Table 1: Age distribution of the participants [N=20]

| Age in group | Frequency | Percent |
|--------------|-----------|---------|
| <21 years | 6 | 30 |
| 21-30 | 3 | 15 |
| 31-40 | 8 | 40 |
| 41-50 | 2 | 10 |
| 51-60 | 1 | 5 |
| Total | 20 | 100 |

The table shows that 40% of the participants were from the age group of 31-40 years, while another

30% were under the age of 21 years. The mean age of the participants was 30.9 ± 11.42 years.

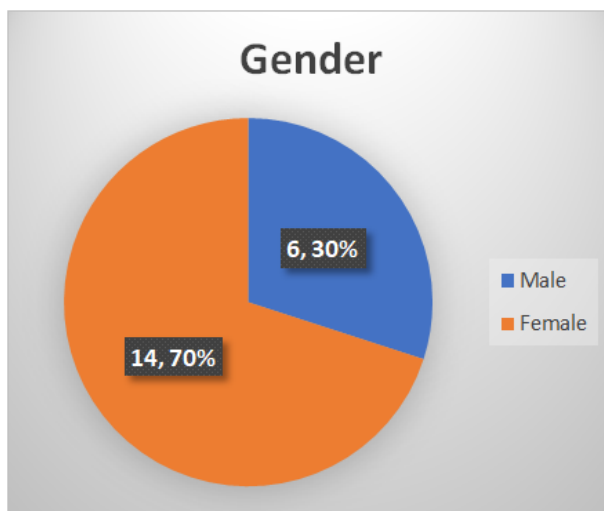


Figure 1: Gender Distribution of the participants [N=20]

Among the total 20 participants, female predominance was observed, as 70% of the participants were female and only 30% were male.

Table 2: Distribution of the participants by histological grading [N=20]

| Histological Grading | Frequency | Percent |
|------------------------|-----------|---------|
| MEC low grade | 8 | 40 |
| MEC Intermediate grade | 8 | 40 |
| MEC high grade | 4 | 20 |

According to the histological grading of the participants, 8 (40.0%) were diagnosed with MEC low

grade, another 8 (40.0%) were diagnosed with MEC intermediate grade, and 4 were with MEC high grade.

Table 3: Distribution of the respondents by age in relation to histological grading [N=20]

| Age in group | MEC low grade n (%) | MEC intermediate grade n (%) | MEC high grade n (%) | Total |
|--------------|---------------------|------------------------------|----------------------|--------|
| <21 years | 4(20%) | 2(10%) | 0 | 6(30%) |
| 21-30 | 1(5%) | 2(10%) | 0 | 3(15%) |
| 31-40 | 2(10%) | 4(20%) | 2(10%) | 8(40%) |
| 41-50 | 1(5%) | 0 | 1(5%) | 2(10%) |
| 51-60 | 0 | 0 | 1(5%) | 1(5%) |
| Total | 8(40%) | 8(40%) | 4(20%) | 100% |

Observing the distribution of respondents by age and their histological grading, it was observed that all the MEC high-grade patients were over 30 years of

age, while MEC low and intermediate-grade patients generally belonged to younger age groups.

Table 4: Distribution of the respondents by gender in relation to histological grading [N=20]

| Sex | MEC Low grade n(%) | MEC Intermediate grade n(%) | MEC High grade n(%) | Total n(%) |
|--------------|--------------------|-----------------------------|---------------------|------------|
| Female | 6(42.9%) | 7(50.0%) | 1(7.1%) | 14(100.0%) |
| Male | 2((33.3%) | 1(16.7%) | 3(50.0%) | 6(100.0%) |
| Total | 8(40.0%) | 8(40.0%) | 4(20.0%) | 20(100%) |

It was observed that MEC low and intermediate grades were more prevalent among the

female population, whereas half the male population belonged to MEC high-grade group.

Table 5: Distribution of the participants by anatomical location [N=20]

| Anatomical location | Frequency | Percentage |
|---------------------|-----------|------------|
| Parotid gland | 9 | 45 |
| Palate | 6 | 30 |
| Maxilla | 3 | 15 |
| Submandibular gland | 2 | 10 |
| Total | 20 | 100 |

According to the anatomical locations of the mucoepidermoid carcinoma, parotid gland was the most common location at 45%, followed by 30% cases

occurring at the palate, 15% at the maxilla and 10% at the submandibular gland.

Table 6: Distribution of the respondents by gender in relation to anatomical location [N=20]

| Anatomical location | Male n(%) | Female n(%) |
|---------------------|-----------|-------------|
| Parotid gland | 6 (42.9) | 3 (50) |
| Palate | 5 (35.7) | 1 (16.7) |
| Maxilla | 2 (14.3) | 1 (16.7) |
| Submandibular gland | 1 (7.1) | 1 (16.6) |
| Total | 14 (100) | 6 (100) |

In relation anatomical location, prevalence of parotid gland carcinoma was slightly higher among the female population, compared to the male population (50% vs 42.9%). Carcinoma of the palate was more

common among male (35.7%) compared to the female population (16.7%). Maxilla and submandibular gland carcinomas had more prevalence among the female population.

Table 7: Distribution of the participants by histological grading in relation to anatomical location [N=20]

| Histological grading | Parotid gland n (%) | Palate n (%) | Maxilla n (%) | Submandibular gland n (%) |
|------------------------|---------------------|--------------|---------------|---------------------------|
| MEC Low grade | 3(33.3%) | 3(50.0%) | 1(33.3%) | 1(50.0%) |
| MEC Intermediate grade | 5(55.6%) | 2(33.3%) | 1(33.3%) | 0 |
| MEC High grade | 1(11.1%) | 1(16.7%) | 1(33.3%) | 1(50.0%) |

Among the 9 parotid gland carcinomas, 55.6% were from MEC intermediate grade, 33.3% from low grade and the remaining 11.1% from MEC high grade by histological grading. Among the 6 carcinomas of the palate, 50% were low grade, 33.3% were intermediate

grade, and 16.7% were from MEC high grade. Among the 3 maxilla carcinoma cases, grade distribution was equal, with 1 patient belonging to each histological grades. Among the submandibular gland carcinomas, 50% were low grade and 50% were high grade.

Table 8: Distribution of the respondents by clinical features in relation to anatomical location [N=20]

| Clinical feature | Parotid n (%) | Palate n (%) | Submandibular n (%) | Maxilla n(%) | Total |
|------------------|---------------|--------------|---------------------|--------------|-----------|
| Swelling | 9 (47.4%) | 6(31.6%) | 2(10.5%) | 2(10.5%) | 19 (100%) |
| Pain | 1(33.3%) | 0(0.0%) | 1(33.3%) | 1(33.3%) | 3 (100%) |
| Ulceration | 1(33.3%) | 1 (33.3%) | 0(0.0%) | 1(33.3%) | 3 (100%) |
| Trismus | 0(0.0%) | 0(0.0%) | 1(100.0%) | 0(0.0%) | 1 (100%) |
| Discharge | 0(0.0%) | 0(0.0%) | 0(0.0%) | 1(100.0%) | 1 (100%) |
| Epistaxis | 0(0.0%) | 0(0.0%) | 0(0.0%) | 1(100.0%) | 1 (100%) |

Among the different clinical features, swelling had the highest prevalence among parotid carcinoma locations (47.4%), and was prevalent in 19 out of the total 40 cases. Pain was observed in parotid, submandibular and maxilla carcinoma cases each.

DISCUSSION

Twenty instances of mucoepidermoid carcinoma of the salivary glands were investigated clinically and histopathologically in this investigation. The purpose of this study was to determine the

relationship between tumor anatomical location and histological grade of mucoepidermoid carcinoma of the salivary glands. All tumors were histopathologically rated using the Brandwein point-based histological grading system, with the results as follows: low-grade (n=8), intermediate-grade (n=8), and high-grade (n=4) cancers. The results obtained in this series are generally consistent with prior reports on this issue [8, 9]. The majority of cases in this series were evenly split between the age groups of 21 (30%) and 31-40years (30 percent). In this series, 14 (70%) of the 20 cases were

female, whereas the remaining 6 (30%) were male. Female preponderance was detected in our study, which was consistent with the findings of a few previous global investigations, but the difference was not as pronounced [10, 11]. Patients over the age of 31 were more likely to have high-grade MEC, whereas younger populations had low- or intermediate-grade MEC. This was comparable to a large-scale investigation conducted in 2014 [12]. A link between high grade MEC tumor and male population was also discovered. MEC was more common prevalent in the parotid gland, followed by 30% prevalence in the palate region. Comparing these findings with histopathological grading, it was observed that majority of parotid gland MEC were of intermediate grade, while 50% of the palate region's MEC were from low grade. Incidence of maxilla was equally distributed among all three histological grading of MEC. However, none of the submandibular gland carcinomas belonged to the intermediate grade category, and 1 belonged to low grade while the remaining one belonged to high histological grade MEC. Comparing the gender of the participants with anatomical location of the tumor, it was observed that among the different locations of tumor, men had higher frequency of MEC on parotid gland and palate, and low frequency in maxilla and submandibular gland, whereas women had higher frequencies of tumor on parotid gland, and an equal distribution on the other locations. All of parotid tumors, palatal and submandibular gland except maxilla tumors presented with swelling. Pain and ulceration was the second most clinical presentation.

Limitations of the Study

The study was conducted in multiple hospitals with a small sample size. So, the results may not represent the whole community.

CONCLUSION

The study showed a correlation of the anatomical location of tumor with their histological grading, with different locations of tumor having different prevalence of histological grading. Anatomical location of the tumor also seemed to be affected by the gender of patients, although no significant association was recorded.

Funding: No funding sources.

Conflict of interest: None declared.

Ethical approval: The study was approved by the Institutional Ethics Committee.

REFERENCES

1. Brandwein, M. S., Ivanov, K., Wallace, D. I., Hille, J. J., Wang, B., Fahmy, A., ... & Mills, S. E. (2001). Mucoepidermoid carcinoma: a clinicopathologic study of 80 patients with special reference to histological grading. *The American journal of surgical pathology*, 25(7), 835-845.

2. Regezi, J. A., Scuibba, J. J., & Jordan, R. C. K. (2008). *Oral Pathology: Clinical Pathologic Correlations*. 5th ed. Philadelphia: W.B Saunders Elsevier Health Sciences, 203.
3. Seethala, R. R. (2009). An update on grading of salivary gland carcinomas. *Head and neck pathology*, 3(1), 69-77.
4. Qureshi, A., Rehman, K., Husain, S., Khawaja, N. H., Qureshi, G. R., & Naveed, I. A. (2004). Salivary gland tumours-a three years experience at King Edward Medical College, Lahore. *Annals of King Edward Medical University*, 10(2).
5. Gill, M. S., Muzaffar, S., Soomro, I. N., Kayani, N., Hussainy, A. S., Pervez, S., & Hasan, S. H. (2001). Morphological pattern of salivary gland tumours. *Journal of Pakistan Medical Association*, 51(10), 343.
6. Ozawa, H., Tomita, T., Sakamoto, K., Tagawa, T., Fujii, R., Kanzaki, S., ... & Fujii, M. (2008). Mucoepidermoid carcinoma of the head and neck: clinical analysis of 43 patients. *Japanese journal of clinical oncology*, 38(6), 414-418.
7. Nance, M. A., Seethala, R. R., Wang, Y., Chiosea, S. I., Myers, E. N., Johnson, J. T., & Lai, S. Y. (2008). Treatment and survival outcomes based on histologic grading in patients with head and neck mucoepidermoid carcinoma. *Cancer*, 113(8), 2082-2089.
8. Ellis, G., & Auclair, P. editors. (1996). *Tumors of the salivary glands. Atlas of tumor pathology. No. 17, 3rd Series ed, Washington DC: Armed Forces Institute of Pathology.*
9. Auclair, P. L., Goode, R. K., & Ellis, G. L. (1992). Mucoepidermoid carcinoma of intraoral salivary glands. Evaluation and application of grading criteria in 143 cases. *Cancer*, 69, 2021-2030.
10. Liu, S., Ow, A., Ruan, M., Yang, W., Zhang, C., & Wang, L. (2014). Prognostic factors in primary salivary gland mucoepidermoid carcinoma: an analysis of 376 cases in an Eastern Chinese population. *International journal of oral and maxillofacial surgery*, 43(6), 667-673.
11. Ito, F. A., Ito, K., Vargas, P. A., De Almeida, O. P., & Lopes, M. A. (2005). Salivary gland tumors in a Brazilian population: a retrospective study of 496 cases. *International journal of oral and maxillofacial surgery*, 34(5), 533-536.
12. Chen, M. M., Roman, S. A., Sosa, J. A., & Judson, B. L. (2014). Histologic grade as prognostic indicator for mucoepidermoid carcinoma: A population-level analysis of 2400 patients. *Head & neck*, 36(2), 158-163.