

Hepatectomy: Indications and Results

Boudda S^{1*}, Nacir O¹, Louzi A²¹Gastrology service of University Hospital Centre Mohamed VI of Marrakech²Digestive Surgery Division of University Hospital Centre Mohamed VI of MarrakechDOI: [10.36347/sasjs.2020.v06i08.004](https://doi.org/10.36347/sasjs.2020.v06i08.004)

| Received: 24.07.2020 | Accepted: 03.08.2020 | Published: 16.08.2020

*Corresponding author: Boudda S

Abstract

Original Research Article

Background: Surgery remains the only effective treatment for malignant liver tumors today. It is also indicated for the treatment of some benign diseases of the liver. In recent decades, hepatic surgery has seen its indications multiply thanks to advances in surgical techniques, imaging and anesthesia. **Aim:** To evaluate the different techniques employed in the liver resection as well as surgical indications to analyze results of morbidity and mortality. **Patients and methods:** Retrospective review of medical records of patients who underwent liver resection at the Digestive Surgery Division of University Hospital Centre Mohamed VI of Marrakech between march 2017 and december 2019. **Results:** twenty five (15 women and 10 men) patients underwent liver resection during the study period, with a mean age of 61.2 years (range 23-79 years). Surgical indications were dominated by the malignant lesions 60% of cases, 12% of benign lesions and 28% of liver transplant. Major resections were performed in 11 patients. Vascular clamping was conducted in 72% of cases. Abdominal drainage has been made in 88% of cases and biliary drainage has never been realized. For additional acts, 2 major gestures haven't been achieved. There was no intraoperative death and postoperative morbidity was 20% and the overall mortality rate was 0%. **Conclusion:** The search of reduced morbidity and mortality in hepatic resection passes by a better selection of patients and indications, by a rigorous procedure and an optimal assumption of complications.

Keywords: Liver, neoplasms, surgery, Neoplasm metastasis, hepatocellular carcinoma, Hepatectomy, liver transplant, Risk factors.

Copyright @ 2020: This is an open-access article distributed under the terms of the Creative Commons Attribution license which permits unrestricted use, distribution, and reproduction in any medium for non-commercial use (NonCommercial, or CC-BY-NC) provided the original author and source are credited.

INTRODUCTION

Since the first elective hepatic resections were performed nearly a century ago [1], the basic anatomic, pathophysiologic, and operative principles of liver surgery have been elucidated. However, the first successful elective liver resection, a left lobectomy in a patient presenting with a hepatic mass, was performed only in 1888 by Langenbuch [2]. In 1908, a great technical advance was implemented by Pringle, who established the vascular control of the liver by compressing the portal triad, a maneuver subsequently named after him [3]. However, the real breakthrough in liver surgery was set by COUINAUD in 1957, when he extensively described the portal segmental hepatic anatomy which nowadays provides the rationale for segment-oriented resections [4]. Advances in the diagnosis and assessment of liver diseases, anesthesia, and postoperative care have made liver resection a reasonably safe surgical procedure [5]. However, major hepatic resection remains a rarely performed operation.

The aim of the present study is to evaluate our experience with liver resections, mainly the indications, perioperative features and pathological findings in order to determine risk factors, morbidity and mortality of hepatectomy.

PATIENTS AND METHODS

Medical records of patients who underwent liver resection at the Digestive Surgery Division, "Hospital Arrazi", University Hospital Centre Mohamed VI of Marrakech, between March 2017 and December 2019 were reviewed. A protocol was created in order to obtain the following data: age, sex, relevant past medical history, including cirrhosis, chronic hepatitis and previous neoplasm, indication of hepatectomy, intraoperative data such as tumor location, extension of resection, employment of vascular exclusion, blood transfusion requirements and procedure duration, information related to the pathologist report (tumor size and histological type), and data regarding postoperative outcome, mainly postoperative complications, mortality index and hospital stay.

Operative Procedure

The initial surgical ways were dominated by the laparotomy under costal right hand side in 68% of all procedures, a bilateral subcostal incision was employed in 20% of cases, with an upward midline extension in 12% of procedures. Whenever vascular exclusion was necessary, it was performed as a continuous occlusion of the portal triad with a vascular clamp for up to 55 minutes. No pre-conditioning occlusion was employed. Parenchymal transection was performed by blunt dissection with a Kelly clamp and ligation of vessels and bile duct branches. Electrocoagulation was also widely employed. Operative blood transfusion was defined as the number of packed red cells infused during the operation and in the immediate postoperative period.

Nomenclature and Surgery Extension

The type of resection was classified according to the anatomical nomenclature of COUINAUD [6]. Resections were considered extended when involving five or more segments (extended right lobectomy and extended left hepatectomy), major when three or four segments were involved (right and left hepatectomies), and minor when one or two segments were resected or whenever a non-anatomical resection was performed.

RESULTS

A total of 25 liver resections were performed during the study period. fifteen patients were women and 10 men. The mean age was 61.2 years, ranging from 23 to 79. In 25 patients (36%) an underlying chronic disease was detected in the preoperative evaluation, usually systemic hypertension or diabetes mellitus. Chronic liver disease was diagnosed in 6 patients (24%). The operations performed are summarized in Table 1.

Table-1: Operative procedures

Procedure	n
<i>Total hepatectomy</i>	3
<i>Extended resections</i>	7
Right lobectomy	1
Left extended hepatectomy	6
<i>Major resections</i>	3
Right hepatectomy	1
Left hepatectomy	2
<i>Minor resections</i>	12
Bisegmentectomy	8
Segmentectomy	1
Non-anatomical resection	2
Metastasectomy	1

The indications for liver resection are listed in Table 2. The most common indication was malignant disease, which occurred in 15 patients (60%). Primary hepatic malignancy was the indication for resection in 12 cases (48%): bil duct cancer in 7 cases (28%), hepatocellular carcinoma in 3 cases (12%), intrahepatic cholangiocarcinoma in 2 cases (8%). Secondary hepatic malignancy occurred in 3 patients (12%): colorectal liver metastasis in 2 cases and bronchial liver metastasis in 1 case. Hepatic resection was performed for benign conditions in 3 patients, 2 with hydatid cyst, and 1 with secondary biliary cirrhosis. Liver transplant were also performed in 28% of cases, it includes 4 who underwent left hepatic resections (figure 1) for living-related transplantation and 3 receivers with a MELD score >15.

Table-2: Indications for liver resection

Diagnosis	n
<i>Malignant disease</i>	15
<i>primary</i>	12
Hepatocellular carcinoma	3
Bile duct cancer	7
Intrahepatic cholangiocarcinoma	2
<i>secondary</i>	3
Colorectal liver metastasis	2
Noncolorectal liver metastasis	1
<i>Begnin disease</i>	3
Hydatid cyst	2
Biliary cirrhosis	1
<i>Living related transplantation</i>	7

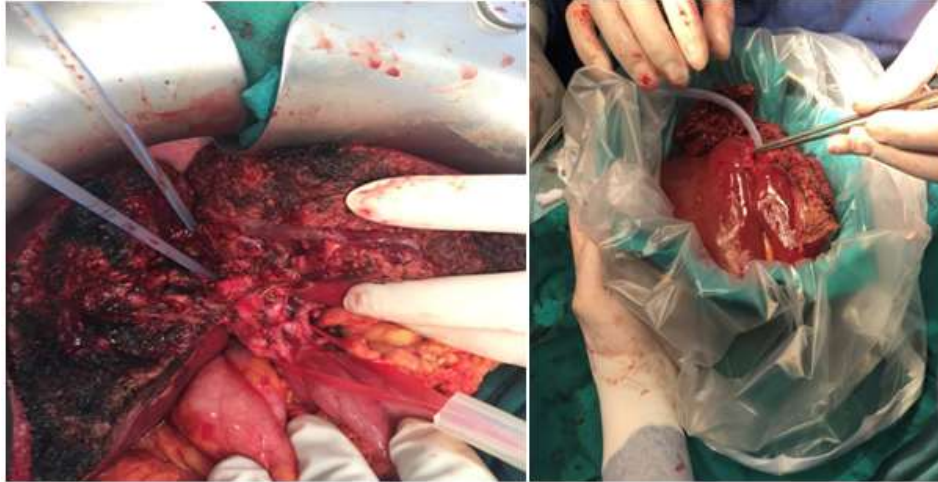


Fig-1: Intraoperative photograph of a left hepatectomy from a living donor (iconography of the Arrazi visceral surgery department)

The mean operative time was 258 minutes, ranging from 180 to 420 minutes. Vascular clamping was conducted in 72% of cases. Abdominal drainage has been made in 88% of cases and biliary drainage has

never been realized. For additional acts, 2 major gestures haven't been achieved : one partial gastrectomy (figure 2) and one left hemicolectomy (figure 3).

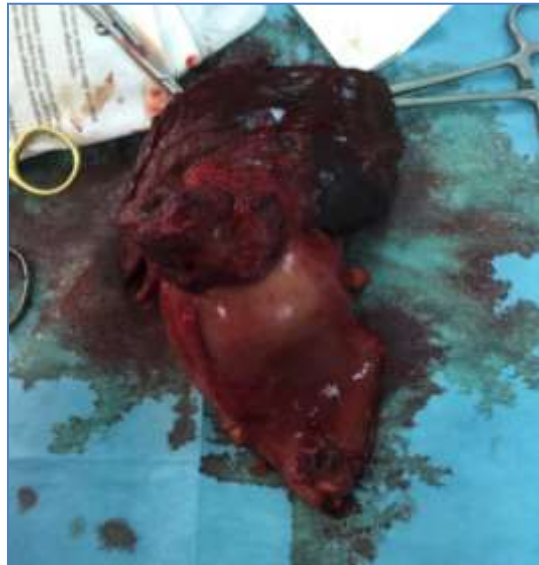

Fig-2 : Hepatic bisegmentectomy (IV + V) removing the tumor gall bladder and gastric antrum (iconography of the visceral surgery department of Arrazi hospital)

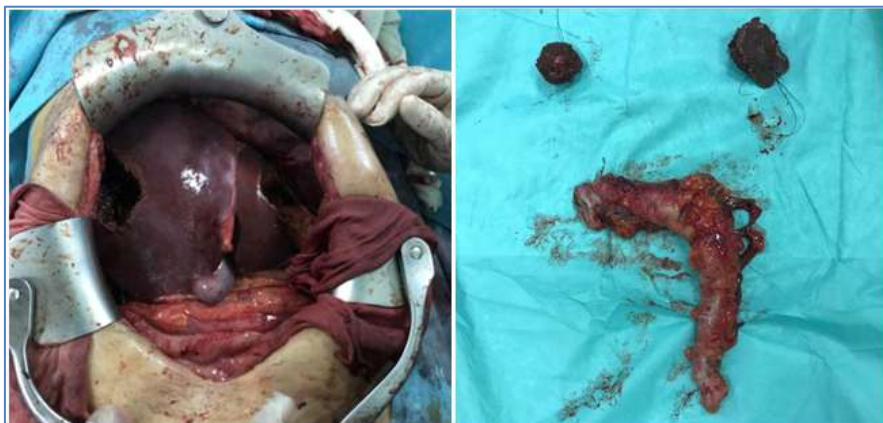

Fig-3: Metastasectomy associated with a left hemicolectomy (iconography of the visceral surgery department of Arrazi hospital)

Five patients (20%) required blood transfusion, with a mean of two units of packed red cells. Operative mortality was defined as any death occurring during the surgical procedure or within the 30th postoperative day. When death occurred in the same admission of the surgical procedure, it was defined as hospital mortality. The overall mortality rate was 0%.

Complications were observed in 5 patients (20%). Pulmonary embolism was the major complication, occurring in 2 patients (8%). Peritoneal effusion was observed in one patient. Pleural effusion was observed in one case and biliary leak in one case.

DISCUSSION

Despite improvements in chemoembolization, cryosurgery and other modalities of treatment, liver resection remains the procedure of choice in the management of most primary liver tumors [7]. Liver transplantation is the best approach in selected cases, mainly in patients with liver cirrhosis and small tumors [8]. Hepatectomy is the mainstay treatment of selected patients with metastatic liver tumors, especially those in which the primary site is the large bowel [9]. However, this procedure has been associated with significant morbidity and mortality.

The median age of patients was 61.2 years old with extreme ranging from 23 to 79 years old, which corresponds to the data of the literature: 59.6 years for Kanematsu [10]; 59.1 years for Pinna [11]. This can be explained by the frequency of tumoral pathologies in the elderly, which is the major indication for hepatectomies.

The most common indication of liver resection in our series was malignant liver diseases, accounting for 60% of cases, benign liver disease occurred in 12%. These results are similar to those of a recently published multicentric study reporting the outcomes of 1670 patients subjected to hepatectomy. In this series, 78% of the patients underwent resection for malignant disease and 22% for benign liver disease [12].

Liver resection has been associated with high morbidity and mortality. The reported morbidity has ranged from 16.2% to 81% [13]. This enormous range is partially due to the heterogeneity of the published series, with major differences in indication, extension of hepatic resection, percentage of patients with cirrhosis and definition of postoperative complication. Our rate of postoperative morbidity was 20% and the overall mortality rate was 0%. Currently, the concept of improved rehabilitation after surgery was introduced by Khelet and his team in colorectal surgery and subsequently extended to hepatic surgery, with the aim of reducing the rate of postoperative complications and the length of hospitalization [14].

The increased mortality and morbidity associated with intraoperative bleeding has been reported in the literature [15]. In the literature, blood loss is between 600 and 1000 ml [16] but can reach 2 liters. The risk of having to transfuse appears to increase with the extent of the resection [15]. Morbidity linked to blood transfusions seems to appear beyond 600 ml of transfused red blood cells, ie around 3 bags [17]. For this purpose, the value of autotransfusions was underlined. In the series by Belghiti [15], 23% of patients received a transfusion of 2 red blood cells on average. In our series, 20% of patients received an exclusive homologous blood transfusion, with an average of 2 red blood cells.

Vascular clamping is an effective way to reduce surgical bleeding. Normothermal liver ischemia has moderate consequences on perioperative morbidity and mortality, up to 60 minutes, provided that the remaining parenchyma is healthy.

In our series, vascular clamping was performed 18 times (72% of cases) and it was pedicle clamping each time. Intermittent clamping was performed 6 times (24% of cases), and 6 hepatic resections were performed without vascular clamping, (24% of cases), with an average cumulative duration of 55 +/- 20 min. The clamping duration in our series is close to that of Fujii [18] with 54 +/- 23 min and Balzan [19] with a cumulative duration of 48 +/- 23 min on average.

Also The duration of the operation has been reported as a risk factor for infection, favoring the formation of intra-abdominal abscesses [20], as well as the development of other postoperative complications. In our series, the intervention time was 4 hours and 30 minutes on average (258 minutes) with extremes ranging from 180 to 420 minutes.

Biliary complications represent another major topic in liver surgery. The central hepatic resections would cause more postoperative biliary fistulas, because they perform hepatectomy slices of large surface and expose the convergence. Finally, performing an intraoperative cholangiography before hepatic resection to detect anatomical variation, and performing a bile duct leakage test at the end of the operation are considered by some authors to be effective means to prevent biliary fistulas [21]. In our series, a case of bile leakage through the drain was reported in a patient with spontaneous dry-up after 14 days.

CONCLUSION

The search of reduced morbidity and mortality in hepatic resection passes by a better selection of patients and indications, by a rigorous procedure and an optimal assumption of complications. The impact of blood transfusion on perioperative outcome highlights

the need for advances in control of operative blood loss. Blood transfusion may be reduced by employing meticulous surgical technique and, whenever indicated, vascular exclusion

REFERENCE

1. Foster JH. Highlights in the history of liver tumors and their resection. *Solid liver tumors*. 1977;9-27.
2. Fan ST, Lo CM, Liu CL, Lam CM, Yuen WK, Yeung C, Wong J. Hepatectomy for hepatocellular carcinoma: toward zero hospital deaths. *Annals of surgery*. 1999 Mar;229(3):322.
3. Pringle JH. V. Notes on the arrest of hepatic hemorrhage due to trauma. *Annals of surgery*. 1908 Oct;48(4):541.
4. Couinaud C, Nogueira C. Les veines sus-hépatiques chez l'homme. *Cells Tissues Organs*. 1958;34(1-2):84-110.
5. Vezinet C, Eyraud D, Savier E. Anesthésie pour chirurgie hépatique. *Le Praticien en anesthésie réanimation*. 2009 Dec 1;13(6):418-28.
6. Lafortune M, Madore F, Patriquin H, Breton G. Segmental anatomy of the liver: a sonographic approach to the Couinaud nomenclature. *Radiology*. 1991 Nov;181(2):443-8.
7. Petrović T, Majdevac I, Budišin N, Radovanović Z, Nikolić I, Nikin Z, Gavrančić B, Mihailović J. The results of surgical treatment of metastatic liver tumor. *Archive of Oncology*. 2010 Jan;18(1-2):14-6.
8. Clavien PA, Lesurtel M, Bossuyt PM, Gores GJ, Langer B, Perrier A. Recommendations for liver transplantation for hepatocellular carcinoma: an international consensus conference report. *The lancet oncology*. 2012 Jan 1;13(1):e11-22.
9. Acciuffi S, Meyer F, Bauschke A, Settmacher U, Lippert H, Croner R, Altendorf-Hofmann A. Analysis of prognostic factors after resection of solitary liver metastasis in colorectal cancer: a 22-year bicentre study. *Journal of cancer research and clinical oncology*. 2018 Mar 1;144(3):593-9.
10. Kanematsu T, Furui J, Yanaga K, Okudaira S, Shimada M, Shirabe K. A 16-year experience in performing hepatic resection in 303 patients with hepatocellular carcinoma: 1985-2000. *Surgery*. 2002 Jan 1;131(1):S153-8.
11. Pinna AD, Yang T, Mazzaferro V, De Carlis L, Zhou J, Roayaie S, Shen F, Sposito C, Cescon M, Di Sandro S, Yi-Feng H. Liver transplantation and hepatic resection can achieve cure for hepatocellular carcinoma. *Annals of surgery*. 2018 Nov 1;268(5):868-75.
12. Reddy SK, Barbas AS, Turley RS, Steel JL, Tsung A, Marsh JW, Geller DA, Clary BM. A standard definition of major hepatectomy: resection of four or more liver segments. *Hpb*. 2011 Jul 1;13(7):494-502.
13. Nagino M, Kamiya J, Uesaka K, Sano T, Yamamoto H, Hayakawa N, Kanai M, Nimura Y. Complications of hepatectomy for hilar cholangiocarcinoma. *World journal of surgery*. 2001 Oct 1;25(10):1277-83.
14. Brustia R, Slim K, Scatton O. Récupération améliorée après chirurgie hépatique. *Journal de Chirurgie Viscérale*. 2019 Apr 1;156(2):143-54.
15. Belghiti J, Hiramatsu K, Benoist S, Massault PP, Sauvanet A, Farges O. Seven hundred forty-seven hepatectomies in the 1990s: an update to evaluate the actual risk of liver resection. *Journal of the American College of Surgeons*. 2000 Jul 1;191(1):38-46.
16. Shimada K, Sakamoto Y, Esaki M, Kosuge T, Morizane C, Ikeda M, Ueno H, Okusaka T, Arai Y, Takayasu K. Analysis of prognostic factors affecting survival after initial recurrence and treatment efficacy for recurrence in patients undergoing potentially curative hepatectomy for hepatocellular carcinoma. *Annals of surgical oncology*. 2007 Aug 1;14(8):2337-47.
17. Pol B, Campan P, Hardwigsen J, Botti G, Pons J, Le Treut YP. Morbidity of major hepatic resections: a 100- case prospective study. *European Journal of Surgery*. 1999 Jul;165(5):446-53.
18. Fujii Y, Nanashima A, Hiyoshi M, Imamura N, Yano K, Hamada T. Risk factors for hepatic insufficiency after major hepatectomy in non-cirrhotic patients. *Asian journal of surgery*. 2019 Jan 1;42(1):251-5.
19. Balzan S, Belghiti J, Farges O, Ogata S, Sauvanet A, Delefosse D, Durand F. The "50-50 criteria" on postoperative day 5: An accurate predictor of liver failure and death after hepatectomy. *Annals of surgery*. 2005 Dec;242(6):824.
20. Yanaga KA, Kanematsu T, Takenaka KE, Sugimachi KE. Intraoperative septic complications after hepatectomy. *Annals of surgery*. 1986 Feb;203(2):148.
21. Yamashita YI, Hamatsu T, Rikimaru T, Tanaka S, Shirabe K, Shimada M, Sugimachi K. Bile leakage after hepatic resection. *Annals of surgery*. 2001 Jan;233(1):45.