

## Multiple Arterial Thrombosis Revealing Essential Thrombocythemia: A Case Report

Basma Dihi<sup>1\*</sup>, Youssra El Adlouni<sup>1</sup>, Mariam Lamhani<sup>1</sup>, El Jamili Mohammed<sup>1</sup>, El Karimi Saloua<sup>1</sup>, Benzarouel Dounia<sup>1</sup>, El Hattaoui Mustapha<sup>1</sup>

<sup>1</sup>Department of Cardiology, Mohammed VI University Hospital Center, Marrakech, Morocco

DOI: [10.36347/sjmcr.2022.v10i09.009](https://doi.org/10.36347/sjmcr.2022.v10i09.009)

| Received: 09.06.2022 | Accepted: 24.07.2022 | Published: 10.09.2022

\*Corresponding author: Basma Dihi

Department of Cardiology, Mohammed VI University Hospital Center, Marrakech, Morocco

### Abstract

### Case Report

Myeloproliferative neoplasia is a group of acquired hemopathies most often affecting adults and whose morbidity and mortality are largely due to disorders of hemostasis. The most frequent complications are thrombosis, which preferentially affects the arterial territory, but also more atypical localizations. We report in this observation the case of a 63 year old female patient admitted for several arterial thromboses which had revealed Essential thrombocythemia.

**Keywords:** thrombosis, essential thrombocythemia, Non-ST-segment elevation acute coronary syndrome.

Copyright © 2022 The Author(s): This is an open-access article distributed under the terms of the Creative Commons Attribution 4.0 International License (CC BY-NC 4.0) which permits unrestricted use, distribution, and reproduction in any medium for non-commercial use provided the original author and source are credited.

## INTRODUCTION

Essential thrombocythemia is one of the disorders of the blood grouped under the name of "myeloproliferative syndromes". It is characterized by an over-production of blood platelets in the bone marrow. It is generally revealed either by a blood test showing a significant increase in the number of platelets, or by symptoms or complications, including arterial thrombotic events. The main issue is the risk of potential thrombosis due to platelet hyperreactivity [1].

## CASE REPORT

We report in this observation the case of a 63-year-old Moroccan patient with no particular personal or family pathological history.

She was admitted to the emergency room initially for left hemiplegia of abrupt onset since 22 hours before her admission.

On physical examination on admission, the patient was obnoxious, polypnic at 27 cycles/minute, 80% desaturated on room air. The heart rate was regular at 80 beats per minute, with a systolic blood pressure of 110mmHg.

No murmurs or pops were present on auscultation, pulmonary and abdominal examination

revealed no and abdominal examination revealed no significant abnormalities.

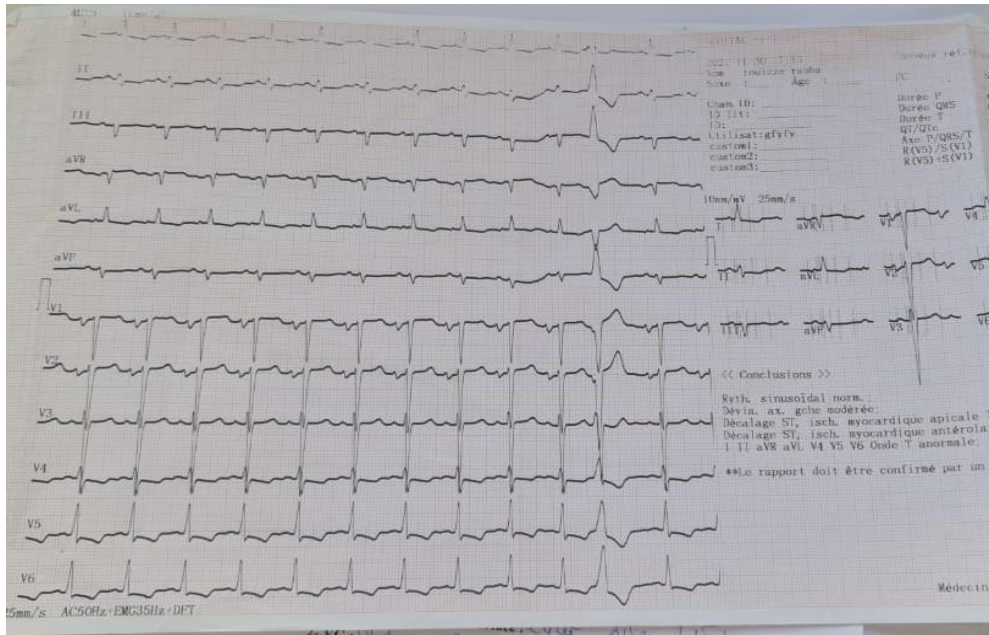
In addition, a cold and cyanotic left upper limb with abolition of radial and ulnar pulses and a skin recoloration time exceeding 3 seconds was noted.

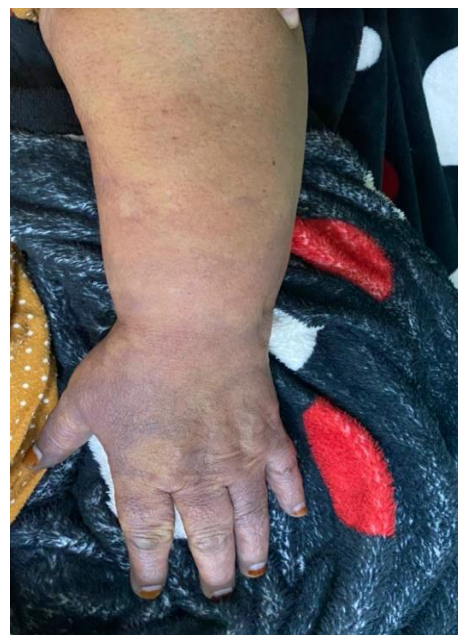

Figure 1: This photo is an objective view of our patient's ischemic left upper limb

The neurological examination revealed left hemiplegia.

The Electrocardiogram obtained revealed an elevation of the ST segment in aVr with ST depression in the apical, lateral and inferior leads (Figure 2).

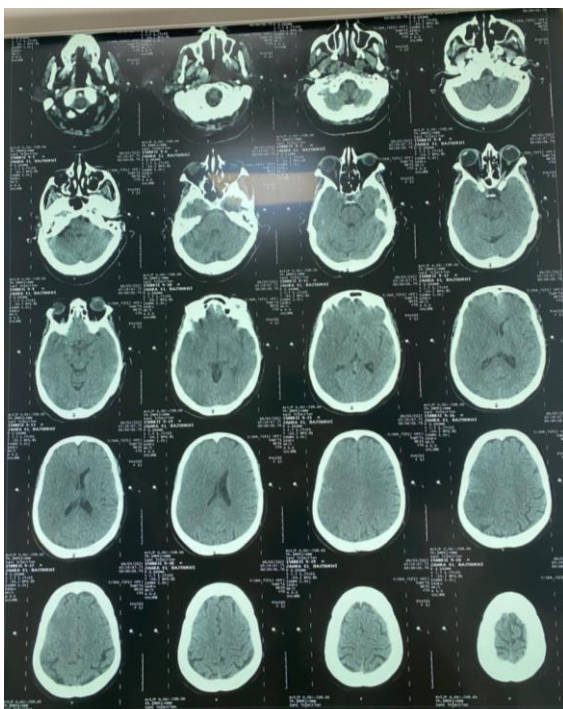


**Figure 2: Electrocardiogram showing an overshift of the Avr and undershift in the lateral and inferior leads**

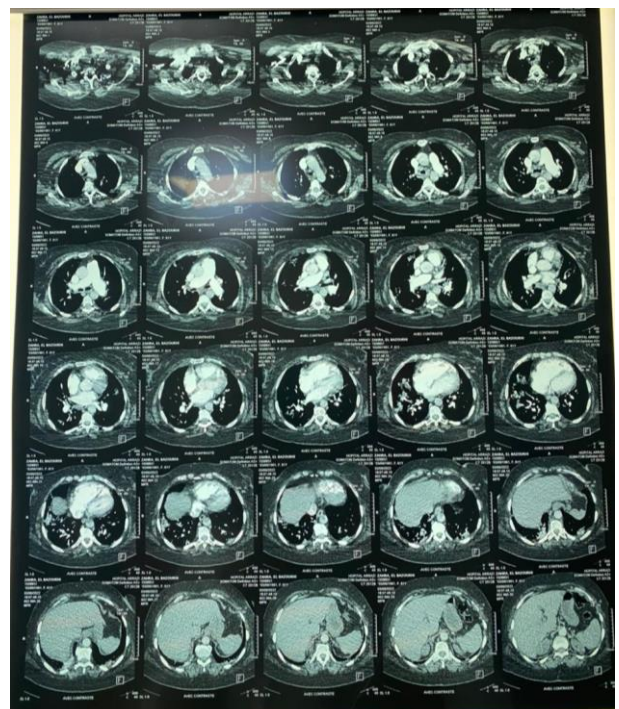
His biological assessment revealed acute renal injury: serum creatinine 35.8mg/l, glomerular filtration rate 13ml/min, her blood count showed a significant thrombocytosis: 1020G/L.

An emergent thoracic angioscan was performed showing pulmonary embolism of the left and right upper lobar branch with a focus of pulmonary infarction with individualization of an endoluminal thrombus at the level of the descending thoracic aorta estimated at 56% and the left subclavian artery responsible for a partial stenosis (Figure 4 and 5):

Her brain scan revealed an extensive right sylvian ischemic stroke (Figure 3).

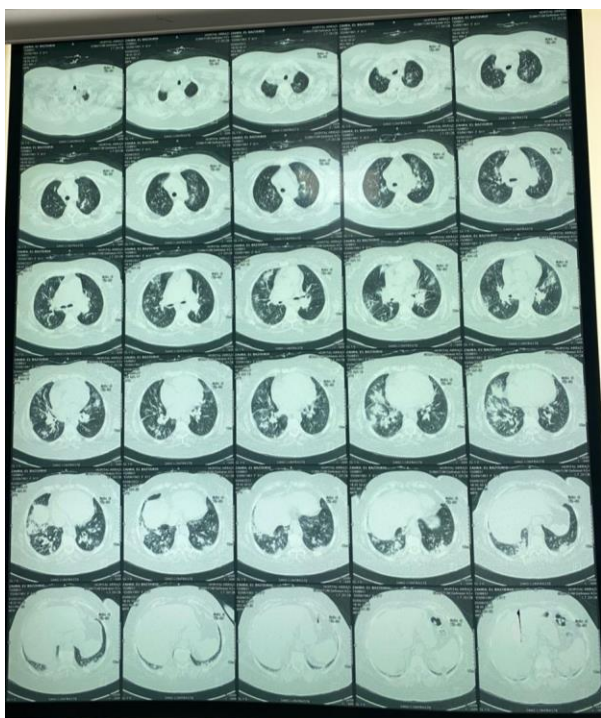


**Figure 3: Cerebral CT scan showing a stroke of the right middle cerebral artery in our patient**



**Figure 4**





**Figure 5**

A trans-thoracic echocardiography was also performed revealing a left atrium of borderline size with a hyperechoic image adjacent to the inter-atrial septum and with a wide implantation base, making a thrombus suspected. The right ventricle was dilated in longitudinal systolic dysfunction.

In this context, a surgical intervention was excluded because of the high operative risk in this patient and then she was referred to an intensive care unit for continuity of care where she benefited from an osteomedullary biopsy to explore the thrombocytosis that she presented.

Unfortunately, the patient died within 24 hours.

The results of the bone marrow biopsy showed after her death: a hyperplastic marrow rich in megakaryocytes probably related to an essential thrombocythemia and confirmed by molecular analysis which showed the presence of the V617F mutation of the JAK2 gene.

## DISCUSSION

This case report describes a 63-year-old woman who suffered multiple thromboses that required intensive care and whose etiology turned out to be essential thrombocythemia.

Essential thrombocythemia is an entity that is not well known to cardiologists.

It is a myeloproliferative syndrome whose diagnostic criteria have changed profoundly and whose management, with regard to thrombotic risk, is still in progress [1].

However, in recent years, a number of studies, albeit single-center and small in number, have attempted to provide a better understanding of this risk. The complications most frequently found are thrombosis, which preferentially affects the arterial territory [2].

These thrombotic manifestations are more frequent and often more serious than the hemorrhagic manifestations and may also be a mode of entry into the disease and allow its diagnosis, as in the case of our patient [2].

Thrombosis occurs preferentially in arterial (2 to 3 times more) than venous territories. For example, a study of 1638 patients found the following locations: stroke (39%), acute coronary syndromes (21%), peripheral arterial thrombosis (6%), splanchnic artery thrombosis (2%), splenic artery thrombosis (1%), or central retinal artery thrombosis (1%). Venous events manifested as deep venous thrombosis/pulmonary embolism (18%), superficial venous (5%), portal and mesenteric veins (6%), hepatic veins (1%), cerebral (1%), or retinal (1%) [3].

Two major risk factors for thrombosis have been confirmed by prospective studies and are the basis of current treatment recommendations [4]: age over 60 years and a history of thrombotic events. More recently, numerous risk factors have been studied in retrospective series, including cardiovascular risk factors, leukocytosis (at diagnosis or its evolution [5], mutation status [6] and hereditary thrombophilia.

For essential thrombocythemia, the elements that are still of value in multivariate studies have been combined in a proposed score, called "IPSET thrombosis" (International Prognostic Score for Essential Thrombocythemia [7].

This score takes into account the two major recognized risk factors, age over 60 years and history of thrombotic events, but also the presence of the JAK2V617F mutation and cardiovascular risk factors (smoking, hypertension and diabetes). It stratifies risk into 3 categories: low (total score = 0-1), intermediate (total score = 2), and high (total score  $\geq$  3) associated with incidences of thrombosis of 0.5% to 1.19%, 1.76% to 2.35%, and 2.28% to 4.88% events/year, respectively.

The pathophysiology of thrombosis is complex and multifactorial, involving different players such as blood cells, endothelium, and flow conditions. Erythrocytes show quantitative and qualitative changes.

The high hematocrit, linked to the erythrocyte proliferation found in essential thrombocythemia, causes an increase in viscosity and a decrease in flow, resulting in venous stasis responsible for a propensity to thrombosis, particularly venous thrombosis (Virchow's triad: stasis, hypercoagulability, alterations in the endothelium) In arteries, which are high-flow vessels, this increase in hematocrit modifies the axial distribution of erythrocytes and platelets: platelets move towards the periphery of the vessel, which reinforces their interaction with endothelial cells, facilitating platelet adhesion and aggregation [8]. Furthermore, in addition to the quantitative change in erythrocytes, qualitative changes are also found: ET erythrocytes with a JAK2 mutation express a phosphorylated Lu/BCAM antigen.

Phosphorylation of this adhesion molecule by JAK2 increases its binding to laminin of endothelial cells, resulting in adhesion of erythrocytes to the endothelium [9].

In this context of JAK2 mutation, other modifications of platelets have been demonstrated such as increased expression of tissue factor, a major pathway of coagulation activation, or the propensity to form circulating leukoplaketar complexes [10]. These leukoplaketar complexes, which appear to be more frequent in patients with thrombosis [11], may be related to changes in platelets, but also in leukocytes that probably play a major role in thrombosis.

Regarding treatment, patients with essential thrombocythemia have a treatment that classically combines Aspegic with cytoreductive therapy [12].

Unfortunately our patient did not benefit from adequate therapeutic management given her rapidly fatal course and diagnosis of essential thrombocythemia was made post mortem.

## CONCLUSION

This case report reminds us that essential thrombocythemia is a diagnosis to be considered in the presence of multiple arterial and venous thromboses, especially since the patient had no other cardiovascular risk factor [13].

This remains a rare situation, the management of which depends on multidisciplinary collaboration.

## BIBLIOGRAPHY

1. Michiels, J. J., & Juvonen, E. (1997, August). Proposal for revised diagnostic criteria of essential thrombocythemia and polycythemia vera by the Thrombocythemia Vera Study Group. In *Seminars in thrombosis and hemostasis* (Vol. 23, No. 04, pp. 339-347). Copyright© 1997 by Thieme Medical Publishers, Inc..
2. Elliott, M. A., & Tefferi, A. (2005). Thrombosis and haemorrhage in polycythaemia vera and essential thrombocythaemia. *British journal of haematology*, 128(3), 275-290.
3. Hultcrantz, M., Björkholm, M., Dickman, P. W., Landgren, O., Derolf, Å. R., Kristinsson, S. Y., & Andersson, T. M. (2018). Risk for arterial and venous thrombosis in patients with myeloproliferative neoplasms: a population-based cohort study. *Annals of internal medicine*, 168(5), 317-325.
4. Cortelazzo, S., Viero, P., Finazzi, G. A. D. E., D'Emilio, A., Rodeghiero, F., & Barbui, T. (1990). Incidence and risk factors for thrombotic complications in a historical cohort of 100 patients with essential thrombocythemia. *Journal of Clinical Oncology*, 8(3), 556-562.
5. Passamonti, F., Rumi, E., Pascutto, C., Cazzola, M., & Lazzarino, M. (2009). Increase in leukocyte count over time predicts thrombosis in patients with low-risk essential thrombocythemia. *Journal of Thrombosis and Haemostasis*, 7(9), 1587-1589.
6. Campbell, P. J., Scott, L. M., Buck, G., Wheatley, K., East, C. L., Marsden, J. T., ... & Medical Research Council Adult Leukaemia Working Party. (2005). Definition of subtypes of essential thrombocythaemia and relation to polycythaemia vera based on JAK2 V617F mutation status: a prospective study. *The Lancet*, 366(9501), 1945-1953.
7. Barbui, T., Finazzi, G., Carobbio, A., Thiele, J., Passamonti, F., Rumi, E., ... & Tefferi, A. (2012). Development and validation of an International Prognostic Score of thrombosis in World Health Organization-essential thrombocythemia (IPSET-thrombosis). *Blood, The Journal of the American Society of Hematology*, 120(26), 5128-5133.
8. Wautier, M. P., El Nemer, W., Gane, P., Rain, J. D., Cartron, J. P., Colin, Y., ... & Wautier, J. L. (2007). Increased adhesion to endothelial cells of erythrocytes from patients with polycythemia vera is mediated by laminin  $\alpha 5$  chain and Lu/BCAM. *Blood, The Journal of the American Society of Hematology*, 110(3), 894-901.
9. De Grandis, M., Cambot, M., Wautier, M. P., Cassinat, B., Chomienne, C., Colin, Y., ... & El Nemer, W. (2013). JAK2V617F activates Lu/BCAM-mediated red cell adhesion in polycythemia vera through an EpoR-independent Rap1/Akt pathway. *Blood, The Journal of the American Society of Hematology*, 121(4), 658-665.
10. Landolfi, R., Ciabattini, G., Patrignani, P., Castellana, M. A., Pogliani, E., Bizzi, B., & Patrono, C. (1992). Increased thromboxane biosynthesis in patients with polycythemia vera: evidence for aspirin-suppressible platelet activation in vivo [see comments]. *Blood*, 80(8), 1965-1971.
11. Hobbs, C. M., Manning, H., Bennett, C., Vasquez, L., Severin, S., Brain, L., ... & Ghevaert, C. (2013). JAK2V617F leads to intrinsic changes in platelet

- formation and reactivity in a knock-in mouse model of essential thrombocythemia. *Blood, The Journal of the American Society of Hematology*, 122(23), 3787-3797.
12. Falanga, A., Marchetti, M., Vignoli, A., Balducci, D., Russo, L., Guerini, V., & Barbui, T. (2007). V617F JAK-2 mutation in patients with essential thrombocythemia: relation to platelet, granulocyte, and plasma hemostatic and inflammatory molecules. *Experimental hematology*, 35(5), 702-711.
  13. Jensen, M. K., de Nully Brown, P., Lund, B. V., Nielsen, O. J., & Hasselbalch, H. C. (2001). Increased circulating platelet-leukocyte aggregates in myeloproliferative disorders is correlated to previous thrombosis, platelet activation and platelet count. *European journal of haematology*, 66(3), 143-151.