

## Pyogenic Granuloma Case Report- Surgical Excision with Diode Laser

Dr. Shashirekha A MDS<sup>1\*</sup>, Dr. Tejaswi Ch MDS<sup>2</sup>

<sup>1</sup>Associate Professor, Dept. Periodontology and Oral Implantology, SBDC, Moinabad, <sup>2</sup>Assistant Professor, Nanded Rural Dental College and Research Centre, Nanded, Maharashtra, India

DOI: [10.36347/sjmcr.2020.v08i01.013](https://doi.org/10.36347/sjmcr.2020.v08i01.013)

| Received: 04.01.2020 | Accepted: 11.01.2020 | Published: 18.01.2020

\*Corresponding author: Dr. Shashirekha A

### Abstract

### Case Report

Pyogenic granuloma (PG) is a kind of inflammatory hyperplasia in response to chronic irritation. It can occur at any age. The hypothetical etiologies include trauma, viral or hormonal factors. Gingiva is the most common site affected followed by buccal mucosa, tongue and lips. Pyogenic granuloma in general, does not occur when excised along with the base and its causative factors. The diode laser is our treatment of choice for pyogenic granuloma as it provides less bleeding than the other modalities.

**Keywords:** Pyogenic granuloma, Diode Laser, Surgical excision.

**Copyright © 2020:** This is an open-access article distributed under the terms of the Creative Commons Attribution license which permits unrestricted use, distribution, and reproduction in any medium for non-commercial use (NonCommercial, or CC-BY-NC) provided the original author and source are credited.

## INTRODUCTION

Pyogenic granuloma is a commonly occurring reactive lesion of the oral cavity. It is non-neoplastic in nature and is hence referred to as a tumour-like lesion [1]. The term “pyogenic granuloma” was coined by Hartzell in 1904 and is still being used to denote this lesion [2]. But this terminology is confusing since neither it is due to bacterial infection nor does it produce any pus. Also, histopathologically there is no granuloma formation [3]. In oral cavity, it represents up to 7% of the diagnosed lesions [4]. Pyogenic granuloma involves the gingiva most frequently and presents as a nodular growth which may be slow growing or rapid in nature [1, 5]. Low-grade chronic irritation, trauma, and hormonal imbalances are said to be the main etiology for pyogenic granuloma which results in the overzealous proliferation of vascular type of connective tissue [1, 3, 7]. Poor oral hygiene leading to accumulation of plaque and calculus and overhanging restorations are said to be the most common precipitating factors [7]. Other etiological agents include use of certain immunosuppressive drugs and oral contraceptives. Nonspecific bacterial infection is thought to be a secondary involvement rather than being the main etiology of this lesion [8]. The colour of the lesion also varies and is dependent on the vascularity of the lesion in relation to its clinical course [6].

## CASE REPORT

A 20-year-old female was to the came to the department of periodontics, Kamineni institute of dental

sciences, Narketpally, Telangana, with a complaint of gingival overgrowth and bleeding in lower right region of the jaw. Macroscopic appearance of this lesion was a pedunculated mass in the interproximal region of 42 and 43 extended on entire labial aspect of respective teeth, which appeared almost round in shape. It was reddish pink covered by cream-colored mucosa. The surface was uneven with shallow grooves in some areas. The lesion was approximately 10 mm × 8 mm in diameters and 5 mm in thickness with relatively soft consistency (Figure 1).

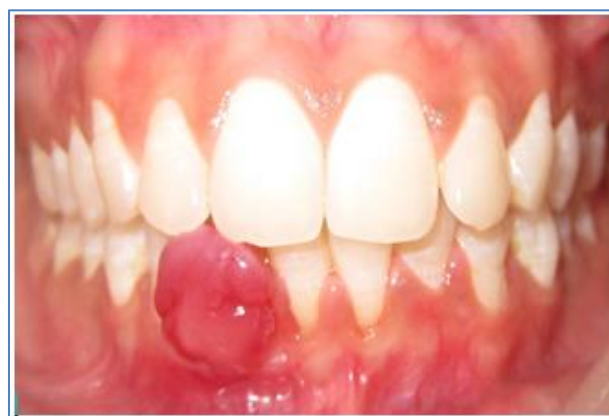
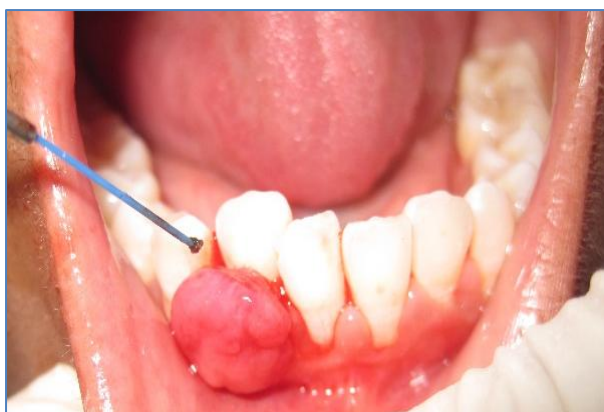
Fig-1: Pyogenic granuloma irt 42 and 43

Excisional biopsy was carried out with diode laser (DenLase; China Daheng Group, Inc. Beijing, China) (Figure 2).



**Fig-2: Excision of the lesion with laser**

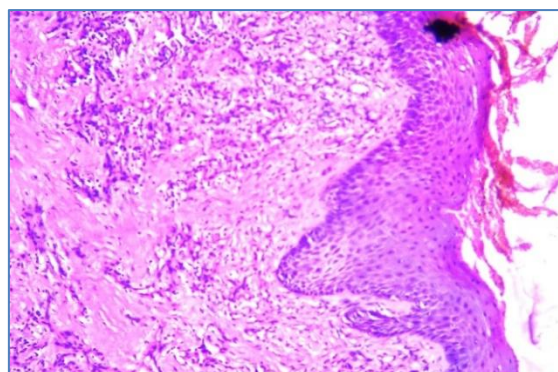
The laser device is classified as Class 4 laser system, especially designed safety glasses were provided to the patient, operator, and dental assistant for protection of the eyes from the laser beam. Oral hygiene instructions were reinforced after the treatment. An elliptical incision was made around the peduncle, and then the lesion was lifted along with the underlying periosteum from the bone surface and removed until soft tissue were eliminated.

In order to prevent recurrence, up to the surrounding tissue was cleaned by laser and also up to 2mm of the safe margin of the lesion was removed. Haemostasis was achieved with the same laser and healing was obtained for second intention. After the surgery, coe-pak (GC America, USA) was placed on the area. Chlorhexidine mouthwash (0.2%) was also prescribed for the patient.

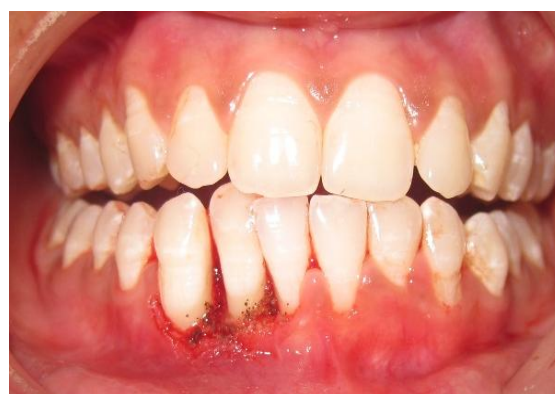Excised specimen was preserved and the sample was placed in 10% formalin and then sent for histopathological examination.

## HISTOPATHOLOGIC FINDINGS

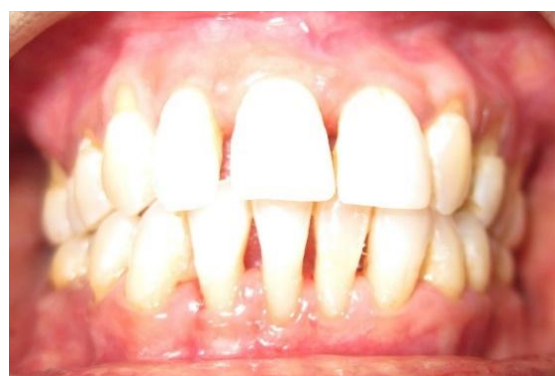For histopathological evaluation, H & E staining was carried out. Microscopic examination of sections prepared from the sample shows acanthotic and atrophic Para keratinized stratified squamous epithelium of oral mucosa and in some areas ulceration was seen with fibrino-leukocytic membrane where in the surface, epithelium had Plasma pooling areas. Supportive fibrovascular connective tissue with numerous blood vessels in various sizes with plump endothelial cells. Mild to moderate infiltration of acute and chronic inflammatory cells was evident in the whole sample (Figures 3). This Histopathologic view confirmed the diagnosis of pyogenic granuloma. The immediate post-operative view shows the surgical site is devoid of bleeding which can lead to healthy with successful healing (Figure 4). Furthermore full recovery was achieved within three months (Figure 5). After the surgery the patient was asked about the level of pain and as there was no pain the patient was very pleased.



**Fig-3: Histopathologic picture**



**Fig-4: Immediate post- operative view**



**Fig-5: Post - operative view after 3 months**

## DISCUSSION

Surgical excision is the treatment of choice. After surgical excision of gingival lesions, curettage of underlying tissue is recommended [9]. Excision with 2 mm margins at its clinical periphery and to a depth to the periosteum or to the causative agent. Nevertheless, prognosis for intra-oral pyogenic granulomas is good. Satisfactory outcome has been reported with Laser therapy [10] and Cryosurgery [11] for oral pyogenic granulomas.

## REFERENCES

1. Gomes SR, Shakir QJ, Thaker PV, Tavadia JK. Pyogenic granuloma of the gingiva: A misnomer?— A case report and review of literature. Journal of indian society of periodontology. 2013 Jul;17(4):514.

2. M.E.Hartzell, "Granulomapyogenicum," *Journal of cutaneous diseases including syphilis*. 1994; 22; 520–525.
3. Kamal R, Dahiya P, Puri A. Oral pyogenic granuloma: Various concepts of etiopathogenesis. *Journal of oral and maxillofacial pathology: JOMFP*. 2012 Jan;16(1):79.
4. Lawoyin JO, Arotiba JT, Dosumu OO. Oral pyogenic granuloma: a review of 38 cases from Ibadan, Nigeria. *British journal of oral and maxillofacial surgery*. 1997 Jun 1;35(3):185-9.
5. Jafarzadeh H, Sanatkhan M, Mohtasham N. Oral pyogenic granuloma: a review. *Journal of oral science*. 2006;48(4):167-75.
6. Sachdeva SK. Extralingival pyogenic granuloma: an unusual clinical presentation. *Journal of Dentistry*. 2015 Sep;16(3 Suppl):282.
7. Con Gran TA, del Hueso P. Aggressive pregnancy tumor (pyogenic granuloma) with extensive alveolar bone loss mimicking a malignant tumor: case report and review of literature. *Int. j. morphol*. 2011;29(1):164-7.
8. Vilmann A, Vilmann P, Vilmann H. Pyogenic granuloma: evaluation of oral conditions. *British journal of oral and maxillofacial surgery*. 1986 Oct 1;24(5):376-82.
9. Patil K, Mahima VG, Lahari K. Extra gingival pyogenic granuloma. *Indian J Dent Res*. 2006;17:199–202.
10. White JM, Chaudhry SI, Kudler JJ, Sekandari N, Schoelch ML, Silverman S Nd: YAG and CO2 laser therapy of oral mucosal lesions. *J Clin Laser Med Surg*. 1998 Dec;16(6): 299– 304.
11. Ishida CE, Ramos-e-Silva M. Cryosurgery in oral lesions. *Int J Dermatol*. 1998 Apr;37(4):283– 5.