

Verrucous Carcinoma of Foot: Locally Aggressive Well Differentiated Tumour with Unusual Presentation

Dr. Kuladeepa Ananda Vaidya^{1*}, Dr. Ramachandra², Dr. Medha Shankarling³, Dr. Ramachandra Badami⁴, Dr. Vishwanath Puttanna⁵, Dr. Umapathi Choudary⁶

¹Assistant professor, Department of pathology, Srinivas Institute of medical science and research centre, Mukka, Mangalore.575021

²Professor & HOD, Department of orthopaedics, Srinivas Institute of medical science and research centre, Mukka, Mangalore.575021

³Assistant professor, Department of pathology, Srinivas Institute of medical science and research centre, Mukka, Mangalore.575021

⁴Senior resident, Department of orthopaedics, Srinivas Institute of medical science and research centre, Mukka, Mangalore.575021

⁵Senior resident, Department of orthopaedics, Srinivas Institute of medical science and research centre, Mukka, Mangalore.575021

⁶Senior resident, Department of orthopaedics, Srinivas Institute of medical science and research centre, Mukka, Mangalore.575021

*Corresponding Author's Email: vaidyakuldeep@gmail.com

Abstract: Verrucous carcinoma is a rare, locally invasive, well differentiated, low-grade squamous cell carcinoma. It follows a chronic course and mimics a variety of skin lesions and delaying diagnosis. There are scanty references about this tumour in the literature arising from dorsum of foot in post leprotic lesion of skin. We here with present a case of verrucous carcinoma arising from dorsum of foot in a 60year old patient with past history of leprosy. We are presenting this case because of its rarity and atypical presentation.

Keywords: Verrucous carcinoma, squamous cell carcinoma, tumour

INTRODUCTION

The term verrucous carcinoma (VC) was first coined in 1948 by Ackerman. Three major locations of verrucous carcinoma are oral cavity (oral florid papillomatosis), anogenital region (giant condyloma of Buschke and Lowenstein), and plantar surface of foot (epithelioma cuniculatum) [1]. In 1954, Aird, et al reported three cases of a previously un described, fungating, low-grade carcinoma occurring on the sole of the foot to which they gave the name epithelioma cuniculatum [2]. VC typically occurs in men in their 4th to 6th decades, although it has been seen in patients as young as 16 years [3]. Verrucous carcinoma can invade deeper tissues and rarely to bone [4].

CASE REPORT

A 60year old man presented with a large, fungating lesion on the dorsal aspect of his left forefoot. The lesion had been present for 2 years and was gradually increasing in size. On examination the exophytic, cauliflower type of lesion measuring 7x4.5x4cm, was seen extending to the proximal aspect of lateral four toes, disfiguring the normal anatomy of foot [Fig1]. Growth was non tender to touch, with indurated border, rimmed by old scar and puckering of skin. Surface was showing focal ulceration with exuding foul-smelling material. Plantar surface of fore foot was showing an irregular trophic ulcer m/s

5.5x3.5cm with indurated base extending up to the dorsolateral aspect of fore foot. The patient was a chronic smoker but non diabetic. He had history of leprosy 15 yrs ago and taken irregular treatment for the same. Radiographs of the foot showed leprosy associated osteolysis and absorption of terminal phalanges and part of metatarsals. Arterial Doppler of left lower limb showed atherosclerotic changes of tibial artery. Probable clinical diagnosis of deep fungal infection was thought of and differential diagnosis of skin tumor was rendered. Biopsy was taken and sent for histopathological examination, which turned out to be of verrucous carcinoma. Sample for fungal culture and special stains for fungus on tissue sections were negative for fungal elements.

Symes amputation was performed considering the size, extent of tumor and other preexisting chronic trophic ulcer, deformities of toes secondary to leprosy. Patient sustained the procedure well and post-operative period was uneventful. Amputated foot was fixed in 10% formalin and sent for thorough pathological evaluation. Histopathological sections studied from the verrucous growth showed stratified squamous epithelium with marked hyperkeratosis, papillomatosis, acanthosis, irregular elongation of the rete ridges with pushing type of invasion and bulbous proliferation of well-differentiated keratinocytes. Epithelium showed

mild dysplasia with focal dyskeratosis, mounds of parakeratosis and epithelial pearl formation [Fig2]. Sub epithelial stroma was fibrocollagenous with focal lymphocytic infiltration. Sections from the ulcer edge showed nonspecific chronic inflammatory changes. Resected margin and bones were devoid of tumor cells.

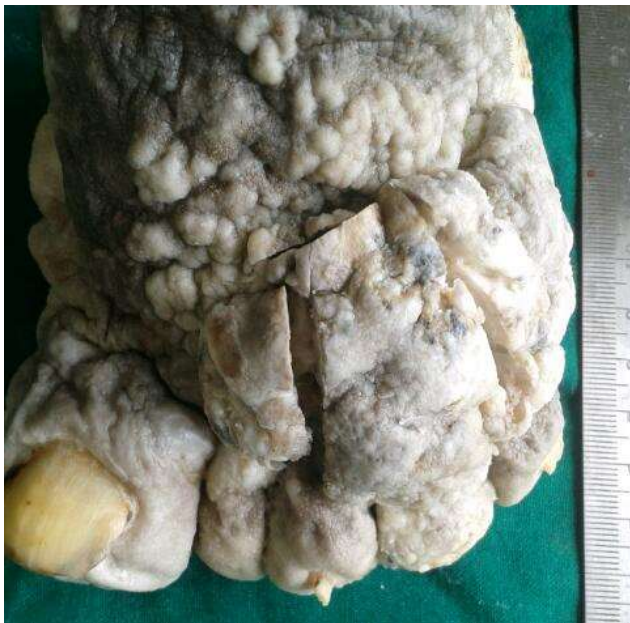

Fig 1: Gross: Verrucous, cauliflower like growth on dorsum of foot

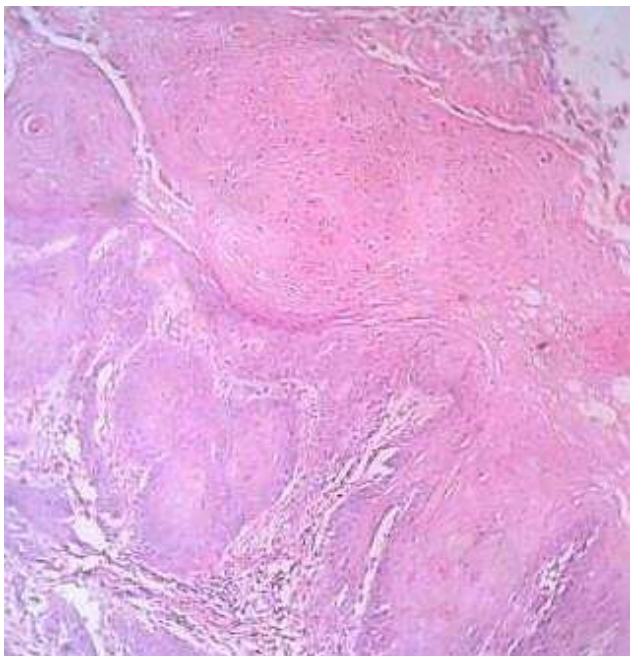


Fig 2: Microscopy: Epithelium with marked hyperkeratosis, acanthosis irregular elongation of the rete ridges with pushing type of invasion and bulbous proliferation of well-differentiated keratinocytes

DISCUSSION

Verrucous carcinoma is a slow-growing lesion that is most often found on the weight bearing surface of the foot [4], but as an exception, in our case the tumour was arising from the dorsum of foot. This tumour is an uncommon, well-differentiated variant of squamous cell carcinoma that is regarded as a low grade locally invasive malignant tumour with rare potential for distant metastasis. Verrucous carcinoma is usually seen in sites like oral cavity, anogenital region, and plantar surface of foot [5]. Human papilloma virus has been implicated in the pathogenesis of verrucous carcinoma; however, its role is controversial [6]. VC are known to arise in chronic ulcers, in skin after radiation therapy, old scars and rarely in the amputation stump. In our case growth has arisen from pre-existing lesion and scar tissue produced from old leprosy [5]. It should be considered in the differential diagnosis for all chronic nonhealing wounds [4].

The cardinal manifestation of this disease is a fungating, exophytic mass with numerous keratin-filled sinuses [1]. As the tumour grows, it invades locally and has been shown to involve the plantar fascia or to advance toward the dorsal surface of the foot, with destruction of the metatarsal bones [7], in our case the tumor originated from dorsum of foot and extended gradually towards lateral and plantar aspect infiltrating deep muscles and fascia. Exophytic tumours with ulceration and sinuses draining foul smelling discharge cause pain, bleeding, and difficulty in walking. Multiple biopsy specimens are often necessary to establish the diagnosis. The slow growth and confusing early stage appearances can lead to delays in diagnosis as occurred in our case [8,9].

Histologic diagnosis of VC can be difficult sometime. A deep biopsy specimen of the lesion is necessary, as superficial portions may resemble a verruca vulgaris with hyperkeratosis, parakeratosis and acanthosis [7]. Microscopically the epithelium shows little atypia and is characterized by well-differentiated, lightly staining, and benign-appearing keratinocytes [6]. Verruca vulgaris, deep mycosis, reactive epidermal hyperplasia, dermatofibroma, benign adnexal tumour, giant seborrheic keratosis, and cutaneous squamous cell carcinoma with verrucoid clinical features are some of the differential diagnosis for verrucous carcinoma [9].

The treatment is wide local excision. In more severe cases, amputation of a toe or even a foot has been described [9,10]. Studies suggest that multiple therapies exist and recurrence does occur; however, this is less likely with wide excision and more so with Mohs surgery. With a high clinical suspicion and thorough histopathologic exam, bone involvement and amputation may be avoided [4].

CONCLUSION

Verrucous carcinoma arising from dorsum of foot occurring in post leprotic skin lesion is a rare phenomenon. The slow growth, uncommon sites like dorsum of foot and confusing early stage appearances can lead to delays in diagnosis.

REFERENCES

1. Ho J, Diven DG, Butler PJ, Tying SK; An ulcerating verrucous plaque on the foot. Arch Dermatol., 2000; 136:550–551.
2. Aird I, Johnson HD, Lennox B, Stansfeld A G; Epithelioma cuniculatum: a variety of squamous carcinoma peculiar to the foot. Br. J. Surg, 1954; 42: 245-250.
3. Brownstein MH, Shapiro L; Verrucous carcinoma of skin: epithelioma cuniculatum plantare. Cancer, 1976; 38:1710–1716.
4. Penea KE, Manji KA, Craig AB, Grootegoed RA, Leaming TR, Wirth GA; Atypical Presentation of Verrucous Carcinoma A Case Study and Review of the Literature. Foot Ankle Spec, 2013;6(4):318-322.
5. Sarma D, Hansen TP, Adickes ED; Carcinoma arising in the leg amputation stump. The Internet Journal of Dermatology, 2006; 4(1).
6. Noel JC, Peny MO, Goldschmidt D, Verhest A, Heenen M, De Dobbeleer G; Human papillomavirus type 1 DNA in verrucous carcinoma of the leg. J Am Acad Dermatol, 1993; 29:1036–1038.
7. Kathuria S, Rieker J, Jablkow VR, Van den Broek H; Plantar verrucous carcinoma (epithelioma cuniculatum): case report with review of the literature. J Surg Oncol, 1986; 31(1):71–75.
8. Lesic A, Nikolic M, Sopta J, Starcevic B, Bumbasirevic M, Atkinson, Atkinson HDE; Verrucous carcinoma of the foot: a case report. Journal of Orthopaedic Surgery, 2008;16(2):251-3
9. Schein O, Orenstein A, Bar-Meir E; Plantar Verrucous Carcinoma (Epithelioma Cuniculatum): Rare Form of the Common Wart. IMAJ, 2006;8:885
10. Zielonda E, Goldschmidt D, Fontaine S; Verrucous carcinoma or epithelioma cuniculatum plantae. Eur J Surg Oncol, 1997; 23:86–87.