

Management of Acute Postoperative Bilateral Vocal Cords Paralysis after Surgical Resection of Posterior Fossa Tumor (Case Report)

Linda El Allani^{1*}, Oussama El Ammari¹, Ali Derkaoui¹, Brahim Bechri¹, Abdelkarim Shimi¹, Mohammed Khatouf¹

¹Department of Anesthesiology and Intensive Care A1, Hassan II Academic Hospital, Fez, Morocco

DOI: [10.36347/sjmcr.2022.v10i09.013](https://doi.org/10.36347/sjmcr.2022.v10i09.013)

| Received: 11.08.2022 | Accepted: 08.09.2022 | Published: 16.09.2022

*Corresponding author: Linda El Allani

Department of Anesthesiology and Intensive Care A1, Hassan II Academic Hospital, Fez, Morocco

Abstract

Case Report

Bilateral vocal cords paralysis is a serious condition that can be due to pathology of the vocal fold itself, damage to the cranial nerves ensuring their mobility, or central neurological disorders. In this article, we present a case of a 13-year-old girl who was admitted to the intensive care unit postoperatively for posterior cerebral fossa tumor surgery. She was reintubated after an extubation failure as a result of laryngeal dyspnea with stridor and chest in-drawing. The examination revealed damage to III, VI, and IX nerves with the immobility of vocal cords that were abducted towards the midline. A weaning tracheotomy was performed with a good clinical evolution and the patient was discharged 13 days after the surgery with maintained follow-ups. We report this case for its rarity.

Keywords: Bilateral; Vocal cords; Paralysis; Posterior fossa tumor; Surgery; Laryngeal dyspnea.

Copyright © 2022 The Author(s): This is an open-access article distributed under the terms of the Creative Commons Attribution 4.0 International License (CC BY-NC 4.0) which permits unrestricted use, distribution, and reproduction in any medium for non-commercial use provided the original author and source are credited.

INTRODUCTION

The vocal cords have three main functions: Breathing, creating vocal sounds voice, and protecting the lower airways during swallowing.

Bilateral immobility of the vocal cords depending on their position can be manifested by severe dyspnea which can be life-threatening, dysphonia, or swallowing disorders [1]. It is a rare condition but difficult to manage due to the significant morbidity it can generate [2].

PATIENT AND OBSERVATION

A 13-year-old girl with uneventful medical history was presented to the emergency department of the University Hospital Center Hassan II of Fez with a five months history of intra-cranial hypertension syndrome. On examination, the patient was conscious, hemodynamically, and respiratory stable. The neurologic examination revealed a static and kinetic cerebellar syndrome. Other exams were normal with a correct biological assessment.

Computed tomography (CT) scan of the head followed by cerebral Magnetic resonance imaging (MRI) with and without contrast were realized

revealing a well-circumscribed midline mass in the posterior fossa arising from the vermis (Medulloblastoma) with active quadri-ventricular hydrocephalus (Figure 1). According to the MRI findings and clinical symptoms, an Endoscopic third ventriculocisternostomy (ETV) was performed.

The patient underwent a gross total tumor resection within two weeks of the ETV, using an occipital craniotomy approach. Postoperatively, she was admitted to the intensive care unit for monitoring of vital signs and analgesia.

After extubation, the patient presented laryngeal dyspnea with stridor and chest in-drawing. Neurological examination showed the absence of the photopupillary and gag reflexes with lateral rectus muscle loss due to damage to the sixth cranial nerve. The patient was managed with intravenous corticosteroid and inhaled epinephrine without improvement.

Before reintubation, the patient was examined with flexible fiberoptic laryngoscopy objectifying the immobility of the vocal cords that were abducted towards the midline (Figure 2). Then, the diagnosis of bilateral vocal fold paralysis was made clinically after

Citation: Linda El Allani, Oussama El Ammari, Ali Derkaoui, Brahim Bechri, Abdelkarim Shimi, Mohammed Khatouf. Management of Acute Postoperative Bilateral Vocal Cords Paralysis after Surgical Resection of Posterior Fossa Tumor (Case Report). Sch J Med Case Rep, 2022 Sept 10(9): 911-914.

the elimination of other pathologies such as laryngeal edema or subglottic stenosis. The patient was percutaneously tracheostomized after the realization of

a control brain CT scan which did not objectify obvious postoperative anomalies (Figure 2).

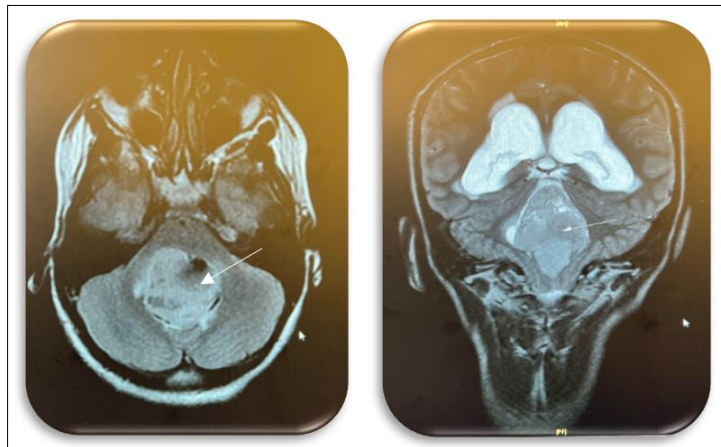


Figure 1: The axial Flair and coronal T2 phases of the magnetic resonance imaging revealing a tumor in the posterior fossa arising from the vermis (white arrow) causing extensive hydrocephalus

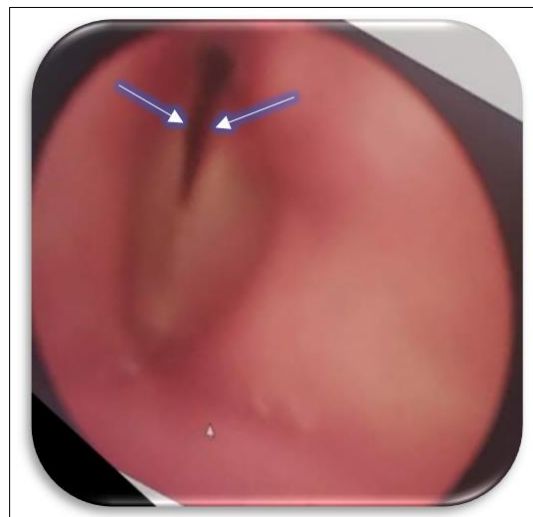


Figure 2: Transnasal fiberoptic laryngoscopy view showing adducting vocal cords.

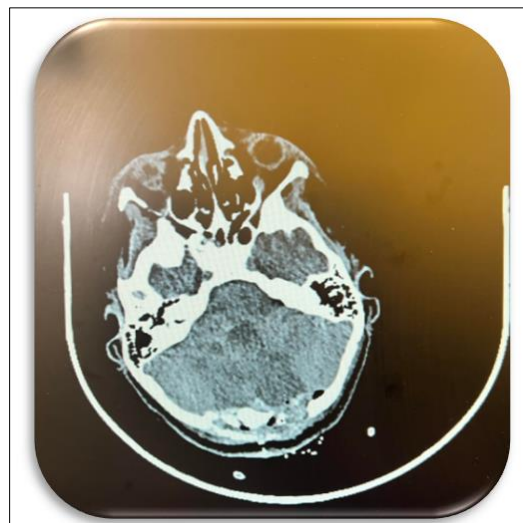


Figure 3: Non-contrast brain CT scan showing Postoperative minimal oedema

The patient's evolution was marked by the occurrence of a large right pneumothorax associated with cervical subcutaneous emphysema. Thoracic drainage was performed (Figure 4 a-b) with a good clinical and radiological evolution, and then she was

placed in a T-piece. After progressive respiratory weaning, the patient was discharged 13 days after surgery in stable condition. She will be followed up by the neurosurgery department.

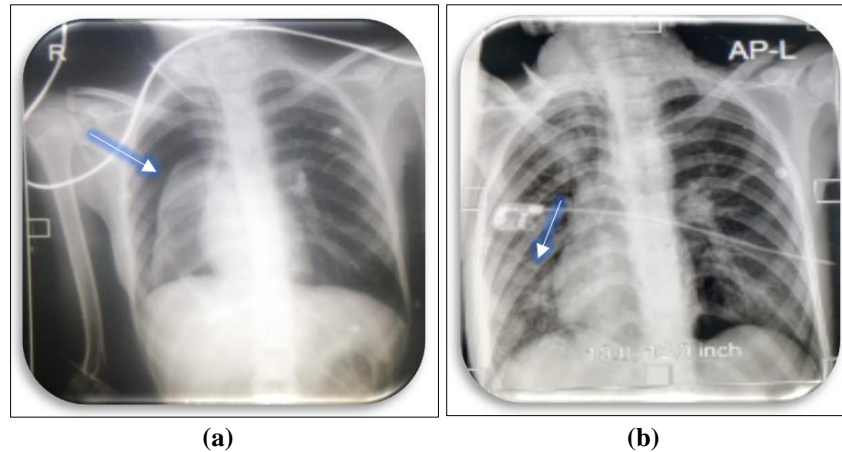


Figure 4: a) Chest X-ray showing large right Pneumothorax, b) Improvement in pneumothorax after thoracic drainage (arrow)

DISCUSSION

The larynx is composed of 3 levels: supraglottic, glottic (vocal cord plane), and subglottic. Laryngeal innervation is provided by 2 branches of the 10th cranial pair or vagus nerve: the superior laryngeal nerve and the recurrent nerve. The cord innervation is mixed: sensitive with the superior laryngeal nerve, and motor with the recurrent nerves [3].

Bilateral vocal cord palsy in adduction is a rare entity, Due to this paralysis, the vocal cords cannot move apart during inspiration, resulting in permanent respiratory distress more important as the residual glottic cleft is smaller [4]. The diagnosis must be suspected of the association between breathing difficulties and voice changes. It will be confirmed by Flexible fiberoptic laryngoscopy [1, 5] which analyzes the mobility and position of the vocal cords (that are in the vast majority of cases in adduction: median or paramedian) and which can be completed by video stroboscopy and bronchoscopy to eliminate other underlying pathologies [5]. Laryngeal electromyography of the vocal cords can also be performed to confirm the neurogenic origin of laryngeal immobility, making the distinction between laryngeal paralysis and cricoarytenoid arthritis [1].

The main causes of bilateral vocal cord paralysis are prolonged intubation and total thyroidectomy [1]. There are also other rarer causes:

Tumoral and vascular pathologies of the central nervous system; post-surgical lesion of the vagus nerves, which we strongly suspect in our patient given the absence of medical and surgical history, the localization of the tumor, the involvement of the other

cranial pairs, and the Flexible fiberoptic laryngoscopy finding; Amyotrophic lateral sclerosis; syphilis, and Systemic disease. There are also idiopathic forms [4, 5].

The therapeutic strategy must be personalized according to the clinical symptomatology and especially the probability of spontaneous recovery which should be considered before any invasive procedure that may have an impact on the patient's functional prognosis. If the patient presents respiratory distress, the initial treatment is represented by tracheostomy (the case of our patient) although it is associated with a decrease in quality of life and can be especially undesirable in the pediatric population [6]. If the paralysis does not regress within a few months allowing decannulation, several surgical techniques are proposed:

Arytenoidectomy (an irreversible endoscopic surgical procedure that allows for an enlargement of the larynx in its transverse axis); Endoscopic laser cordotomy which is preferred to arytenoidectomy but can lead to an alteration in voice quality due to vocal cord lesions [7]; Reinnervation to obtain vocal cord abduction using the phrenic nerve or a pedicled neuromuscular flap from ansa cervicalis. Periodic injections of botulinum toxin can also be proposed for a transient improvement of symptoms until complete recovery [5].

The prognosis depends on the initial cause. Investigations such as laryngeal electromyography of the vocal cords can give predictive value in post-surgical cases to identify the probability of recuperation [5].

CONCLUSION

Bilateral vocal cord paralysis is an uncommon condition that can be life-threatening. Its diagnosis is made by Flexible fiberoptic laryngoscopy, which is the reference examination.

The clinical manifestation depends on the position of the vocal cords. Prolonged intubation and thyroid surgery are the most frequent etiologies.

CONFLICTS OF INTEREST

The authors declare that there is no conflict of interest regarding the publication of this paper.

Patient Consent for Publication

Obtained.

REFERENCES

1. Alexis, D. S. Z., Ulrich, V. B., Ablawa, A. V. M. B., Wassi, A., & Bernadette, Y. V. (2020). Clinical and Paraclinical Aspects of Bilateral Vocal Cord Paralysis. *European Scientific Journal (ESJ)*, 16(15), 212.
2. Brake, M. K., & Anderson, J. (2015). Bilateral vocal fold immobility: a 13 year review of etiologies, management and the utility of the Empey index. *Journal of Otolaryngology-Head & Neck Surgery*, 44(1), 1-7.
3. Soriano, R. M., & Gupta, V. (2022). Anatomy, Head and Neck, Larynx Nerves. [Updated 2021 Jul 26]. In: *Stat Pearls. Treasure Island (FL): Stat Pearls Publishing*.
4. Gentili, ME, Lengrand, D., Bernard, JM, Nicolas, JC, & Guilmin, M. (1991, January). Postoperative bilateral paralysis of the vocal cord abductors and history of subtotal thyroidectomy. In *French Annals of Anesthesia and Resuscitation* (Vol. 10, No. 6, pp. 595-596). Elsevier Masson.
5. Salik, I., & Winters, R. (2022). Bilateral Vocal Cord Paralysis. [Updated 2022 Jul 12]. In: *Stat Pearls. Treasure Island (FL): Stat Pearls Publishing*.
6. Gilony, D., Gilboa, D., Blumstein, T., Murad, H., Talmi, Y. P., Kronenberg, J., & Wolf, M. (2005). Effects of tracheostomy on well-being and body-image perceptions. *Otolaryngology—Head and Neck Surgery*, 133(3), 366-371.
7. Li, Y., Pearce, E. C., Mainthia, R., Athavale, S. M., Dang, J., Ashmead, D. H., ... & Zeale, D. L. (2013). Comparison of ventilation and voice outcomes between unilateral laryngeal pacing and unilateral cordotomy for the treatment of bilateral vocal fold paralysis. *ORL*, 75(2), 68-73.