

First Report of 2q37 Microdeletion Syndrome in Morocco

Hanane Ait hammou¹, Mariam Tajir^{1,2}, Nisrine Aboussair^{1,3*}

¹Department of Genetics, Clinical Research Center, Mohammed VI University Hospital of Marrakech-40000, Morocco

²Faculty of Medicine and Pharmacy, University of Hassan I, Oujda-60000, Morocco

³Faculty of Medicine and Pharmacy, University of Cadi Ayyad, Marrakech-40000, Morocco

DOI: [10.36347/sjmcr.2020.v08i01.025](https://doi.org/10.36347/sjmcr.2020.v08i01.025)

| Received: 01.01.2020 | Accepted: 08.01.2020 | Published: 29.01.2020

*Corresponding author: Nisrine Aboussair

Abstract

Case Report

2q37 microdeletion syndrome or Albright Hereditary Osteodystrophy like (AHO-like), also referred to as AHO3 or Monosomy 2q37qter, is characterized by developmental delay, intellectual disability, brachymetaphalangy of digits 3-5, short stature, obesity, hypotonia, characteristic facial appearance, autism, and skeletal defects. In this work, we report a case of cytogenetically visible de novo deletion of this 2q37 chromosome region, referred to genetic department of Mohammed VI University Hospital of Marrakech and we discuss its clinical features and laboratory tests. R-banding chromosomal analysis was performed for the patient from T lymphocyte cultures in vitro and blocked in metaphase. This technique showed a small terminal deletion of the long arm of chromosome 2 and the karyotype was designated 46, XX, del(2)(pter ---->q37:). Parental karyotypes (R-banding) were also realized, but didn't show any chromosomal abnormality. So, in that case, genetic counseling is reassuring for the future pregnancies. We show through this work the interest of the geneticist in the diagnosis of rare syndromes and appropriate genetic counseling of patient and his family.

Keywords: 2q37 microdeletion; AHO-like; AHO3; monosomy 2q37qter; constitutional karyotype; genetic counseling; Mohammed VI University Hospital of Marrakech.

Copyright @ 2020: This is an open-access article distributed under the terms of the Creative Commons Attribution license which permits unrestricted use, distribution, and reproduction in any medium for non-commercial use (NonCommercial, or CC-BY-NC) provided the original author and source are credited.

INTRODUCTION

2q37 microdeletion syndrome (or AHO-like, AHO3, Monosomy 2q37qter) is characterized by a round face, frontal bossing, flattened mid-face, deep-set eyes, epicanthic folds, anteverted nostrils, hypoplastic alae nasi, brachymetaphalangy of digits 3-5 (often digit 4 alone), minor ear anomalies, short stature and obesity. Hypotonia, and developmental delay are the most common manifestations of this syndrome [1]. Behavior problems are also frequent [2, 3] including hyperactivity, repetitive behavior, in many cases, these manifestations have been characterized as autistic disorders [4]. Other findings include seizures, congenital heart disease, Central Nervous System (CNS) abnormalities (hydrocephalus, dilated ventricles), umbilical/inguinal hernia, tracheomalacia, situs abnormalities, gastrointestinal abnormalities, and renal malformations.

In the present work, we report a case of 2q37 microdeletion syndrome or Albright Hereditary Osteodystrophy like syndrome, referred to Genetic department of Mohammed VI University Hospital of Marrakech and we discuss its clinical features and

laboratory test results to correlate them with results found in the literature. In fact, this is the first report of 2q37 microdeletion syndrome in Morocco.

We show through this work the interest of the geneticist in the diagnosis of rare syndromes and appropriate genetic counseling of patient and his family.

CLINICAL CASE REPORT

The proposita aged one year, the last of two sibling (Fig.1). She was referred to genetic counseling of UTH-Mohammed VI of Marrakech by a pediatrician for facial dysmorphism associated with a delayed motor skills. Physical examination showed a height of 70 cm. Dysmorphology examination revealed a round face, a short nose with a depressed bridge, Mongoloid palpebral slit, hypertelorism, a front saillant, arched eyebrows with synophris, anteverted nostrils, Microstomia and thin lips with a long and a marked philtrum, retrognathia, high-arched palate, hypoplasia of the right ear lobular (Fig.2). The examination of extremities showed brachydactyly of the hands (Fig.3). Radiographic examination of the cavum demonstrated

an imprint adenoid that projects on the posterior wall of the nasopharynx.

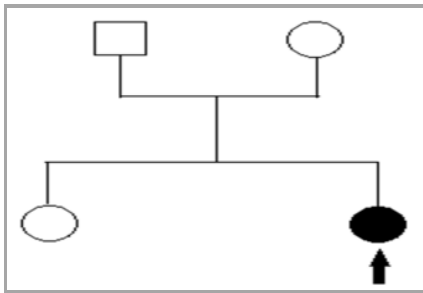


Fig-1: Family pedigree

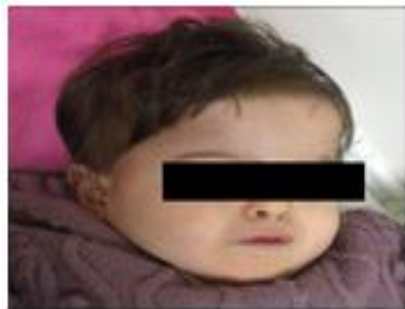

Fig-2: Facial dysmorphia

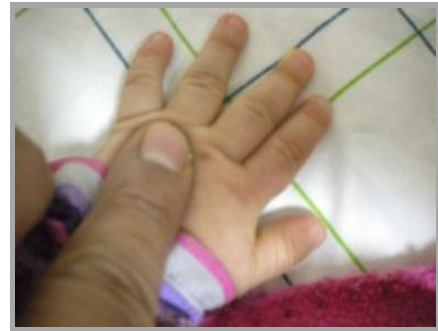

Fig-3: Picture of the hand

CYTOGENETIC STUDY

R-banding chromosomal analysis was performed for the patient from T lymphocyte cultures in vitro and blocked in metaphase. This technique showed a small terminal deletion of the long arm of chromosome 2 (Fig.4) and the karyotype was designated 46,XX,del(2)(pter----q37:). Parental karyotypes (R-banding) were also realized, but didn't show any chromosomal abnormality.

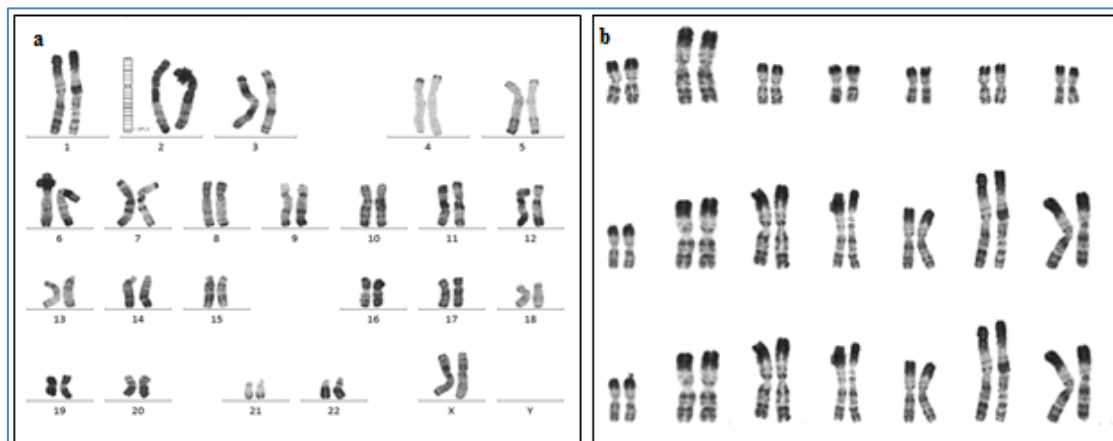


Fig-4: Karyotype of the patient (a), Combined karyotype of chromosome 2 (b)

DISCUSSION

Since 1983, several authors have described small terminal deletion of 2q associated with variable phenotyps [5- 9]. This deletion was visible on prometaphase karyotype in most cases published [10-13, 6, 14].

The clinical feature is characterized by severe facial dysmorphic which combines a round face, thinning hair, a prominent forehead, oblique palpebral fissures down and out, eyes deeply located in orbits, low supplied and arched eyebrows, midface hypoplasia, a depressed nasal bridge, low nose wings, advanced V-shaped nose, a thin upper lip and a high arched palate [1, 6]. In the present work, the patient present variable dysmorphic signs, brachydactyly, short stature and

malformations. These criteria are already described in the clinical feature of the 2q37 deletion.

The dysmorphic features are even more numerous than the deletion is extended [1, 15] studied 5 patients with mental retardation and brachydactyly. He found that four had visible deletions and one had a submicroscopic deletion of 2q37.

Moreover, patients with 2q37 terminal deletion may have a small size in 23% and obesity. Malformations are also present (in 30% of patients) [16].

Generally, the variability of the clinical feature depends on the genes involved. According to the study

of [17], five genes are involved in AHO-like due to the deletion 2q37 especially; STK25, KIF1A and HDAC4. Moreover [18] are proposed HDAC4 as the gene in which a pathogenic variant caused the syndromic features of the 2q37 microdeletion syndrome.

The prevalence of the 2q37 microdeletion syndrome is unknown. This can be explained by the difficulty in recognizing the small terminal deletion on classical cytogenetic studies, and the failure to recognize the clinical syndrome on physical examination.

Diagnosis is based on cytogenetic analysis and molecular characterization. Research of translocation must also be performed, because the deletion may result from the transmission of a derivative chromosome.

The differential diagnosis includes other syndromes aneusomy segmental and Prader-Willi syndrome. The AHO (pseudo-hypoparathyroidism, PHP) and the pseudo-PHP (PPHP) should also be considered in the differential diagnosis but can be removed by highlighting of normal levels of calcium, phosphorus and parathyroid hormone in patients with the deletion 2q37 [18] demonstrated an overlap between 2q37 microdeletion and Smith-Magenis syndrome. Moreover [19] have found that two individuals with suspected phenotypic features of Kabuki syndrome had chromosomal rearrangements including a 2q37 deletion.

Clinical characteristics of 2q37 microdeletion syndrome are apparent and no cases of germinal mosaicism have been described nowadays. There appears a female predominance among patients with a 2q37 deletion [20], which is the case of our study.

2q37 microdeletion syndrome can be the result of a *de novo* chromosome abnormality or may be inherited from a parent who is a balanced translocation or inversion carrier [21] have shown that the majority of chromosomal terminal deletions were *de novo* (48/60 familial studies) and their parents have normal karyotype. In present work, no balanced translocation and no abnormalities were found in the karyotype of parents who want to have more children. In this case, genetic counseling is reassuring for the future pregnancies. However, when the karyotype of parents presents a balanced translocation, genetic counseling is not reassuring and prenatal diagnosis is possible for subsequent pregnancies. This diagnosis is possible by chromosome analysis of fetal cells obtained by amniocentesis usually performed at about 15 to 18 weeks' gestation or by chorionic villus sampling (CVS) at about 10 to 12 weeks' gestation. It is difficult to visualize terminal chromosome deletions in fetal cells, that's why we have to do the FISH technique to confirm the result.

The support of patient with 2q37 microdeletion syndrome should be multidisciplinary and include a full evaluation of major clinical signs. Speech therapy, physiotherapy and occupational therapy are necessary. Periodic reevaluation by a clinical geneticist to provide new recommendations and information about the syndrome is preferable. Moreover, the patient must perform periodic pediatric neurodevelopmental and behavioral assessments to help manage cognitive and behavioral problems.

CONCLUSION

Through this work, we highlight the contribution of the geneticist in the diagnostic approach and the identification of the terminal deletion 2q37 for appropriate support of patients and adequate genetic counseling for their families.

ACKNOWLEDGMENTS

We thank the patient described in this study and her family for sharing information with us and advocating for continued research of chromosomal disorders.

REFERENCES

1. Casas KA, Mononen TK, Mikail CN, Hased SJ, Li S, Mulvihill JJ. Chromosome 2q terminal deletion: report of 6 new patients and review of phenotype-breakpoint correlations in 66 individuals. *American Journal of Medical Genetics Part A*. 2004; 130(4): 331-339.
2. Aldred MA, Sanford RO, Thomas NS, Barrow MA, Wilson LC, Brueton LA. Molecular analysis of 20 patients with 2q37.3 monosomy: definition of minimum deletion intervals for key phenotypes. *Journal of medical genetics*. 2004; 41(6):433-439.
3. Batstone PJ, Simpson S, Bonthron DT, Keng WT, Hamilton D, Forsyth L. Effective monosomy or trisomy of chromosome band 2q37.3 due to the unbalanced segregation of a 2; 11 translocation. *American Journal of Medical Genetics Part A*. (2003); 118(3):241-246.
4. Ghaziuddin M, Burmeister M. Deletion of chromosome 2q37 and autism: a distinct subtype?. *Journal of Autism and Developmental Disorders*. 1999; 29(3):259-263.
5. Gorski JL, Cox BA, Kyine M, Uhlmann W, Glover TW. Terminal deletion of the long arm of chromosome 2 in a mildly dysmorphic hypotonic infant with karyotype 46,XY,del(2)(q37). *American journal of medical genetics*. 1989; 32(3):350-352.
6. Reddy KS, Flannery D, Farrer RJ. Microdeletion of chromosome sub-band 2q37.3 in two patients with abnormal situs viscerum. *American journal of medical genetics*. 1999; 84(5):460-468.

7. Lehman NL, Zaleski DH, Sanger WG, Adickes ED. Holoprosencephaly associated with an apparent isolated 2q37.1→2q37.3 deletion. *American journal of medical genetics*. 2001; 100(3):179-181.
8. Van Karnebeek CD, Koevoets C, Sluijter S, Bijlsma EK, Smeets DF, Redeker EJ. Prospective screening for subtelomeric rearrangements in children with mental retardation of unknown aetiology: the Amsterdam experience. *Journal of medical genetics*. 2002; 39(8):546-553.
9. Wolff DJ, Clifton K, Karr C, Charles J. Pilot assessment of the subtelomeric regions of children with autism: detection of a 2q deletion. *Genetics in Medicine*. 2002; 4(1):10-14.
10. Young RS, Shapiro SD, Hansen KL, Hine LK, Rainosek DE, Guerra FA. Deletion 2q: two new cases with karyotypes 46, XY, del(2)(q31q33) and 46, XX, del(2)(q36). *Journal of medical genetics*. 1983; 20(3):199-202.
11. Phelan MC, Rogers RC, Clarkson KB, Bowyer FP. Albright hereditary osteodystrophy and del(2)(q37.3) in four unrelated individuals. *American journal of medical genetics*. 1995; 58(1):1-7.
12. Power MM, James RS, Barber JC, Fisher AM, Wood PJ, Leatherdale BA. RDCI, the vasoactive intestinal peptide receptor: a candidate gene for the features of Albright hereditary osteodystrophy associated with deletion of 2q37. *Journal of medical genetics*. 1997; 34(4):287-290.
13. Bijlsma EK, Aalfs CM, Sluijter S, Luttikhuis MO, Trembath RC. Familial cryptic translocation between chromosomes 2qter and 8qter: further delineation of the Albright hereditary osteodystrophy-like phenotype. *Journal of medical genetics*. 1999; 36(8):604-609.
14. Giardino D, Finelli P, Gottardi G, De Canal G, Monica MD, Lonardo F. Narrowing the candidate region of Albright hereditary osteodystrophy-like syndrome by deletion mapping in a patient with an unbalanced cryptic translocation t(2;6)(q37.3; q26). *American Journal of Medical Genetics Part A*. 2003; 122(3):261-265.
15. Wilson LC, Leverton K, Luttikhuis MO, Oley CA, Flint J, Wolstenholme J. Brachydactyly and mental retardation: an Albright hereditary osteodystrophy-like syndrome localized to 2q37. *American journal of human genetics*. 1995; 56(2):400-407.
16. Doco-Fenzy M, Landais E, Andrieux J, Schneider A, Delemer B, Sulmont V. Deletion 2q36.2q36.3 with multiple renal cysts and severe mental retardation. *European journal of medical genetics*. 2008; 51(6):598-607.
17. Chaabouni M, Le Merrer M, Raoul O, Prieur M, De Blois MC, Philippe A. Molecular cytogenetic analysis of five 2q37 deletions: refining the brachydactyly candidate region. *European journal of medical genetics*. 2006; 49(3):255-263.
18. Williams SR, Aldred MA, Der Kaloustian VM, Halal F, Gowans G, McLeod DR, Zondag S, Toriello HV, Magenis RE, Elsea SH. Haploinsufficiency of HDAC4 causes brachydactyly mental retardation syndrome, with brachydactyly type E, developmental delays, and behavioral problems. *American Journal of Human Genetics*. 2010; 87(2):219-28.
19. Cuscó I, del Campo M, Vilardell M, González E, Gener B, Galán E, Toledo, Pérez-Jurado LA. Array-CGH in patients with Kabuki-like phenotype: identification of two patients with complex rearrangements including 2q37 deletions and no other recurrent aberration. *BMC Medical Genetics*. 2008; 9:27.
20. Doherty ES, Lachawan FL. 2q37 microdeletion syndrome. *GeneReviews*. University of Washington, Seattle; 2013.
21. Ravnan JB, Tepperberg JH, Papenhausen P, Lamb AN, Hedrick J, Eash D. Subtelomere FISH analysis of 11 688 cases: an evaluation of the frequency and pattern of subtelomere rearrangements in individuals with developmental disabilities. *Journal of Medical Genetics*. 2006; 43(6):478-489.