

## Penile Squamous Cell Carcinoma: An Inextirpable Tumor Case Report

Reda Tariqi<sup>1\*</sup>, Hamza El Abidi<sup>1</sup>, Hussein Abdallah<sup>1</sup>, Soukaina Bekkouche<sup>2</sup>, Hachem Elsayegh<sup>1</sup>, Yassine Nouini<sup>1</sup><sup>1</sup>Department of Urology A, Ibn Sina University Hospital, Rabat, Morocco<sup>2</sup>Institut National d'Oncologie "Sidi Mohammed Ben Abdellah", Rabat, MoroccoDOI: [10.36347/sjmc.2022.v10i09.015](https://doi.org/10.36347/sjmc.2022.v10i09.015)

| Received: 19.08.2022 | Accepted: 13.09.2022 | Published: 17.09.2022

**\*Corresponding author:** Reda Tariqi

Department of Urology A, Ibn Sina University Hospital, Rabat, Morocco

### Abstract

### Case Report

We report a case of penis cancer at University hospital center of rabat, about a 66 years old patient with diabetes and a history of chronic smoking. The symptoms were marked by the appearance of an interscrotal perineal mass initially painless with some itching, then painful to the touch; associated with a dysuria all evolving to a scrotal urinary fistula. The diagnosis of squamous cell carcinoma was confirmed intraoperatively after an extemporaneous biopsy. The decision was to reduce the tumor volume as much as possible. Follow-up treatment after a multidisciplinary discussion was to complete with chemotherapy.

**Keywords:** Squamous cell carcinoma of the penis, Lymph node excision, TNM classification, inextirpable tumor.

Copyright © 2022 The Author(s): This is an open-access article distributed under the terms of the Creative Commons Attribution 4.0 International License (CC BY-NC 4.0) which permits unrestricted use, distribution, and reproduction in any medium for non-commercial use provided the original author and source are credited.

## INTRODUCTION

Penile tumour is a fairly uncommon disease with an incidence of 1/100000 in Europe and USA, and a higher 1-2% found in Africa, South America and south East Asia. Epidermoid carcinoma is the most frequent histological type representing a total of 95% [1].

In recent years light has been shed on many risk factors such as: phimosis, smoking, HPV infection, chronic penile inflammation but also low socio economical status and multiple sexual partners [1, 2].

On the other hand the protective role of circumcision has been indentified. The diagnosis is suspected clinically by the discovery of the lesions mainly on the glans or the foreskin but only affirmed histologically after a biopsy or a resection.

Doppler Ultrasound and MRI with an induced erection are used to identify the corporal invasion. Resection surgery, radiotherapy, brachytherapy or chemotherapy, establish the various therapeutics, according to different carcinological results [2]. The TNM staging, the histological type, the tumoral rank, the vascular and lymphatic invasion conditions the prognosis which remains pejorative and dark. Indeed the survival rate is of the order of 80% in 5 years

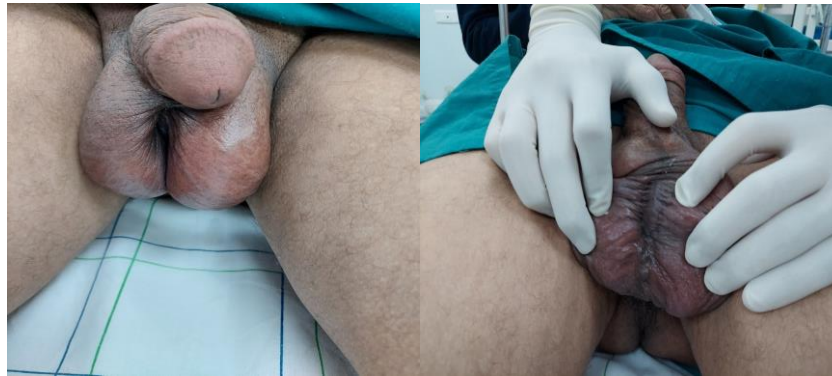concerning the patients without ganglionic lesions and about 50 % if ganglions are invaded [2]. The objective of this work was to report our experience.

## OBSERVATION

Mr Z.A, a 66 years old patient, diabetic under oral hypoglycemic medications, and former tobacco user who smoked for about 30 years and weaned off over 10 years ago. Our patient has been circumcised from an early age, and without a history of urethritis.

The symptoms started 7 months before his admission, by the appearance of an interscrotal perineal mass initially not painful but itchy and then painful to the touch, dysuria complicated by urinary fistula with chronic scrotal swelling and emission of pus, blood and urine from a scrotal fistula. The patient benefited from an antibiotic treatment after an initial consultation then referred to our hospital after no remission.

The genital examination revealed a firm mass taking the base of the penis and the perineal floor, palpable through the scrotum. The testicles were intact and the prostate was of normal consistency and size. No inguinal lymph nodes were found initially, later we found bilateral inguinal adenopathy, fixed and small, not exceeding 1cm in size.

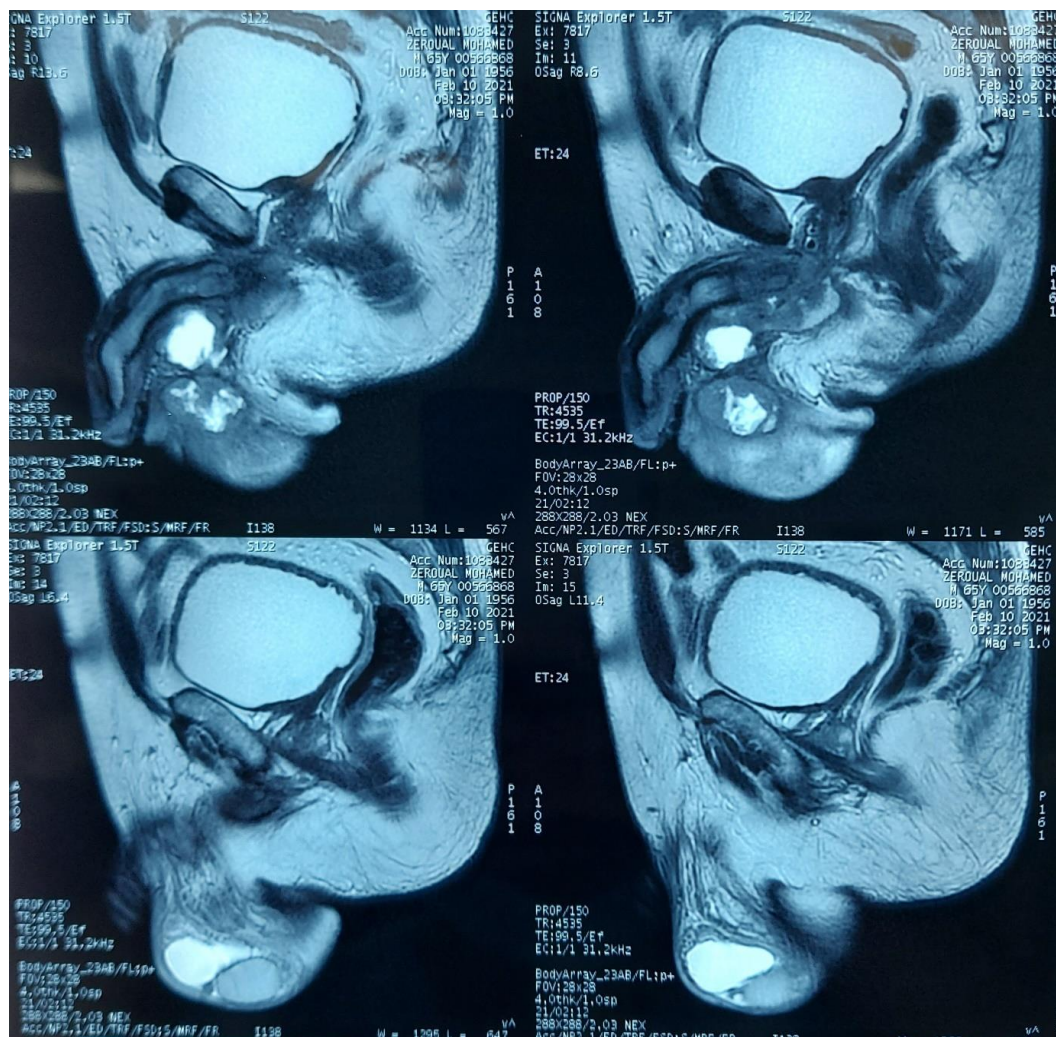


**Figure 1: Interscrotal perineal mass initially complicated by urinary fistula with emission of pus, blood and urine**

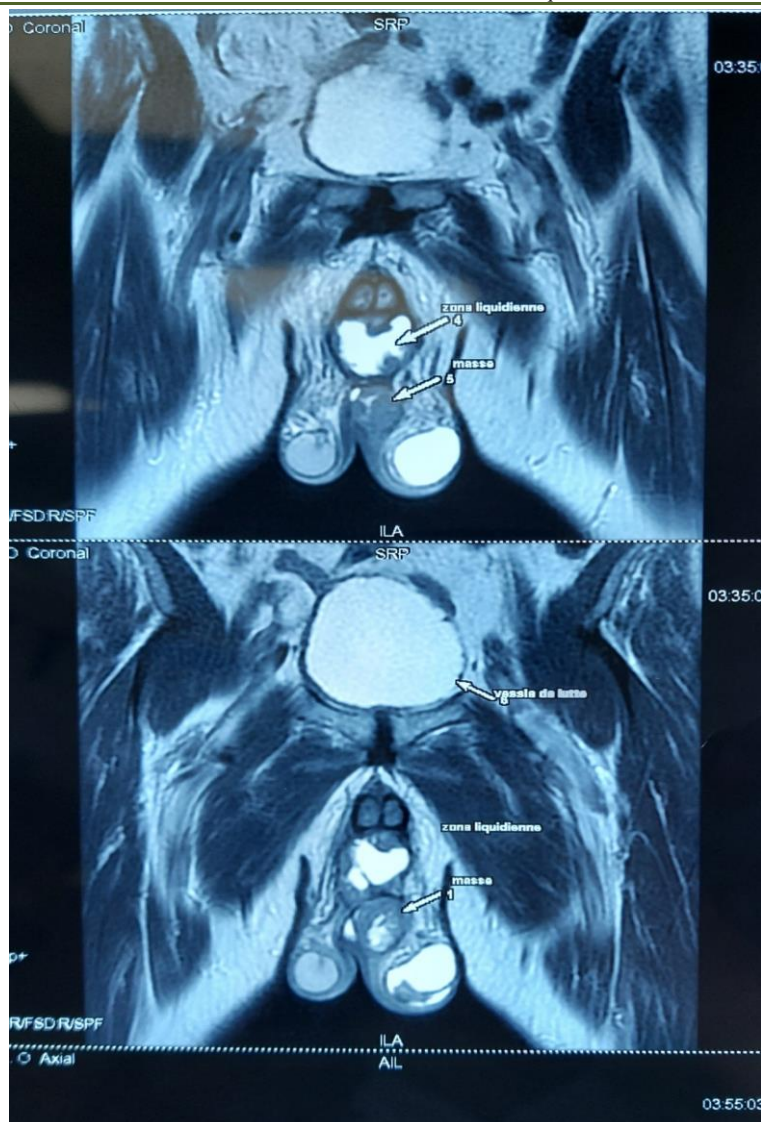
The scrotal ultrasound revealed a large heterogeneous tissular mass in the perineum and thickening of scrotal tunics, a right epididymal cyst and spermatic cord cyst, and finally a normal left testicle.

corpus spongiosum and extending to the scrotal wall, measuring 118x34mm. This mass surrounds the urethra without infiltrating it, respecting the testicules, the spermatic cord and the anal canal. In addition to bilateral inguinal adenomegalies and a left hydrocele of moderate abundance.

A pelvic MRI was performed showing a mass of perineal soft tissue and the penis, in contact with the



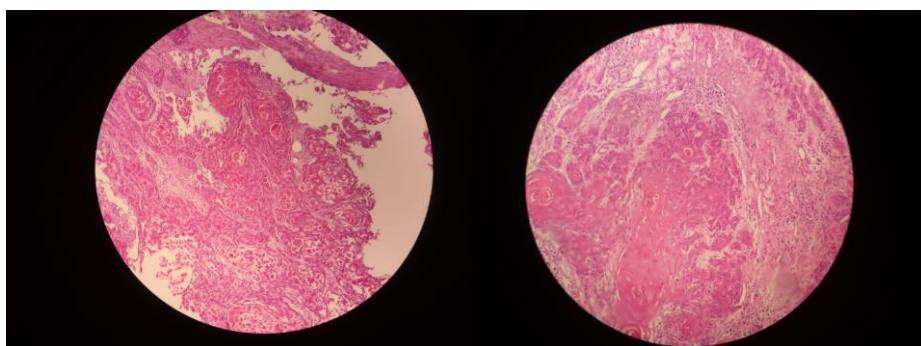




**Figure 2:** Pelvic MRI: a) Saggittal cut, b) Coronal cut : showing a mass of perineal soft tissue and the penis, in contact with the corpus spongiosum and extending to the scrotal wall, measuring 118x34mm

First, A cystoscopy was performed with a biopsy, showing complete stenosis of the initial part of the spongy urethra adjacent to the mass. the results of the anapathomological study were inconclusive.

The patient underwent an excisional biopsy, anapathological examination showed an infiltrating and matured epidermoid carcinomatous proliferation, with the presence of perinervous sheaths, and no vascular embolism.



**Figure 3:** ( a+b) Carcinomatous proliferation, made of plyglonal cells with an oval, hyperchromatic and strongly nucleated nucleus and an eosinophilic cytoplasm, these elements are arranged in trabeculae and cords within a fibrous and inflammatory stroma, in favour of an infiltrating and mature squamous cell carcinoma

The extension assessment was completed by abdominal and thoracic CT scan and the patient was classified T4N3M0.

After multidisciplinary consultation and in front of the inextirpable character of the mass, the patient benefited from a cystostomy for urinary diversion and was submitted to chemotherapy, where he had 5 sessions of Cisplatin and 5FU but without improvement and with a stabilization of the lesions and he was put under palliative care.

## DISCUSSION

Malignant penile cancer is a rare tumour in western Europe and USA, representing barely 0.5-0.6% of all tumours [3], with a higher incidence in the sixth decade of life. Most penile cancers have a squamous epithelial origin, including cancer in situ and the invasive squamous cell carcinoma. Risk factors such as lack of circumcision at an early age, phimosis, smegma accumulation due to poor hygiene, infection with the human papilloma virus and xerotic balanitis (lichen sclerosus) are recognized [3].

The majority of penile cancers are epithelial, with squamous cell histology accounting for 95% of cases. Other histologies, including basal cell carcinoma, melanoma, sarcoma, and adenocarcinoma, are rarer [3, 4]. The primary tumor is usually located on the glans (48% of cases) or prepuce (21% of cases) and is found on the shaft in less than 2% of cases.

As described in Banzo J, T *et al.*, 2014 [3] the correct tumor staging according to the TNM classification is essential for treatment planning and establishing a prognosis. Imaging techniques provide information on the degree of tumor invasion (T), presence of lymph node metastasis (N) and distant metastasis (M). Many unresolved controversies about which imaging procedures should be included in the diagnosis and staging of the SCCP, aggravated by the relatively low incidence of the tumor, the limited number of publications and the absence of randomized clinical trials [3].

The EAU recommends the MRI with pharmacologically induced erection by injection into the corpora cavernosa of 10 mg of prostaglandin E1 [3, 5], in order to determine the local extent of the tumor. The combination of physical examination and MRI provides the best correlation with histological stage.

Histological and molecular characteristics of primary tumor such as histological subtype and grade, lymphatic embolization and/or venous thickness and pattern of tumor growth are the most important variables for predicting inguinal lymph node involvement. The presence of metastases in regional lymph nodes, considering the number and size of involved nodes, both unilateral and bilateral inguinal

lymph node metastases, infiltration of the pelvic lymph nodes and the presence of capsular invasion are the main factors to establish an unfavorable prognosis [6].

The conventional treatment for squamous cell carcinoma of the penis has been total or partial penectomy, which has achieved greater than 90% local control.

However, concern for significant functional morbidity and psychosexual issues has led to the emergence of organ-sparing treatment options. Penile-conserving procedures include Mohs microscopic surgery, external beam radiation therapy (EBRT), interstitial brachytherapy, laser ablation, and cytotoxic chemotherapy [7].

Inguinal lymph node dissection (ILND) occupies a central role in the management of non-metastatic penile cancer [8], and is used either for diagnostic or therapeutic purposes. The National Comprehensive Cancer Network and the European Association of Urology guidelines recommend ILND or dynamic sentinel lymph node excision in patients with squamous cell carcinoma of the penis (SCCP) starting from high-grade T1 stage and beyond [9].

CCAFU treatment recommendations 2018-2019 in stage T3 or T4 is Total penile amputation with perineal urethrostomy if the tumour is removable, possibly combined with neoadjuvant chemotherapy. And in cN3 stage, a thoracic-abdominal-pelvic CT scan for extension is recommended, as well as multimodal management, due to the poor prognosis. Neoadjuvant chemotherapy is recommended followed by radical removal in responders. If there is an objective response to chemotherapy, inguinal and pelvic lymphadenectomy may be discussed [10].

In other situations (tumor stabilization or progression), only palliative management is permissible: salvage chemotherapy or radiotherapy or supportive care.

Palliative treatment using chemotherapy, the effectiveness of which has been improved by the introduction of taxanes in first line. In second line, Paclitaxel alone or Cisplatin with Gemcitabine were proposed.

Our patient was initially classified as T4cN3M0, with a non-removable mass, and received initial chemotherapy with Cisplatin and 5FU, and given the non regression but stabilization of the lesions after 5 sessions, the patient was put on palliative treatment.

## CONCLUSION

Squamous cell carcinoma of the penis is a relatively rare male malignancy with low incidence rates.

Treatment is stage dependent and includes, for nondistant metastatic, surgery of the primary lesion as well as regional lymph node dissection when indicated.

Because of the low incidence of penile cancer which explain the lack of systematized coverage.

**Conflict of Interest:** The author declare that there is no conflict of interest.

## REFERENCES

1. EAU Guidelines. (2020). Edn. presented at the EAU Annual Congress Amsterdam. ISBN 978-94-92671-07-3.
2. Jean-Nicolas Cornu Et Coll. (2007). Prise en charge carcinologique des cancers péniens. *Prog Urol*, 17(7), 1347-1350.
3. Banzo, J., Ubieto, M. A., Andrés, A., Tardín, L., Rambalde, E. F., Cancer, L. F., ... & Prats, E. (2014). The contribution of 18F-FDG PET/CT in a patient with cutaneous metastases of squamous cell carcinoma of the penis. *Revista Española de Medicina Nuclear e Imagen Molecular*, 33(5), 293-295.
4. Brady, K. L., Mercurio, M. G., & Brown, M. D. (2013). Malignant tumors of the penis. *Dermatologic Surgery*, 39(4), 527-547.
5. Pizzocaro, G., Algaba, F., Horenblas, S., Solsona, E., Tana, S., Van Der Poel, H., & Watkin, N. A. (2010). EAU penile cancer guidelines 2009. *European urology*, 57(6), 1002-1012.
6. Ficarra, V., Akduman, B., Bouchot, O., Palou, J., & Tobias-Machado, M. (2010). Prognostic factors in penile cancer. *Urology*, 76(2), S66-S73.
7. O'Neil, B., Brant, W. O., Slack, S. D., Tward, J. D., & Myers, J. B. (2011). Penile cancer: contemporary considerations in management of local disease. *Current Urology*, 5(2), 62-71.
8. da Costa, W. H., Rosa de Oliveira, R. A., Santana, T. B., Benigno, B. S., da Cunha, I. W., de Cássio Zequi, S., ... & Lopes, A. (2015). Prognostic factors in patients with penile carcinoma and inguinal lymph node metastasis. *International Journal of Urology*, 22(7), 669-673.
9. NCCN Guidelines: Penile Cancer, Version 1. 2016: Available at: <https://www.nccn.org/>.
10. Sèbe, P., Ferretti, L., Savoie, P. H., Morel-Journel, N., Fléchon, A., Murez, T., ... & Durand, X. (2016). CCAFU french national guidelines 2016-2018 on penile cancer. *Progres en Urologie: Journal de L'association Francaise D'urologie et de la Societe Francaise D'urologie*, 27, S167-S179.