

## Small Bowel Obstruction Due to Uterine Adhesions Following Caesarean: A Case Report

Karam Aziz\*, Abdelouhab El Marouni, Houssam Belghali, Ahmed Zerhouni, Tarik Souiki, Karim Ibn Majdoub Hassani, Imane Toughrai, Khalid Mazaz

Visceral Surgery Service, Hassan II University Hospital, Faculty of Medicine and Pharmacy of Fez, Sidi Mohamed Ben Abdullah University, Fez, Morocco

DOI: [10.36347/sjmcr.2020.v08i02.005](https://doi.org/10.36347/sjmcr.2020.v08i02.005)

Received: 20.12.2019 | Accepted: 27.12.2019 | Published: 08.02.2020

\*Corresponding author: Karam Aziz

### Abstract

### Case Report

A female patient was admitted urgently; for abdominal pain, vomiting and stopping of materials and gases. This symptomatology had been evolving for 36 hours. The interrogation notes a history of a caesarean. The physical examination confirmed the presence of an occlusive syndrome with abdominal distension and meteorism. Hernias parietal were free. The rest of the physical examination was normal. X-ray of the abdomen without preparation noted hydro-aerial levels of the hailic type. The Computed tomography showed an intestinal obstruction in a bird's beak.

**Keywords:** Internal Hernia, post caesarean adhesions, Small Bowel Obstruction.

**Copyright © 2019:** This is an open-access article distributed under the terms of the Creative Commons Attribution license which permits unrestricted use, distribution, and reproduction in any medium for non-commercial use (NonCommercial, or CC-BY-NC) provided the original author and source are credited.

## INTRODUCTION

The small bowel occlusions are a common cause of hospitalization in surgery [1]. Among all the etiologies (iatrogenic, tumoral, inflammatory, metabolic, congenital), adhesions are the leading cause of admission for small bowel obstruction (54%), the second cause being hernias (30%) [1].

This case report presents a rare care of small bowel occlusion caused by an adherence due to caesarean surgery.

## CASE REPORT

A 30-year-old female was admitted urgently; for abdominal pain, vomiting and stopping of materials and gases. This symptomatology had been evolving for 36 hours. The interrogation notes a history of caesarian surgery. The physical examination confirmed the presence of an occlusive syndrome with abdominal distension and meteorism. Hernias parietal were free. The rest of the physical examination was normal. X-ray of the abdomen without preparation noted hydro-aerial levels of the hailic type. The Computed tomography showed an intestinal obstruction in a bird's beak.

The diagnosis of acute intestinal obstruction was retained. But in the face of the worsening abdominal tenderness in defense; A laparotomy was indicated urgently. The incision been a median. We

noted incarceration of ileal loops across a defect about 5 centimeters long made by an adherence located between the uterus and the anterior parietal muscles. The incarcerated ileum was necrotic. It was an acute intestinal obstruction by internal hernia (fig 1.2. The treatment consisted of resection and anastomosis and closure of the hernia by a sutured thread surfer. The postoperative course was simple. The discharge from the hospital been authorized on the third postoperative day.

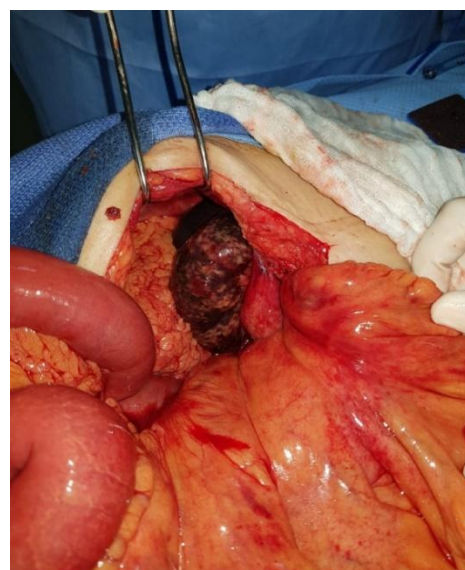
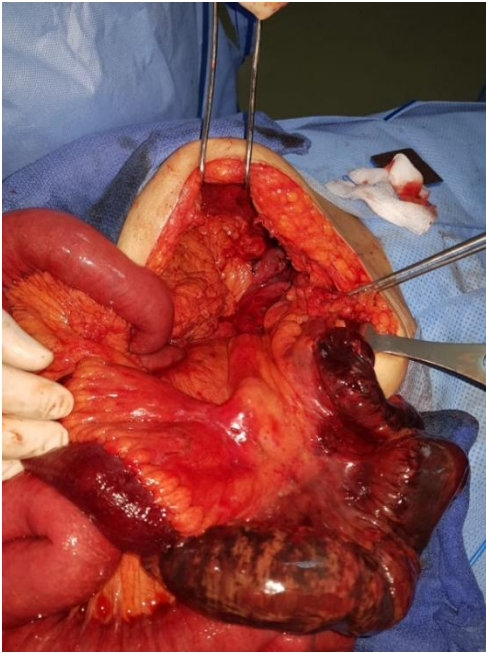


Fig-1: Image show the intestinal incarceration



**Fig-2: Image of the incarceration**

## DISCUSSION

We found that operations accounting for the majority of early postoperative adhesive obstructions were large bowel, rectal, appendiceal and gynecological surgery, confirming the findings of others [2, 3]. The high number of obstructions after appendicectomy must reflect the fact that this is a commonly performed operation and not that appendicectomy is particularly prone to producing obstruction. Surgery below the transverse mesocolon accounts for the majority of operations subsequently producing adhesive obstruction [4, 5].

Following division of adhesions, recurrence of intestinal obstruction may be as high as 32% [6]. Despite the near certainty that almost all abdominal

surgery produces adhesions, the present high, and increasing, incidence of postoperative adhesive obstruction and its high recurrence rate following lysis of the adhesion, there is currently no effective treatment of adhesions that prevents their recurrence.

## CONCLUSION

Small bowel obstruction due to uterine adhesions following caesarean is a rare but possible cause of occlusion intestinal acute in adults. It should be considered in the presence of episodes of subocclusion spontaneously reduced. Late diagnosis can lead to complications type of loop necrosis.

## REFERENCES

- 1 Barmparas G, Branco BC, Schnuriger B, Lam L, Inaba K, Demetriades D. The Incidence and Risk Factors of Post-Laparotomy Adhesive Small Bowel Obstruction. *J Gastrointest Surg*, 2010.
- 2 Sykes PA, Schofield PF. Early postoperative small bowel obstruction. *Br J Surg*. 1974 Aug;61(8):594–600.
- 3 Quatromoni JC, Rosoff L, Sr, Halls JM, Yellin AE. Early postoperative small bowel obstruction. *Ann Surg*. 1980 Jan;191(1):72–74.
- 4 Stewart RM, Page CP, Brender J, Schwesinger W, Eisenhut D. The incidence and risk of early postoperative small bowel obstruction. A cohort study. *Am J Surg*. 1987 Dec;154(6):643–647.
- 5 Krebs HB, Goplerud DR. Mechanical intestinal obstruction in patients with gynecologic disease: a review of 368 patients. *Am J Obstet Gynecol*. 1987 Sep;157(3):577–583.
- 6 Brightwell NL, McFee AS, Aust JB. Bowel obstruction and the long tube stent. *Arch Surg*. 1977 Apr;112(4):505–511.