

## Kartagener Syndrome: A Case Report

Dr. Jayashankar. C. A.<sup>1\*</sup>, Dr. D. S. Somasekar<sup>2</sup>, Dr. Pavan Kumar Perugu<sup>3</sup>, Dr. K. Varsha Reddy<sup>3</sup>, Dr. Bhanu Prakash<sup>4</sup>, Dr. Santosh K.V.<sup>5</sup>

<sup>1</sup>Associate Professor, Department of General Medicine, Vydehi Institute of Medical Sciences and Research centre, White field, Bangalore-560066, Karnataka, India

<sup>2</sup>Professor and Head, Department of General Medicine, Vydehi Institute of Medical Sciences and Research centre, White field, Bangalore-560066, Karnataka, India

<sup>3</sup>Post graduate, Department of General Medicine, Vydehi Institute of Medical Sciences and Research centre, White field, Bangalore-560066, Karnataka, India.

<sup>4</sup>Professor, Department of Dermatology, Vydehi Institute of Medical Sciences and Research centre, White field, Bangalore-560066, Karnataka, India

<sup>5</sup>Professor, Department of Pathology, Vydehi Institute of Medical Sciences and Research centre, White field, Bangalore-560066, Karnataka, India

### \*Corresponding Author:

Name: Dr. Jayashankar. C. A

Email: [drjayashankar.ca@gmail.com](mailto:drjayashankar.ca@gmail.com)

**Abstract:** Abstract: Immotile cilia syndrome is associated with the basic defect of disordered ciliary motility. Kartagener's syndrome has been considered to be a sub group of Immotile Ciliary Syndrome. Kartagener Syndrome (KS) is a rare autosomal recessive disorder consisting of triad of sinusitis, bronchiectasis and situs inversus with dextrocardia. We report a 25 year old male with Kartagener syndrome from our tertiary care centre diagnosed clinically and by relevant radiological investigations.

**Keywords:** Kartagener's syndrome, primary ciliary dyskinesias, situs inversus

### INTRODUCTION

Primary ciliary dyskinesia (PCD), also known as immotile cilia syndrome is an inherited disorder characterized by impaired ciliary function leading to diverse clinical manifestations, including chronic sinopulmonary disease, persistent middle ear effusions and infertility [1]. Kartagener's syndrome has been considered to be a sub group of this syndrome. Kartagener's syndrome is characterized by situs inversus, chronic paranasal sinusitis and bronchiectasis [1]. It is a rare autosomal recessive, genetic disorder with estimated prevalence of about 1 in 68,000 [2]. Here we report a case of Kartagener syndrome from our hospital.

### CASE REPORT

A 25 year old unmarried male, was admitted with history of cough with expectoration and breathlessness since past 10 days. Cough was insidious in onset and progressively increasing in severity, but did not interfere in his daily routine activities. Sputum was profuse, mucopurulent, occasionally blood tinged, odourless and varying on change in posture. It was associated with low grade intermittent fever relieved by antipyretics. Breathlessness was insidious in onset, progressively increasing in severity, occurring only on exertion and relieved on taking physical rest.

Patient gave no history of wheezing, chest pain, palpitations, swelling of lower limbs or syncopal episodes. He gave past history of repeated hospitalization for recurrent episodes of nasal discharge, chronic cough with expectoration and fever relieved by medications since childhood. He also gave history suggestive of pulmonary tuberculosis and had received antituberculous drugs for 6 months 9 years ago. He was born of a non consanguineous marriage couple.

On general physical examination, patient was moderately built and nourished; conscious, oriented, pulse was 90 beats per minute, regular in rhythm, normal volume and character with no radio femoral delay. Blood pressure was 110/70 mm of Hg and oral temperature was 100° F. He had grade 1 clubbing in fingers and toes of both hands and feet respectively. There was no pallor, pedal oedema, cyanosis and lymphadenopathy or raised jugular venous pressure. Respiratory system examination revealed coarse leathery crepitations in both infra scapular and infraaxillary areas on auscultation.

On cardiovascular examination, apex beat was felt on right 5<sup>th</sup> intercostal space 1 cm lateral to midclavicular line and on auscultation of heart, heart

sounds were better heard on right side with no murmurs.

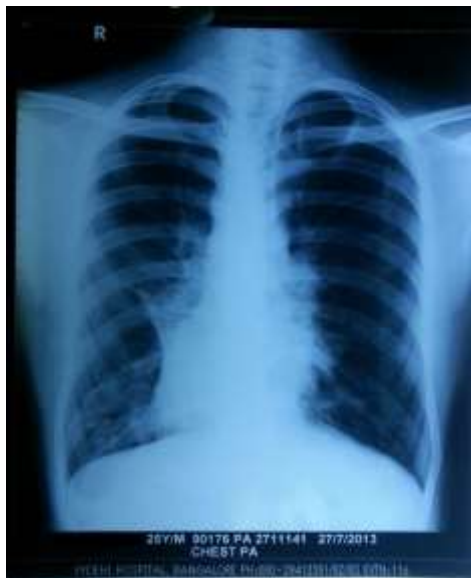Abdominal examination revealed tympanic note on percussion in right hypochondrium. Nervous system, spine and skin examination was clinically normal.

Laboratory examination revealed Hb% of 13.9 gms% (Normal: 11 to 18.8 gms/dl), total leucocyte count 11,060/ $\mu$ L (Normal: 4000 to 11,000/ $\mu$ L), platelet count 2,51,000/ $\mu$ L (Normal: 1,50,000 to 4,00,000/ $\mu$ L) and ESR (Erythrocyte sedimentation rate) was 30 mm in 1st hour (Normal reference range is 0 to 10mm in 1<sup>st</sup> hour).

Random blood glucose was 85 mg/dl (Normal: 70 to 140mg/dl). Serum total IgE was 250 IU/ml (Normal: 0-380 IU/ml).

Electrocardiogram revealed features of Dextrocardia. 2 D Echocardiogram showed dextrocardia with no pulmonary artery hypertension.

Chest X ray posterior anterior view revealed dextrocardia, linear fibrotic bands and dilated cystic changes in lower zones of both lungs suggestive of bronchiectasis and gastric fundus gas shadow on right side (fig. 1).

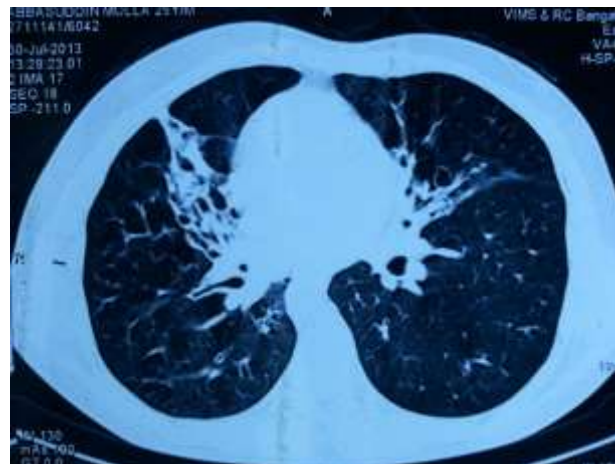


**Fig. 1: Chest X ray posterior anterior view; shows dextrocardia with bilateral lower zone fibrosis and bronchiectatic changes and gastric fundus gas shadow on right side**

Sputum for Gram stain revealed Gram positive cocci in pairs suggesting streptococcus pyogenes. Sputum was negative for acid fast bacilli.

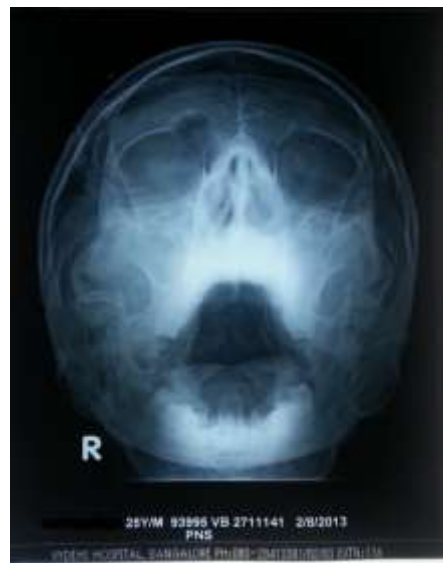HRCT (High resolution computed tomography) of thorax revealed bronchiectatic changes in the right middle, lingular and bilateral lower lobes

and dextrocardia with situs inversus (fig. 2). Patient refused to undergo bronchoscopy.



**Fig. 2: HRCT of thorax: shows bronchiectatic changes in both the lungs**

X ray paranasal air sinuses revealed opacification of bilateral maxillary sinuses suggesting bilateral maxillary sinusitis with non pneumatisation of left frontal sinus (fig. 3).



**Fig. 3: Radiograph of paranasal air sinuses: shows opacification of bilateral maxillary sinuses with non pneumatisation of left frontal sinus**

Ultrasound examination of abdomen and pelvis revealed situs inversus totalis. Saccharin test was performed and transit time was 1 hour 15 minutes, suggesting a delayed transit time. Semen analysis revealed oligoasthenospermia with sperm count of 10 million/ml (Normal: 20 -30million/ml) with 70% of sperms immotile (fig. 4).

**Vydehi Hospital**  
Health With Care

**CENTRAL DIAGNOSTIC LABORATORY**

Patient Name	25 Yrs 3 Months 20 Days	Hand No	2711141	Dring	01-Aug-2013 12:29 pm
Age	25 Yrs 3 Months 20 Days	BR No	21863	Sample Collection	01-Aug-2013 3:20 pm
Sex	MALE	Lab No	20130088	Reported	01-Aug-2013 4:06 pm
Patent Type	IN PATIENT	Dr Name		Printed	25-Nov-2013 3:50 pm
Visit Type	MWV	Sample Type		Status	
		Bed No	MMS/08		

**CLINICAL PATHOLOGY**

Test Parameters	Method	Result	Units	Biological Reference Interval
<b>SEMIN ANALYSIS</b>				
PERIOD OF ABSTINENCE		3 DAYS		
COLOUR & APPEARANCE		OPAQUE, GREY WHITE		OPAQUE (GREY WHITE)
PH		7.2		7.2 To 8.0
VOLUME		2.0ML		2.1 To 5.5ML
VISCOSITY		NORMAL		
LIQUIFACTION TIME		30 MINUTES		20 To 30 MINUTES
TOTAL SPERM COUNT		10 MILLION/ ML		20 MILLION/ML
MOTILITY - ACTIVE		80%		
		SLUGGISH		
		NON-MOTILE		
OTHERS		70%		
MORPHOLOGY		PLUS CELLS 1-2%EF 20% ABNORMAL FORMS LIKE PIN HEADS AND GLOBULAR HEADS SEEN		
IMPRESSION		OLIGOSASTHENO SPERMIA		

ORICHANDRAN  
TECHNICIAN

DR ROJARAMAN  
PATHOLOGIST

402, E.P.I.P. Area, Whitefield, BANGALORE - 560 066. Ph : 080-28415501/82/85/84/85  
Fax : 28412956, 28416199. Email : info@vshs.ac.in. Web : www.vshs.ac.in

Fig. 4: Semen analysis report

A diagnosis of Kartagener's syndrome was made on the basis of features of clinical presentation and imaging features.

Patient was treated with intravenous antibiotics, oral antipyretics, mucolytics. Patient was symptomatically better and was discharged from the hospital.

## DISCUSSION

Ciliary movement disorders are classified into congenital ciliary movement disorders also known as primary ciliary dyskinesias and acquired ciliary movement disorders [3]. Kartagener's syndrome has been considered to be a sub group of primary ciliary dyskinesias (PCD) [1]. The reported estimated incidence rate of Kartagener syndrome is 1/15000 - 20000 per year [4].

Seiwert [5] for the first time reported the association of bronchiectasis with situs in 1904. However, it was Manes Kartagener [6] who first recognized the clinical triad of situs versus, chronic sinusitis, and bronchiectasis as a distinct congenital syndrome in 1933.

Camner *et al.* [7] first suggested ciliary dyskinesia as the cause of KS in 1975. Afzelius [8] recognized the relationship between Kartagener's syndrome and male infertility when he observed lack of dynein arms in the sperms and cilia of four subjects, three with Kartagener's syndrome and a fourth one, brother of one of the three subjects in 1976.

In 1977, Eliasson *et al.* [9] used the term "Immotile cilia syndrome" to categorize male patients with sterility and chronic respiratory infection.

In 1981, Rossman *et al.* [10] used the term dyskinesic ciliary syndrome because some patients with KS had cilia that were not immobile but exhibited uncoordinated and inefficient movement pattern. Thus the term Dyskinetic cilia syndrome is considered appropriate than immotile cilia syndrome [11].

It has been proposed that abnormal ciliary beating is necessary for visceral rotation during development of embryo. In patients that have PCD (primary ciliary dyskinesia), half will have situs versus and will become cases of Kartagener's syndrome; the other half will have normal situs due to random rotation [12]. Patients with Kartagener's syndrome may have either situs solitus (dextrocardia) only or situs versus totalis, where all the viscera are on the opposite side [12] including a left-sided appendix [13].

Abnormal ciliary motility results to ineffective mucociliary clearance predisposing to recurrent sinopulmonary infections. Congenital heart disease like transposition of great vessels, trilobular or bilobular heart, pyloric stenosis, urethral meatus on the ventral ridge of glans penis, post cricoid web, polysplenia, hepatic steatosis, hydrocephalus, Marfan's syndrome, polysplenia, retinitis pigmentosa, congenital sensorineural deafness and vestibular dysfunction are

various abnormalities reported in dyskinetic cilia syndrome [11].

A diagnostic criteria has been proposed for diagnosis of dyskinetic cilia syndrome which includes history of chronic bronchial infection and rhinitis from early childhood, combined with one or more of following features: (i) situs versus or dextrocardia in a patient or a sibling, (ii) living but immotile spermatozoa, (iii) tracheobronchial clearance, which is absent or nearly so and (iv) cilia that have ultra structural defects characteristic of the syndrome [11]. Saccharin test is the screening test for KS.

Here we place a grain of saccharin or small tablet of artificial sweetener with the help of a pair of forceps, two centimetres from the free edge of alar nasi on the inferior turbinate and the patient is asked to sit up. The patient is asked to indicate as soon as he/she appreciates the sweet taste of saccharin or artificial sweetener. Normal individuals report the taste within thirty minutes [14] and it is delayed in dyskinetic cilia syndrome.

Electron microscopy is done to detect ultrastructural defects in cilia such as lack of dynein arms [15].

Our patient is 25 year old male who presented with recurrent episodes of rhinitis, sinusitis, and lower respiratory tract infections. Recurrent lower respiratory tract infections have lead to bronchiectasis. Radiological evaluation revealed dextrocardia and bronchiectasis. Semen analysis revealed that he has oligoasthenospermia. Saccharin test revealed delayed mucociliary clearance.

Our patient fulfils the above described criteria of dyskinetic cilia syndrome. However electron microscopy of nasal mucosa biopsy and genetic studies to detect mutation in DNA11 and DNA H5 genes [15] were not done due to unavailability of resources in our hospital.

## CONCLUSION

Delay in recognizing Kartagener syndrome is not uncommon as in our case, because the clinical manifestations are easily mistaken for common infections. Kartagener syndrome should be considered in individual with recurrent rhinitis and lower respiratory tract infections since childhood so that early diagnosis is made and appropriate treatment is instituted to prevent further progression and deterioration in lung function.

## REFERENCES

1. Ferkol T; Primary Ciliary Dyskinesia (Immotile Cilia Syndrome). In Nelson text book of Pediatrics. Bonita F Stanton, Nina F Schor, Joseph W St Geme III, Richard E

- Behrman editors; 19<sup>th</sup> edition,. Saunders, Imprint of Elsevier, Philadelphia, 2001: 1497.
2. Afzelius BA; Immotile cilia syndrome: past, present and prospects for the future. Thorax, 1998; 53: 894-897.
3. Mahsud I, Din S; Kartagener's syndrome. Gomal Journal of Medical Sciences, 2006; 4(2):79-81.
4. Tokur M, Tokur N, Yenibertiz D, Korkmaz C; PektusKarinatusDeformitesininEşlikEttiğiKart agenerSendromu. Journal of Clinical and Analytical Medicine,TürkGöğüsCerrahisiderneği 5, yıllık kongresi-2009:25-26.
5. Seiwert AK; Uebereinen Fall von BronchiektasiebeieinemPatientenmitsitusin versusviscerum. Berlin KlinWschr., 1904; 41:139-41.
6. Kartagener M. ZurPathogenese der Bronchiektasien:Bronchiektasienbeisitusviscer uminversus. BeitrageZumKlinik der Tuberkulose,1933;83:489-501.
7. Camner P, Mossberg B, Afzelius BA; Evidence ofcongenitally nonfunctioning cilia in the tracheobronchialtract in two subjects. Am Rev Respir Dis.,1975;112:807-809.
8. Afzelius BA; A human syndrome caused by immotile cilia.Science, 1976; 193: 317-319.
9. Eliasson R, Mossberg B. Camner P, Afzelius BA; The immotilecilia syndrome: A congenital ciliary abnormality as an etiologicfactor in chronic airway infections and male sterility. N Engl JMed., 1977;297:1-6.
10. Rossman CM, Forrest JD, Lee RM, Newhouse MT; Thedyskinetic cilia syndrome. Ciliary motility in immotile ciliasyndrome. Chest,1980;78: 580-582.
11. Fraser RS, Muller NL, Colman N, Pare PD; Bronchiectasis and otherBronchial Abnormalities. In Diagnosis of diseases of the Chest. Fraser RS, Muller NL, Colman, Pare PD editors, 4<sup>th</sup> edition, W.B. Saunders Company, Philadelphia, 1999: 2281-2283.
12. None PG, Bali D, Carson JL, Sannuti A, Gipson CL, Ostrowski LEet al.; Discordant organ laterality in monozygotic twins with primaryciliarydyskinesia. Am J Med Genet.,1999; 82:155 – 600.
13. Jonsson MS, McCormick JR, GilliesCG, Gondos B;Kartagener's syndrome with motile spermatozoa. N Engl J Med.,1982;258:1329-1330.
14. Rajaram K, RamuS, PrabhakarR,Deivanayagam R,Ahamed M,Swaminathan T; Saccharin test of mucociliary clearance in kartagener's syndrome. Lung India, 1987, 5 (1): 33-35.
15. Skeik N, Jabr F; Kartagener syndrome. Int J Gen Med., 2011; 12(4):41-43.