

Acrospiroma (Nodular Hidradenoma) of the Thigh

Dr. Kuladeep Ananda Vaidya¹, Dr. Raghunath Prabhu^{2*}, Dr. Neha Kumar³, Dr. Sakshi Sadhu⁴

¹Assistant Professor, Department of Pathology, Srinivas Institute of Medical Science and Research Centre, Mukka, Mangalore, Karnataka-575021, India

²Assistant Professor, Department of Surgery, Kasturba Medical College, Manipal, Manipal University, Karnataka-576104, India

³Foundation year 1, UHNS, London, U.K

⁴Intern, Kasturba Medical College, Manipal, Manipal University, Karnataka-576104, India

*Corresponding Author:

Name: Dr. Raghunath Prabhu

Email: drraghu81@yahoo.co.in

Abstract: Acrospiroma or nodular hidradenoma is a rare benign neoplasm arising from the eccrine sweat glands. It usually presents as slowly enlarging, solitary, freely movable, solid or cystic swelling, frequently diagnosed from fourth to eighth decade of life. Herein we report a case of acrospiroma in a 50 year old male patient who presented with an asymptomatic, solitary swelling on the lateral side of upper thigh.

Keywords: Nodular hidradenoma, acrospiroma, benign neoplasm, eccrine sweat glands.

CASE REPORT

A 50-year-old man presented with a skin coloured nodular swelling on lateral side of his upper thigh (measuring around 4x3cm). It had been present for approximately 6 months and gradually increasing in size. The mass was brownish yellow, non-fluctuant, and mildly tender. A skin examination did not show any other lesions with the same features. No regional lymphadenopathy was detected. A provisional differential diagnosis was made of a sebaceous cyst. Fine needle aspirate of the lump yielded serous fluid mixed with blood. On Giemsa and Hematoxylin & Eosin (H&E) stained smears, a possibility of benign

skin lesion was made and a differential diagnosis of skin adnexal tumour was considered. Excisional biopsy of the mass was performed. Grossly tumour was unencapsulated measuring around 3x2x1cm, grey white to grey brown in colour [Fig 1]. Formalin fixed paraffin embedded routine H&E sections revealed lobules of tumour cells under the epidermis, having eosinophilic-cytoplasm, uniform round to oval nucleus, interspersed with collection of few cells having clear cytoplasm. No evidence of atypical mitosis or necrosis [Fig 2]. Histopathological impression of acrospiroma was rendered.

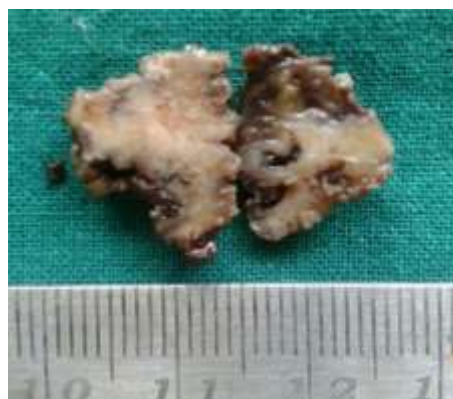

Fig 1: Cut section of the tumour is showing predominantly grey white areas with foci of cystic degeneration

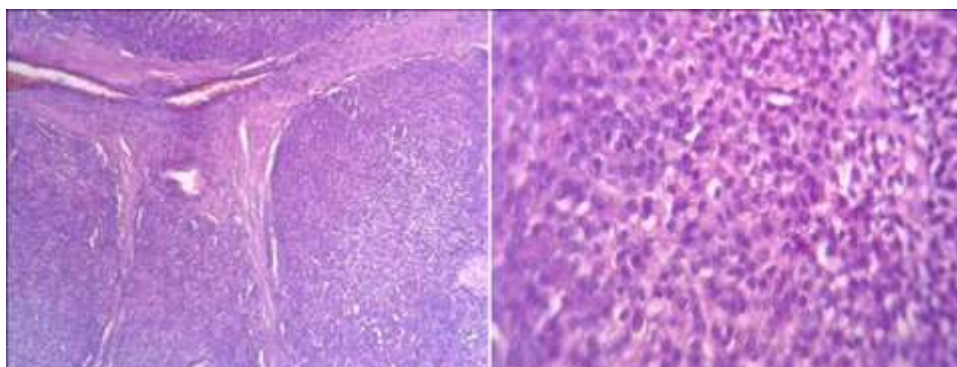


Fig 2: Lobules of benign tumour cells intersected by a thin fibrous septa, cells are with eosinophilic cytoplasm and round to ovoid nucleus (Lower magnification). Predominant cells are with eosinophilic cytoplasm and round to ovoid nucleus interspersed with few clear cells (Higher magnification)

DISCUSSION

Acrospiroma or nodular hidradenoma is also known as solid-cystic or clear cell hidradenoma and is a benign adnexal tumour arising from the excretory duct of eccrine sweat glands [1]. First reported by Keasby and Hadley in 1954 [2], it is often insidious in onset, freely mobile and can be solid or cystic. Usually measuring about 0.5-2cm in diameter, this lesion can occur anywhere in the body, such as, axilla, face, arms, thighs, scalp and groin, with the most common site being the head. It can occur at any age between third to fifth decades of life and is quite rare in children, with a higher affinity for women than men [3].

The lesion presents as an asymptomatic, skin coloured intradermal nodule, with slight induration [3]. It can be brown, blue or red with ulcerations in certain cases. Any rapid growth may indicate trauma, haemorrhage or a malignant change (especially a blue lesion found on microscopy) [4]. Clinically they are difficult to diagnose due to the lesion mimicking different benign and malignant tumours. Even dermoscopy is said to have little significance in this diagnosis [5]. Differential diagnosis includes basal cell and squamous cell carcinomas, melanoma, metastatic tumour, dermatofibroma, haemangioma, leiomyoma and other cutaneous tumours. Apart from this, there has been widespread debate about the exact criteria of a lesion to be classified as acrospiroma, with various reports using a wide range of histological features to encompass this entity.

The differentiation between the different terms associated with this type of lesion is done by biopsy with immunohistochemical staining or electron microscopy. Histologically, the tumour has tubular lumina with cuboidal and columnar cells. The solid component can often have polyhedral cells with basophilic cytoplasm and pale or clear cells with a clear cytoplasm and a nucleus [6]. Any atypical appearance, such as nuclear differentiation, mitotic figures and infiltrative patterns with lymph or perineural spread as well as necrosis suggest malignancy [6]. Besides this, some types of acrospiroma may or may not be attached

to the epidermis – epidermal acrospiroma (connected to the epidermis), eccrine poroma (juxta epidermal) or hidradenoma (eccrine acrospiroma or clear cell hidradenoma). Our case follows the third classification and was not connected to the epidermis.

Localised tumours are best managed by wide local excision [7]. Adjuvant chemotherapy and radiotherapy have only been proposed for malignant tumours and prognosis is generally poor in these patients with a five year survival of less than 30% [8]. Nevertheless, local recurrence rate can be variable, with 50% of the patients having local recurrence and 60% having metastases in 2 years [9] leading to the poor prognosis (may be observed following inadequate surgical resection as well) [10].

In conclusion, Acrospiroma is an eccrine sweat gland tumour, which is difficult to diagnose owing to wide histological appearances and their records. A better knowledge of the different presentations as well as keen clinical suspicion will help identify these lesions at an early stage, thereby possibly reducing chances of local recurrence and spread.

REFERENCES

1. Elder D, Elentisas R, Ragsdale BD; Tumors of the epidermal appendages. In David E editor; Lever's Histopathology of the Skin. Lippincott-Raven Publishers, Philadelphia, 1997: 747-804.
2. Keasby L, Hadley G; Clear cell hidradenoma: reports of three cases with widespread metastases. *Cancer*, 1954; 7: 934-952.
3. Biddlestone LR, Mc Laren KM, Tidman MJ; Malignant hidradenoma: a case report demonstrating insidious histological and clinical progression. *Clin Exp. Dermatol.*, 1991; 16: 474-477.
4. Gianotti R, Alessi E; Clear cell hidradenoma associated with the folliculosebaceous apocrine unit. *Am J Dermatopathol.*, 1997; 19: 351-357.
5. Nicolino R, Zalaudek I, Ferrara G, Annese P, Giorgio CM, Moscarella E *et al.*; Dermoscopy

- of eccrine poroma. *Dermatology*, 2007; 215(2):160–163.
6. Wilhelmi BJ, Appelt EA, Philips LG; A rare case of atypical eccrine acrospiroma of the scalp and a literature review. *Ann Plast Surg.*, 1999; 42: 568-569.
 7. Verret DJ, Kabbani W, DeFatta R; Nodular hidradenocarcinoma over the parotid gland: a pathologic presentation. *Head Neck*, 2007; 29:193-197.
 8. MaCalamont TH; A call for logic in the classification of adnexal neoplasm. *Am J Dermatopathol.*, 1996; 18:103-109.
 9. Wildemore JK, Lee JB, Humphreys TR; Mohs surgery for malignant eccrine neoplasms. *Dermatol Surg.*, 2004; 30:1574-1579.
 10. Volmar KE, Cummings TJ, Wang WH, Creager AJ, Tyler DS, Xie HB; Clear cell hidradenoma: a mimic of metastatic clear cell tumors. *Arch Pathol Lab Med.*, 2005; 129:113-116.