

Original Research Article

Study of Peroneal Perforators in Children (60 Children & 100 legs) With Hand Held Vascular Doppler Which Is Basis for Reverse Sural Artery Flap

Dr. Palukuri Lakshmi^{*1}, Dr. N. Naga Prasad^{**1}, Dr. Sreedharala Srinivasa Satyanarayana², Dr. C. Baliram^{***1},
Dr. Sugadha³, Dr. Sirisha¹, DR. Krishna Moorthy .V¹

^{1*}Assoc. Prof, ^{1**}Prof & HOD, ²Incharge Professor, ^{1***}Assistant prof, ³Assoc. Prof

¹Department of Plastic & Reconstructive Surgery, Osmania Medical College, Hyderabad, Telangana, India

²Department of Neurosurgery, Gandhi Medical College, Secunderabad, Telangana, India

³Department of Forensic Medicine, Gandhi Medical College, Secunderabad, Telangana, India

*Corresponding author

Dr. Palukuri Lakshmi

Email: lakshmi_ahlad@yahoo.co.in

Abstract: The incidence of trauma is on increasing trend as a result of raise in Road traffic accidents. Now a day the complex injury of lower limbs in children is not rare condition. Reconstruction of such injuries is a big challenge to plastic & reconstructive surgeons. Reconstructive options available for such defects are “Conventional Pedicle Flap “or “MICRO VASCULAR FLAP”. In adults- RSA or Ext. RSA Flap literally challenged the Microvascular flap & proved its merit as an alternate option. But “Is it safe in children” the question need to be addressed. Vascular basis for RSA flap is reverse flow of blood from peroneal artery perforators in lower third of leg near lateral malleolus into vascular plexus around sural nerve. Locations of peroneal perforators in adults were well described in the Literature but not in children. This study is conducted to find out the pattern of peroneal perforators in children. The objectives are to study the location of Peronealperf.in the distal leg within 5 cm in relation with tip of Lateral malleolus and to know the need of modifications of flap design & Safety of RSA / Ext. RSA flaps in the children. This a Prospective clinical study conducted at Our Institute (Osmania General Hospital) 60 children < 12 years who are normal & healthy included in the study & 100 legs were studied with hand held vascular doppler for location of peroneal perforators conducted between - Jan – July 2016. Children are divided into 4 groups depending on age (Group - I - 1-3 yrs, Group –II - 4-6 yrs, Group – III - 7-9 yrs, Group – IV - 10-12 Yrs) and following parameters noted and analyzed 1) The length of leg, 2) No. of peroneal perf. Within 5 cm in relation with tip of lateral malleolus, 3) Inter perforator distance (IP Dis), 4) Location of dominant or Robust perforator. These observations compared with cadaveric dissection & surgical findings. The no. of perforators within 5 cm – decreased from GR-I to GR-IV with advancing age but minimum 2 present in all children (unlike in Adults).The robust perforator is located very near to LM in GR-I at 3 cm migrated proximally to 5 cm in GR-IV- . RSA or Extended RSA flap are safer in Children than in adults in view of presence of minimum 2 peroneal perforators within 5 cm from lateral malleolus.

Keywords: Reverse sural artery flap, peroneal perforators, Ext. Reverse sural artery flap

INTRODUCTION:

The incidence of trauma is on increasing trend as a result of raise in Road traffic accidents. Now a day the complex injuries of lower limbs in children are not rare condition. Reconstruction of such injuries is a big challenge to plastic & reconstructive surgeons.

Reconstructive options available for such defects are “Conventional Pedicle Flap “or “MICRO VASCULAR FLAP”. In adults- RSA or Ext. RSA Flap

literally challenged the Microvascular flap & proved its merit as an alternate option. But “Is it safe in children”? Question need to be addressed.

Vascular basis for RSA flap is reverse flow of blood from peroneal artery perforators in lower third of leg near lateral malleolus to the median sural artery running along with sural nerve & vascular plexus around sural nerve. Location of peroneal perforators & design of RSA & Extended RSA flaps in adults were

well described in the Literature fig 1 &2 but not in children [1-3].

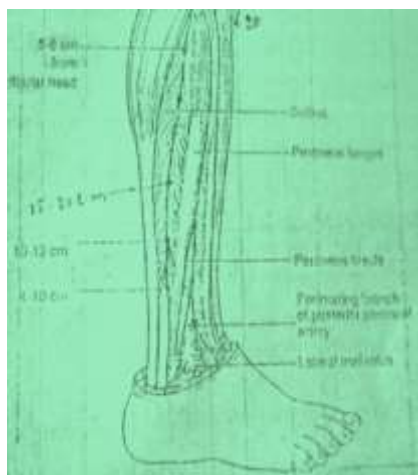


Fig 1: Pero perf. In adults

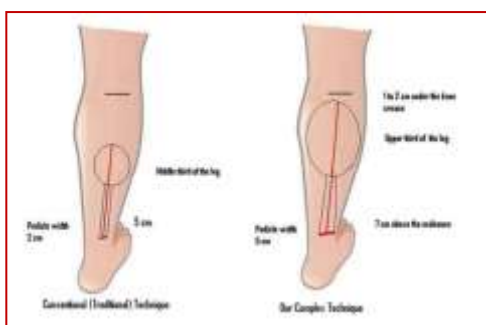

Fig 2: Design of RSA & Ext. RSA in adults

This study is conducted to find out the pattern of peroneal perforators in children.

AIM& OBJECTIVES OF THE STUDY

This is clinical prospective study conducted to know the

1) Location of Peroneal perforators in the distal leg within 5 cm in relation with tip of Lateral Malleolus

1) Modifications of flap design & Safety of RSA / Ext. RSA flaps in the children

(Un availability of above details in the literature review)

MATERIALS & METHODS:

This is a prospective clinical study conducted at Osmania General Hospital, Hyderabad over a period of 6 months from January – July 2016.

Inclusion Criteria: Normal healthy children < 12 years

Exclusion Criteria: Children which are not cooperative, Children having injury near lateral malleolus

Study size : 60 children & 100 legs for location of peroneal perf. With hand held vas. Doppler

RESULTS analysed& corroborated with CADAVERIC DISSECTION & SURGICAL OBSERVATIONS.

METHODOLOGY

Children below 12 Years (after necessary formalities) divided into 4 GROUPS based on age and 15 children & 25 legs were examined in each group with handheld vascular Doppler. Fig: 3 & 4

Group - 1 - 1-3 yrs, Group -II - 4-6 yrs,
Group - III - 7-9 yrs, Group - IV - 10-12 Yrs

Parameters noted are 1) The length of leg, 2) No. of peroneal perf. Within 5 cm in relation with tip of lateral malleolus, 3) Inter perforator distance (IP Dis), 4) Location of dominant or Robust perforator.

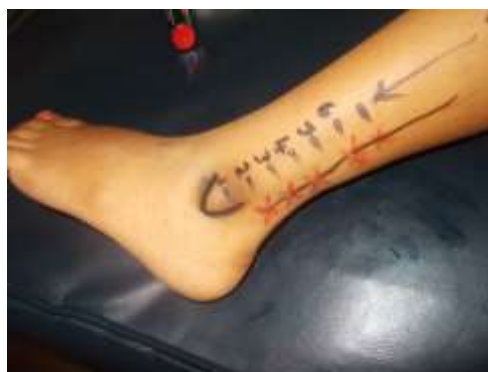

Fig 3: Peroneal perf. Marked from Tip of Lateral malleolus

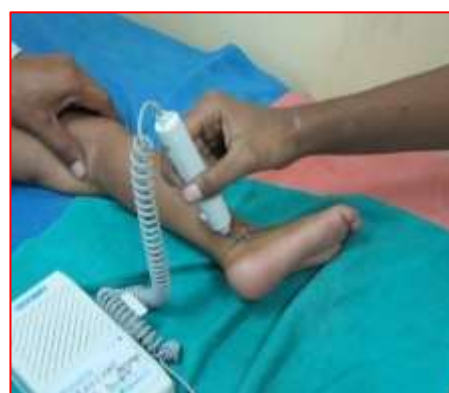

Fig 4: Localization of PP with Handheld vascular Doppler

OBSERVATIONS:

The observations are noted down in the table 1.

Table-1

S.No	Parameters noted	GR-I	GR-II	GR-III	GR-IV
1	Leg length	16-21	20-23	30 -32	38-40
2	No. of Peroneal Per. Within 5 cm from Tip of LM	4-5	3-4	2 - 3	2
3	Inter Perforator Distance (IPDis)	1 cm	1 cm	2 cm	2-3 cm
4	Location of Robust or Dominant Perf.	3 cm	3 cm	4.5 cm	4 / 5 cm

OBSERVATIONS OF CADAVERIC DISSECTION:

Cadaveric dissection was performed in 2 cases below 5 yrs Extended RSA flap was marked and elevated, Peroneal Artery dissected in upper 1/3rd of leg cut & vessel distal cut end cannulated with 20 G intracath & tied to prevent backflow of dye. Methylene blue injected into peroneal artery through intracath. Dye appeared in multiple peroneal perforators (within 5cm from tip of LM) entering into RSA flap. Fig: 5, 6, 7

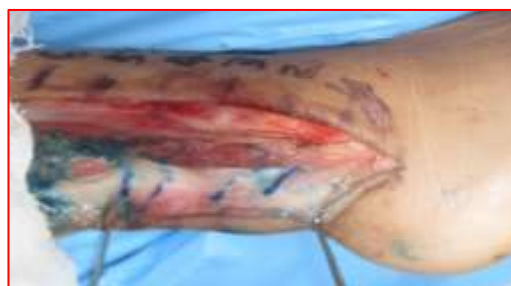

Fig 7: Dye appeared in the perf & flap

There are 2 Peroneal Perforators clearly seen within 5 cm from the tip of lateral malleolus.

SURGICAL OBSERVATIONS:

Extended RSA flap reconstruction was done for the large defect of ankle extending into dorsum of foot in 2 cases below 5 yrs age. 2 Peroneal perforators found within 5 cm from tip of lateral malleolus which were pre operatively marked with vascular Doppler. The perforators were present during surgery in same location. Flaps survived without any complication & covered entire defect and functional recovery was good.

- Additional findings noted during surgical procedure are multiple perforators found in lower 1/3rd leg. (Pre op localised with vas. Doppler) sub facial course of sural. N Is long in children in upper 2 / 3rd of leg. & Vas. Mysentery is very fine in inter muscular groove Fig .8,9,10

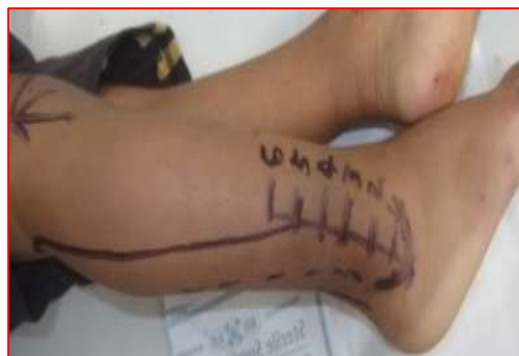

Fig 5: marking of ext. RSA flap

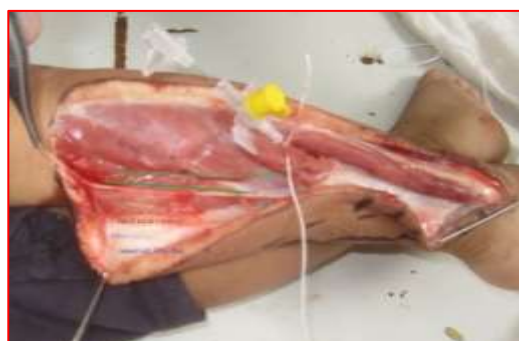

Fig 6: Flap elevated & peroneal artery dissected & cannulated

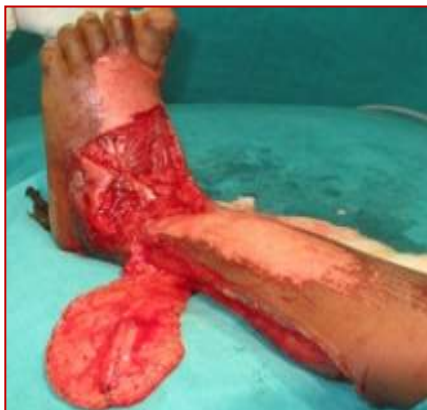

Fig 8: Median sural artery Along with sural nerve

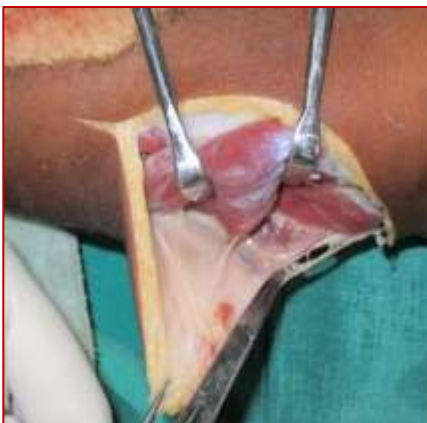

Fig 9: Vas. Mesentry in Intermuscular groove

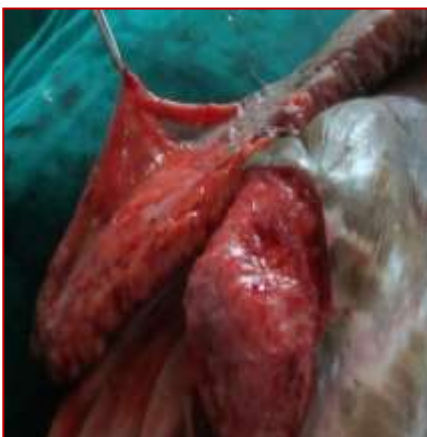

Fig 10: Mesentry like vas. Structure

DISCUSSION:

Soft tissue reconstruction of the lower third leg, ankle and foot region is a challenging problem. The major problem is the poor vascularity and limited mobility of the skin. Tendon, bone and hard ware are frequently exposed because of the thinness of

subcutaneous tissue making possibility of skin grafting a poor option. A durable flap with good skin texture, reliable vascularity, good arc of rotation, ease of dissection with minimum donor site morbidity is the most desired option for covering such defects.

Loco regional flaps for lower leg and ankle defects such as the peroneal artery flap, anterior tibial artery flap and posterior tibial artery flap [4-6] have the disadvantage of sacrificing a major artery in already traumatised limb. Supra malleolar flap [7, 15] is another option but its reliability is questionable in compromised vascularity. Morbidity and operative times are increased in technically demanding microvascular surgeries [8, 9]. Ideal flap thickness and quality, minimal donor site morbidity, the lack of functional loss, short recovery time, the wide arc of rotation and safe vascularity are the significant advantages of the reverse sural artery flap.

In this study the with hand held vascular Doppler {Table : 1} , it is noted that the no. of peroneal perforators within 5 cm – decreased with increasing age of child and length of leg 4-5 in GR-I decreased to 2 in GR-IV inferred as migration of perforators proximally with growing leg length in children.

The robust perforator is located very near to LM in GR-I at 3 cm migrated proximally to 5 cm in GR-IV- may due to increase of length of leg in growing children with age. In all groups minimum 2 peroneal perforators located within 5 cm from tip of lateral malleolus in children (unlike in adults only one perforator) which are good source blood supply to Reverse sural artery flap & Extended reverse sural artery flap Handheld vascular Doppler finding corroborated with cadaveric dissection & while doing Reverse & Extended Reverse Sural artery flap & confirmed.

These findings & observations were applied to safe designing of flap with less complication by following modifications in planning the flap in children. Fig: 11 &12

- Pivot point –Fixing of pivot Point at 3-5 cm from tip of LM after localizing including minimum of 2 P.P with vas. Doppler. (Unlike 5- 7 cm in adults)
- vascular axis - standard course of sural Nerve –by joining the point between tendoachillis and lateral malleolus & midpoint of popliteal crease
- Upper Limit of flap can be up to 2cm below the joint crease

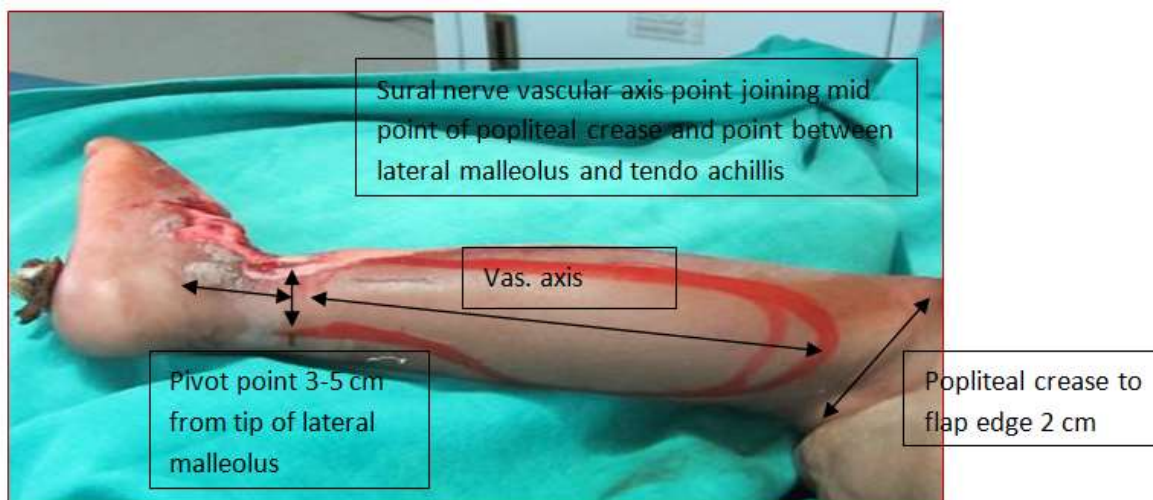


Fig 11: Designing of Extended RSA flap in Children

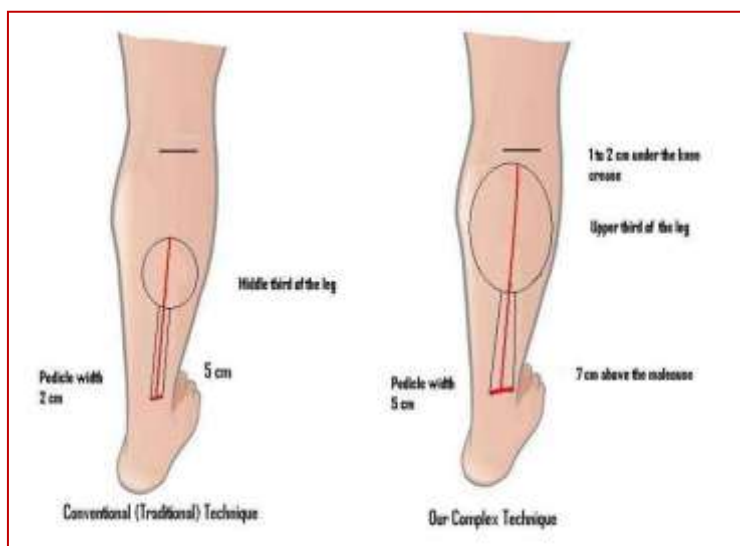


Fig 12: Design of RSA & Ext. RSA in adults (as given in literature)

Extended Reverse sural artery flap planned and performed in 2 children below age 5 yrs by designing the flap with above modifications and taking care to include sural nerve & vascular mesentery between 2 bellies of gastrocnemius muscle, pivot point at 5 cm

including the 2 peroneal perforators with preop localization with vascular Doppler. Fig 13 & 14. There were no flap complications. Wound healed well with good ankle function.

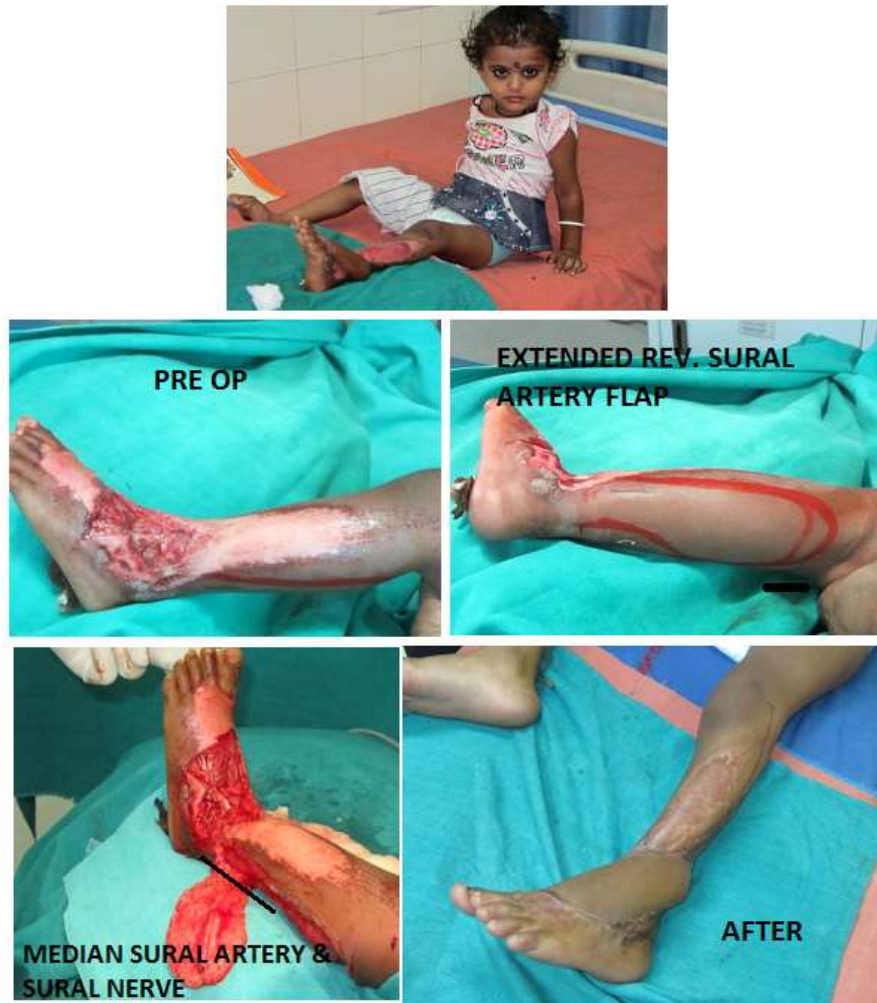

Fig 13: Child with large defect ankle& foot reconstructed with Extended RSA flap

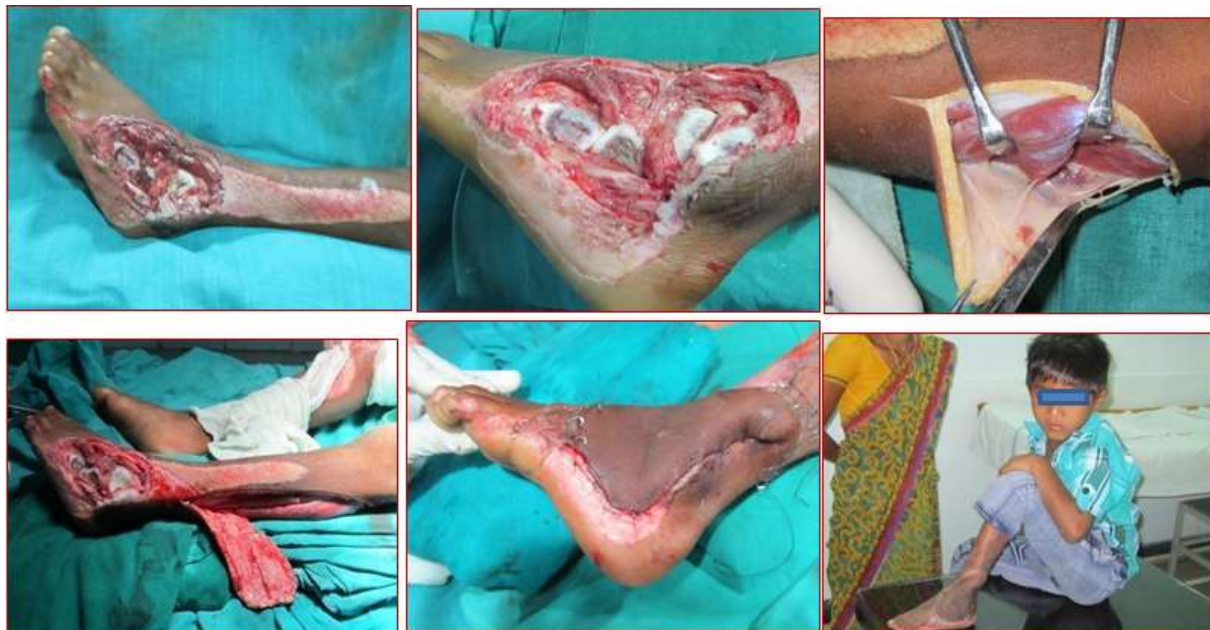

Fig 14: Child with large defect ankle & foot reconstructed with Extended RSA flap

CONCLUSIONS

1. This study concludes that RSA & EXT.RSA flaps are more safe & reliable in Children in view of presence of minimum 2 perf. Within 5 cm from lateral malleolus tip unlike in Adults.
2. Design modification of Ext. RSA flap is safely done by keeping pivot point at 4– 5cm including min. 2 perforators by locating with vascular Doppler pre operatively.
3. Careful dissection & inclusion of sural N along with vas. Mesentry in inter muscular groove,(in sub facial course) median sural A & short saphenous vein increases the safety of the flaps in children.

Conflicts of Interest

There are no conflicts of interest.

AKNOWLEDGEMENT

I express my sincere thanks to my post graduates, parents, Sons Ahlad. S, Ashish. K. My thanks to computer operators Raju, Prashanth, Fahad for helping me in preparation of this paper.

REFERENCES

1. Bertelli JA, Kaleli T. Retrograde-flow Neurocutaneous Island flaps in the forearm: anatomic basis and clinical results. *Plastic and reconstructive surgery.* 1995 Apr 1; 95(5):851-9.
2. Fachinelli A, Masquelet A, Restrepo J. The vascularized sural nerve. *Int J Micro surg* 1981; 3:57–62.
3. Masquelet AC, Romana MC, Wolf G. Skin island flaps supplied by the vascular axis of the sensitive superficial nerves: anatomic study and clinical experience in the leg. *Plastic and reconstructive surgery.* 1992 Jun 1; 89(6):1115-21.
4. Rajacic N, Lari AR, Khalaf ME, Kersnic M. Free flaps for the treatment of avulsion injuries in the feet. *Journal of Pediatric Orthopaedics.* 1994 Jul 1; 14(4):522-5.
5. Donski PK, Fogdestam I. Distally based fasciocutaneous flap from the sural region. *Scandinavian journal of plastic and reconstructive surgery.* 1983 Jan 1; 17(3):191-6.
6. Rajacic N, Gang RK, Krishnan J, Kojic S. Lower leg reconstruction using distally based saphenous island flap. *European Journal of Plastic Surgery.* 2001 Mar 2; 24(1):7-11.
7. Oberlin C, Azoulay B, Bhatia A. The Posterolateral Malleolar Flap of the Ankle: A Distally Based Sural Neurocutaneous Flap-Report of 14 Cases. *Plastic and reconstructive surgery.* 1995 Aug 1; 96(2):400-5.
8. Serafin D, Georgiade NG, Smith DH. Comparison of free flaps with pedicled flaps for coverage of defects of the leg or foot. *Plastic and reconstructive surgery.* 1977 Apr; 59(4):492-9.
9. Ponten B. The fasciocutaneous flap: its use in soft tissue defects of the lower leg. *British journal of plastic surgery.* 1981 Apr 1; 34(2):215-20.
10. Oberlin C, Azoulay B, Bhatia A. The Posterolateral Malleolar Flap of the Ankle: A Distally Based

- Sural Neurocutaneous Flap-Report of 14 Cases.
Plastic and reconstructive surgery. 1995 Aug 1;
96(2):400-5.
11. Hasegawa M, Torii S, Katoh H, Esaki S. The distally based superficial sural artery flap. Plastic and reconstructive surgery. 1994 Apr 1; 93(5):1012-20.
 12. Rajacic N, Darweesh M, Jayakrishnan K, Gang RK, Kojic S. The distally based superficial sural flap for reconstruction of the lower leg and foot. British journal of plastic surgery. 1996 Sep 30; 49(6):383-9.
 13. Masquelet AC, Beveridge J, Romana C, Gerber C. The lateral supramalleolar flap. Plastic and reconstructive surgery. 1988 Jan 1; 81(1):74-84.