

Original Research Article

Extended reverse sural artery flap with prior delay – an alternative to free flap in reconstruction of distal defect of leg & footDr. Palukuri Lakshmi¹, Dr. N. Naga Prasad¹, Dr. Sreedharala Srinivasa Satyanarayana², Dr. C. Baliram¹¹Asso. Prof., Department of Plastic & Reconstructive Surgery, Osmania Medical College, Hyderabad, Telangana, India²Prof. &HOD, Department of Neurosurgery, Gandhi Medical College, Secunderabad, Telangana, India***Corresponding author**

Dr. Palukuri Lakshmi

Email: lakshmi_ahlad@yahoo.co.in

Abstract: To reconstruct defects of the foot and ankle, the first option is free tissue transfer. However, a need of microsurgical expertise and a prolonged operating time remain its disadvantages. In 1992 Masquelet *et al.*, [2] described neuro skin island flaps, distally based sural artery and nerve flaps. The reverse sural artery flap eliminates the need for long and technically demanding free tissue transfers, which have become the gold standard for significant tissue defects in the distal third of the leg and ankle. Unfortunately, the originally described Reverse sural artery flap technique has a risk of partial or total flap necrosis as high as 25%. This risk increases if we extend the flap into proximal part of flap. Preoperative delaying the flap (1 wk to 10 days) may increase the safety & decrease the amount of partial necrosis that commonly occurs with this flap. We conducted this prospective clinical study at Osmania General Hospital from 2013 to 2016. Ten Patients with large, distal most defects of leg, ankle, and foot were taken up into study and reconstruction was done covering the defect with Extended Reverse Sural Flap with pre-operative delay. Ten patients ranged from 20-50 years of age had sustained defects in the distal leg, ankle, heel, foot region resulting from trauma. All wounds healed with favourable functional and aesthetic results without any evidence of major flap necrosis except for 1cm distal necrosis in 1 cases which were managed by debridement and skin grafting. This study conclude that the pre operative delay of Extended Reverse sural artery flap increases the safety of flap and decreases the complication related to Reverse Sural artery flap & also a better alternative to Free flap.

Keywords: Extended reverse sural artery flap, pre op delay, reverse sural artery flap

INTRODUCTION

Reconstruction of defects of lower third of the leg is challenging task to plastic & reconstructive surgeon. The anatomical features of the lower third of leg make the wound a complex problem. The fractures that occur in this region are often open due to the paucity of soft tissue around them. Lower third of leg consists of 2 bones, surrounded by multiple tendons and neurovascular structures- anterior tibial, posterior tibial, peroneal vessels in 3 different compartments and are draped by tight skin. Hence trauma to lower third of leg foot with loss or breach of soft tissue exposes the important structures tendons & bones.

The reconstructive options for lower third of leg range from perforator based flaps, propeller flaps & fasciocutaneous flaps but their reach to large distal most defects of leg & foot is difficult & are associated with

complications like partial necrosis and loss of flap. Free flap is an ideal & best reconstructive procedure for such type of defects however microsurgical expertise, a prolonged operating time, availability of infrastructure and 24 hours anaesthesia team support to deal the complications related to free flap being its limitations.

In 1992, Masquelet *et al.*, [2] described neuroskin island flaps, distally based sural artery and nerve flaps. Standard Reverse sural artery flap transferred from middle third of leg may fall short to reach the distal defects of leg, foot and is associated with complications like venous congestion & partial necrosis of flap. Location of the flap is a major limitation (the middle third of the leg). The proximal extension of the distally based neurofasciocutaneous sural flap has been considered to be random type of flap that provides a long length but

associated with complications. However, its survival is unpredictable [3, 4]. Extension of flap into proximal third of leg, keeping wide pedicle, supercharging by venous anastomosis have been tried to increase the flap survival and to decrease the complication rate.

In this study we have performed the preoperative delay procedure for extended Reverse sural flap apart from keeping its pedicle wide 5 cm and pivot point at 7 cm including 2 peroneal perforators and observed its effects on increasing the survival rate and decreasing the complications of Extended Reverse sural artery flap.

AIMS & OBJECTIVES OF THE STUDY

The purpose of this study is to evaluate the efficacy, success of pre operative delay in decreasing the complication rate of Extended RSA flap which was harvested with an additional extension into proximal third of the calf in order to reconstruct the distal defects of leg, foot, heel& around ankle joints.

MATERIALS & METHODS

This prospective clinical study was conducted in the Department of Plastic and Reconstructive Surgery, Osmania Medical College/Osmania General

Hospital, over a period of 3 years 2013 to 2016. Ten patients were included in this study that had soft tissue defects around ankle, Achilles tendon, heel, dorsum of foot. Mode of injury was RTA in all cases.

Exclusion criteria: All patients with scarring or wounds on the posterior calf or pedicle.

Out of ten cases four patients the defects had occurred in the ankle & heel (weight bearing) fig 1, they were too large to be covered by a standard sural artery flap from the middle third of the leg. In another three patients, defects had occurred in the ankle extending into foot; other three patients had defect on dorsum of foot, which were far away from reach of a standard sural flap. Some of these wounds were very large as well as distal, hence planned Extended RSA with prior delay. As we could not rely on the lowermost perforator obtained from the peroneal artery as the only blood supply to the flap pedicle, we shifted the pivot point of Ext, RSA flap from 5 cm to 7 to 8 cm to incorporate more perforators into the flap Fig. 1,2. Consequently, we had to shift the skin paddle to the proximal calf with preoperative delay of flap.fig 2,3,4 Remaining 2 cases had defect on the dorsum of the foot. Fig 5,6,7

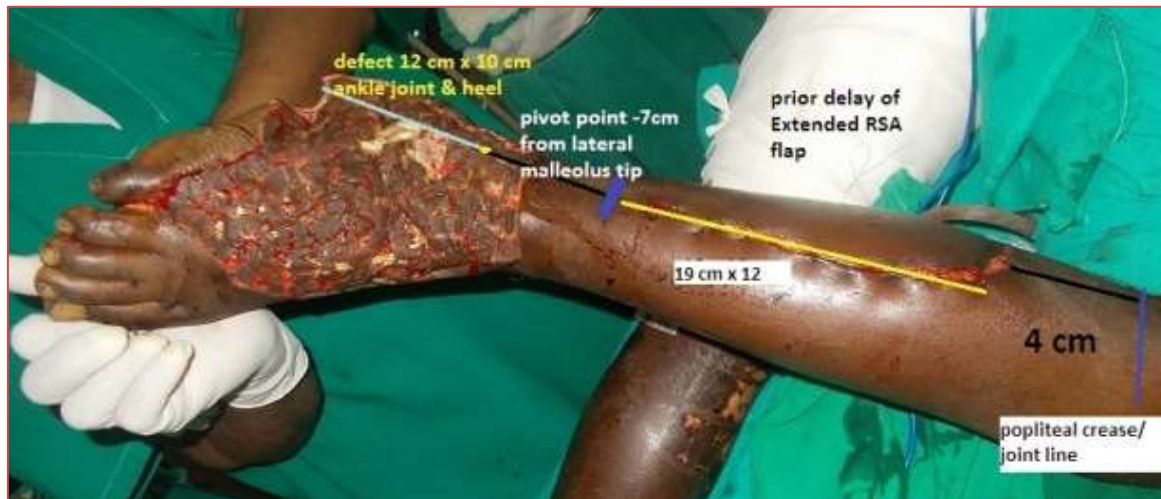


Fig-1: Planning of Preoperative delay of Extended Reverse Sural Artery Flap

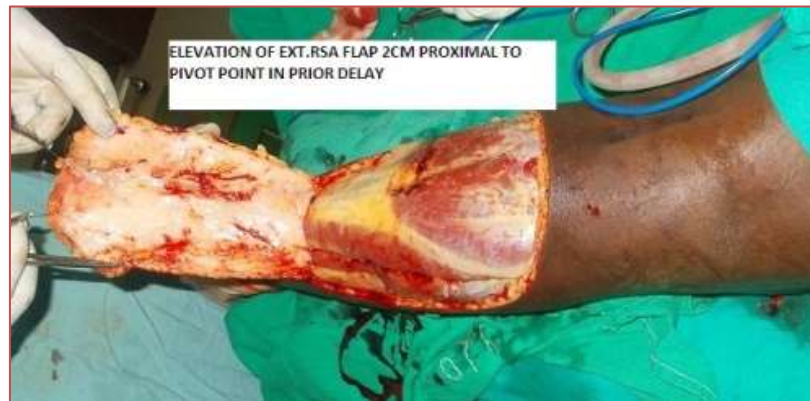

Fig-2: Elevation of the Extended RSA flap

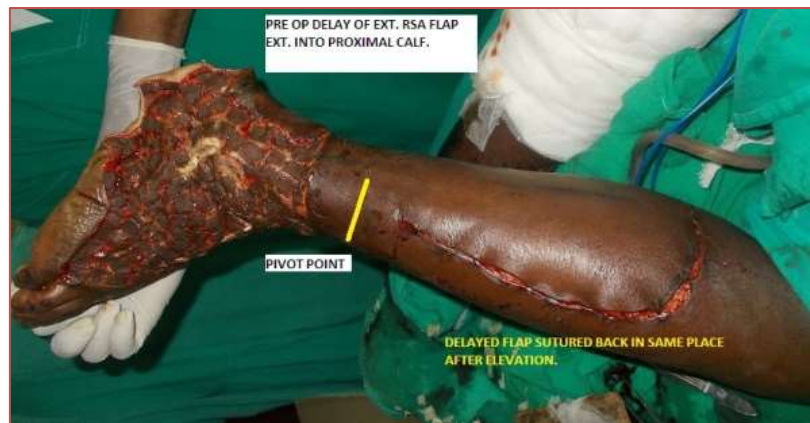

Fig-3: Resuturing of the flap to the donor site after preop delay

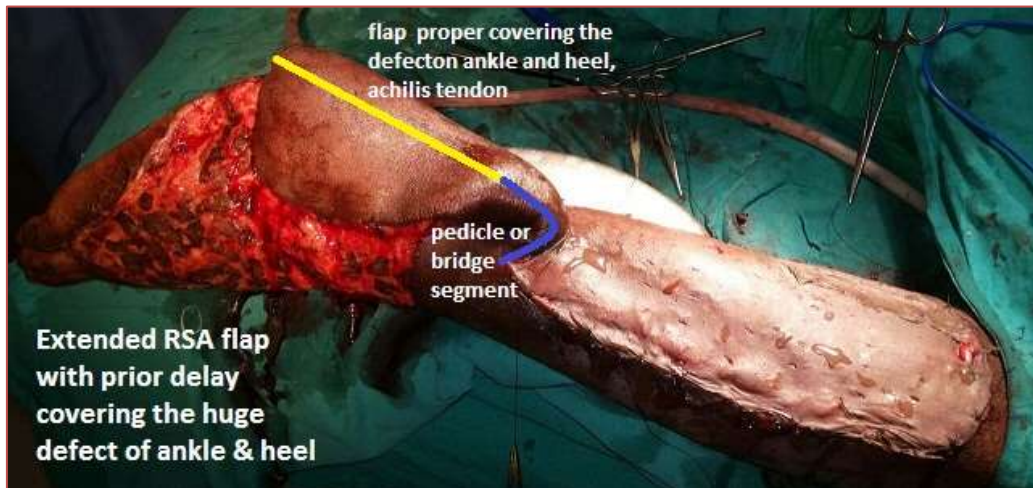


Fig-4: Transfer of the Extended RSA flap 1wk after delay to cover ankle defect

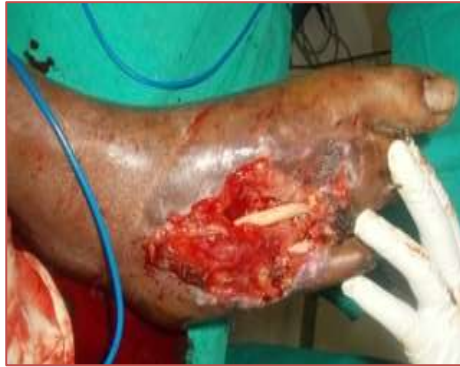

Fig-5: Distal defect of foot exposing tendon

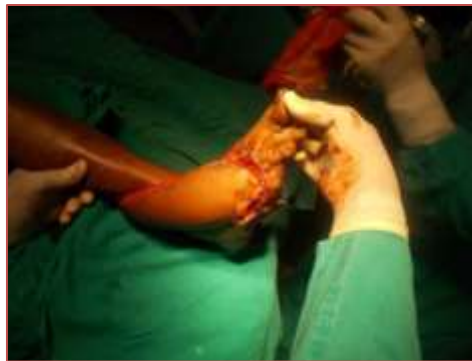

Fig-6: Post op reconstruction of dorsal defect Extended RSA flap with prior delay

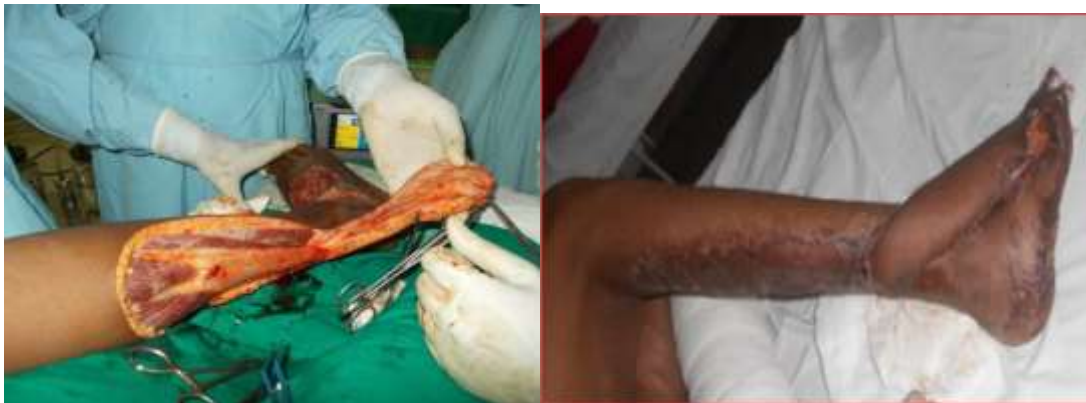

Fig-7: Pre op & post of Foot defect reconstructed with Ext.RSA flap with prior delay

#Ext: Extended, RSA – Reversed Sural Artery Flap

The demographic data of all cases, including age, gender, cause, size and site of the defect size of

flap, complication, and outcome are recorded shown in table below: (table1)

Table-1: Shown the demographic data of all cases, including age, gender, cause, size and site of the defect size of flap, complication and outcome are recorded

Pt. No.	AGE / Gender	Mode of injury	Site & size of the defect	Flap size & pivot point,	Complications	Outcome
1	M/ 35yrs	RTA	12 x 10cm ankle & achillis tendon	19x12 cm, Pp -7 cm Proximal ext. 6 cm	Nil	Good
2	Male/ 50 yrs	RTA	10 x 8 cm ankle & leg	17x10 cm, Pp – 7cm Proximal ext. 4 cm	Partial flap necrosis	Good after debridement & ssg
3	Male/ 40 yrs	RTA	9 x 8 cm ankle & heel	16x10 cm, pp- 8cm Proximal ext. 3 cm	Nil	Good
4	Male/ 30 yrs	RTA	10 x 9 cm ankle	17 x 11 cm, Pp-8cm Proximal ext. 4 cm	Nil	Good
5	Male/ 28 yrs	RTA	11 x 7 cm ankle & dorsum of foot	19 x 9 cm, Pp-8cm Proximal ext. 6 cm	Nil	Good
6	Male/ 32 yrs	RTA	10 x7 ankle & dorsum of foot	17 x8 cm, pp-8 cm Proximal ext. 5 cm	nil	Good
7	Male/ 28 yrs	RTA	9 x 6 ankle & dorsum of foot	16x7 cm, pp.8cm Proximal ext. 5 cm	Nil	Good
8	Male/ 52 yrs	RTA	8 x 6 cm, dorsum of foot	19 x7 cm, pp- 8 cm Proximal ext. 5 cm	Mild Venous congestion	Relieved with elevation
9	Male/ 54 yrs	RTA	7 x 6 cm, dorsum of foot	19 x 7 cm, pp- 8cm Proximal ext. 6 cm	Partial necrosis	Debridement ssg done
10	Male/ 25 yrs	RTA	6 x5 cm, dorsum of foot	15 x 6 cm, pp-8 cm Proximal ext. 4 cm	Nil	Good

#RTA- Road Traffic Accident, SSG – split thickness skin graft, pp –pivot point.

All cases with exposed bones or fractures were radiographed. Pre-operatively flap planned for the dimensions of the defect, level of proximal flap margin when it was designed on the leg (which would be the distal defect end when it was mobilized over the defect), when there is a need for Extended RSA we planned prior delay by raising the planned flap till 2 cm above the pivot point and re sutured in the same site. Every care was taken to include sural nerve & vascular mesentery between 2 muscle bellies, short saphenous vein, 2 lower peroneal perforators, and pedicle width is 5 cm while planning the flap. This delay will condition the arterial supply of flap and decrease the complication rate. After 1 wk, the flap transferred to defect and inset was given to defect edge. The flap was monitored for any venous congestion. The outcome was noted in terms of complete or partial flap survival, successful coverage of the recipient defect, and other complications.

ANATOMICAL BASIS OF FLAP DESIGN & OPERATIVE TECHNIQUE

An Extended RSA fasciocutaneous flap relies on the sural nerve vascular axis, which consists of the

median superficial sural artery, vessels along with short saphenous vein. This axis courses between the 2 heads of gastrocnemius muscle and its several cutaneous branches anastomose with approximately 3–5 septocutaneous perforators from the peroneal artery. These anastomoses ultimately form the reverse flow arterial supply of the reverse sural flap, which is located in the posterior crural septum, beginning 5 cm proximal to the lateral malleolus and extending proximally. Short Saphenous vein provides principal venous drainage of the flap. Its identification and distal preservation are vital for the success of flap. A reverse flow can occur due to the presence of bridging vena comitantes that by passes the venous valves. In addition, de-nervation of the veins, which occurs during flap elevation, causes valvular incompetence.

Pre operative evaluation included identification of the site of peroneal perforators, above the lateral malleolus by using a hand-held vascular Doppler. Two or three perforators were identified above the lateral malleolus. The axis of the flap was directed towards an imaginary line which connected the midpoint of popliteal fossa, to a point which was behind the lateral

malleolus. The flap was based distally with pivot point of Extended RSA flap was chosen according to the distal coverage requirement, but was limited by the 2nd lower-most perforator, at about 7 cm from lateral malleolus tip & Width of pedicle 5 cm and distal extent of flap up to 2 cm short of popliteal crease.

OPERATIVE TECHNIQUE

The procedure was done under spinal anesthesia, with patients in prone / semi prone or lateral position. A flap was marked as per the defect dimension as mentioned above, with 1 cm extra for flap contraction and a better tension free inset Fig-1. Dissection was started at the proximal border of the skin paddle. Sural nerve, artery and short saphenous vein were identified and they were ligated 1 to 2 cm proximal to the proximal border of the skin paddle, between two heads of the gastrocnemius. Sural nerve and artery are located deeper between the two heads of the gastrocnemius, while the lesser saphenous vein is mostly superficial. Utmost care was taken to expose and release the sural pedicle meticulously, by pushing the two heads of the gastrocnemius muscle aside gently, and keeping tiny perforators and accompanying vascular plexus intact, which were located in the loose fibro-adipo-areolar tissue, between the two heads of gastrocnemius. In wide flaps, the lateral sural nerve, if it was present, and its accompanying artery were also included in the flap. The flap was elevated along with fascia 2cm proximal to pivot point Fig 2 and the flap in re-sutured to the donor site Fig 4. After 1 wk the flap was transferred to the defect and raw area of the carrier pedicle and the donor site was skin grafted. Foot end elevation was provided in all the cases and pressure over the flap and grafted region was strictly avoided.

RESULTS

Over the period of 3 years, a total of 10 distally based Reverse suralfasciocutaneous flaps with pre operative delay performed on 10 patients. All (100%) patients were male. Their age ranged from 25 to 55 years. Road traffic accident was the cause of soft tissue defect in all cases. The site of the was dorsum of foot in 3 cases (30%) and ankle & extension into either dorsum of foot or tendo achillis or heel of foot or distal third of leg in 6 cases (60%) & ankle only in 1 case (10%). The ankle defects extended into heel in one case, into lower third of leg in in one case & dorsum of foot in one case. The leg defect exposed the fractured bone segment, heel defect exposed the calcaneum and ankle defect exposed the ankle joint & bones , Tendo achillis region defect exposed the Tendo achillis. All patients were referred to department of plastic Surgery after initial surgical debridement & stabilizing the fracture

segments in the department of Orthopedics within one wk of injury. Defects were reconstructed with extended reverse sural artery flap with prior delay.

A total of 10 patients had sustained injuries following road traffic accidents. Defect sizes ranged from 6 x 5 cm and 10 x 12 cm and sizes of flaps which were harvested, ranged from 15 x 6 cm to 19 x 12 cm (flap proper + pedicle). The following measurements were observed: the proximal borders of flaps: 4 to 5 cm from the popliteal skin crease, pedicle width; 4-5 cm, pivot point 7-8 cm proximal to lateral malleolus tip fig.1. Patients were followed up in OPD for 4 months to one year.

It was categorically found that none of the flaps had failed completely. Although two cases developed venous congestion which go relieved on conservative treatment elevation of leg , one case developed marginal necrosis with distal flap loss, which required debridement and split-thickness skin grafting.

Three cases (30%) out of 10 developed minor complications like venous congestion & distal marginal necrosis of flap. Venous congestion developed in two case (20%) which was relieved on elevation of the limb over pillows & one case (10%) developed distal partial necrosis of flap which required debridement & ssg. Nine cases (90%) had no problem. Donor site of Flap & SSG healed well without any problem. In all cases final result was good. Flap settled well.

DISCUSSION

Reconstruction of defects of lower third of leg, ankle, and foot is difficult task to any plastic and reconstructive surgeon. Unique anatomical features [1] of lower third of leg ankle, foot make the wound compound and complex exposing the important structure tendons, neurovascular structures, fractured bones. Simple skin grafting is not possible. The conventional fasciocutaneous, perforator flaps, propeller flaps harvested from middle third of leg based on perforators from posterior tibial, peroneal vessels in the lower third may not reach the distal defects of leg & foot. Free flap reconstruction is best options which are available. However, it has limitations of time, expertise and infrastructure requirement.

One of the difficult and demanding plastic surgery procedures is the complete and safe reconstructions of these defects in the absence of microsurgery facilities. Anatomical & vascular basis & designing of standard Reverse sural artery neurocutaneous flap was well described by Masquelet *et*

al., [2,3]. Proximal extension of the flap & various methods to increase the safety of the Extended reverse sural artery flap like 1) preserving & harvesting the miniature vessels which lie in a delicate fibro-adipose tissue between the two heads of the gastrocnemius muscle and a mesentery like structure connected to the deep fascia should be preserved and harvested along with the flap [4,5], inclusion of a gastrocnemius muscle “cuff” around the sural pedicle [6,7], delay phenomenon [8-10] supercharging of vein in venous congestion & including short saphenous vein were described by various authors [1].

In our study we have performed delay procedure for all extended reverse sural artery flap for reconstructing the large, distal defects of leg & foot apart from delicate dissection, preservation, harvesting of vascular mesentery into in upper third leg {in intermuscular groove}, keeping the pivot point at 7 cm, width of pedicle 5 cm, taking care to include short saphenous vein, pre operative localisation & inclusion of 2 peroneal perforators into the flap.

Preoperative delay of the flap allowed us to take with large dimensions 19x12cm by extending the RSA flap into proximal 1/3rd. This procedure increases axial blood flow into the flap by reverse flow through peroneal perforators into median sural artery & vascular plexus along the sural nerve. Choke vessels open up and improve the survival of the extended part of flap. Acclimatization of the flap to the blood supply after raising the flap will take place in this period. As the maximum effect of delay phenomenon is seen 7-10 days after delay procedure, flap was transferred & final inset was given at that time. Pre-operative delay procedure enhanced the survival of extended RSA flap in our study. No major complications were developed except for venous congestion in one case which was relieved by simple limb elevation & partial necrosis of flap in two cases which required debridement & skin grafting. Recipient site & donor site healed well without any complication.

Our results are almost same as that of the study conducted by Ramesha KT, Prakaskumar MN, Shankarappa M [12]. Who studied the Safety, Success and Efficacy of Extended Reverse Sural Artery Flap in reconstructing distal most defects of leg & foot on 18 cases by planning Extended RSA flap keeping pivot point at 7-8 cm from lateral malleolus tip, width of pedicle 5 cm and including short saphenous vein, sural nerve etc. we too followed the same planning in our cases & done preoperative delay in addition to above.

CONCLUSION

In our experience pre-operative delay of Extended RSA flap along with meticulous dissection, inclusion of vascular mesentery between 2 muscles in proximal leg, keeping pivot point at 8 cm including minimum 2 peroneal perforators, pedicle width 5 cm etc increased safety of flap. All patients underwent successful reconstructions with the use of Extended RSA flaps with prior delay, without any serious adverse events being reported.

From our study, we can say that use of extended RSA flap with prior delay is a safe, efficient and successful option which was worth considering. We conclude that it is a better alternative to free tissue transfers for large defect reconstructions of the distal leg & foot.

REFERENCES

1. Babu Bajantri, R. Ravindra Bharathi, and S. Raja Sabapathy, -Wound coverage considerations for defects of the lower third of the leg, Indian J Plast Surg. 2012 May-Aug; 45(2): 283–290
2. Masquelet AC, Romana MC, Wolf MD. Skin island flaps supplied by the vascular axis of the sensitive superficial nerves: anatomic study and clinical experience in the leg. *Plast Reconstr Surg.* 1992;89:1115–21.
3. Nakajima H, Imanishi N, Fukuzumi S, Minabe T, Aiso S, Fujino T. Accompanying arteries of the cutaneous veins and cutaneous nerves in the extremities: anatomical study and a concept of the venoadipofascial and/or neuroadipofascial pedicled fasciocutaneous flap. *Plast Reconstr Surg.* 1998;102(3):779–91.
4. Ayyappan T, Chadha A. Super sural neurofasciocutaneous flaps in acute traumatic heel reconstructions. *Plast Reconstr Surg.* 2002;109:2307–13.
5. Hassanpour S eyed-Esmail, Mohammadkhan Naser, Arasteh Ehsan. Is It Safe to Extract the Reverse Sural Artery Flap from the Proximal Third of the Leg? *Arch Iranian Med.* 2008;11(2):179–85.
6. Al-Qattan MM. A modified technique for harvesting the reverse sural artery flap from the upper part of the leg: inclusion of a gastrocnemius muscle “cuff” around the sural pedicle. *Ann Plast Surg.* 2001;47(3):269–74.
7. Al-Qattan Lower-Limb Reconstruction Utilizing the Reverse Sural Artery Flap–Gastrocnemius Muscle Cuff Technique. *Annals of Plastic Surgery.* August 2005;55(2)
8. Tosun Z, Ozkan A, Karaçor Z, Savaci N. Delaying the reverse sural flap provides predictable results

- for complicated wounds in diabetic foot. *Ann Plast Surg.* 2005;55(2):169–73.
9. Karacalar A, Idil O, DemirA, Güneren E, Simek T, Ozcan M. Delay in neurovenous flaps: experimental and clinical experience. *Ann Plast Surg.* 2004;53(5):481–7.
 10. Zink JR, Syed SA, Zahir K, Thomson JG, Restifo R. Transferring vascular territories from one axial pattern flap to another: a comparison of delay procedures. *Ann Plast Surg.* 1997;38(4):385–7.
 11. Imanishi N, Nakajima H, Fukuzumi S, et al. Venous drainage of the distally based lesser saphenous suralveno-neuroadipofascialpedicled fasciocutaneous flap: a radiographic perfusion study. *PlastReonstr Surg.* 1999;103:494–8.
 12. RameshaKT, Prakaskumar MN, Shankarappa M. Extended Reverse Sural Artery Flap's Safety, Success and Efficacy - A Prospective Study. *J Clin Diagn Res.* May 2014., V.8(5).