

## Original Research Article

**Study of Reconstruction of Scalp Defects at Osmania General Hospital****Dr. Palukuri Lakshmi<sup>1</sup>, Dr. N. Naga Prasad<sup>2</sup>, Dr. Sreedharala Srinivasa Satyanarayana<sup>3</sup>, Dr. Jyotsna<sup>4</sup>, Dr. C. Baliram<sup>5</sup>, Dr. Jaipal<sup>6</sup>**<sup>1</sup>Asso.Prof, Department of Plastic Surgery, Osmania Medical College, Hyderabad, Telangana, India<sup>2</sup>Prof.&HOD. Department of Plastic Surgery, Osmania Medical College, Hyderabad, Telangana, India<sup>3</sup>Incharge Professor, Department of Neurosurgery, Gandhi Medical College, Secunderabad, Telangana, India<sup>4,5</sup>Assistant prof, Department of Plastic Surgery, Osmania Medical College, Hyderabad, Telangana, India<sup>5</sup>Resident in Plastic Surgery, Gandhi Medical College, Secunderabad, Telangana, India**\*Corresponding author**

Dr. Palukuri Lakshmi

Email: [lakshmi\\_ahlad@yahoo.co.in](mailto:lakshmi_ahlad@yahoo.co.in)

**Abstract:** Scalp occupies the most prominent body part and possesses unique anatomical & aesthetic features. Scalp defects are scary to the novice to look at and to reconstruct. Gracefully guidelines do exist to accomplish this difficult task. Various Factors that influence the choice of reconstruction Careful analysis of the defect and local tissues can help to tailor the method of reconstruction and result in satisfactory closure in a majority of patients. To study the various scalp defects in terms of their clinical presentation, management and their outcome & comparison of our findings with others and our experience of reconstruction of scalp defects at our Institute. This prospective study includes 72 cases of scalp defects admitted to the department of Plastic and Reconstructive surgery, Osmania General Hospital, Hyderabad, Telangana during period from 2011 to 2015. Detailed analysis of these 72 cases with scalp defects is done in terms of 1.Age, 2.Sex, 3.Etiology, 4.Time of presentation, 5.Site of the defect, 6.Size of the defect, 7.Side of the defect, 8. Associated injuries, 9.Procedures done, 10.Timing of surgery, 11.Complications. 12.Duration of the hospital stay. Out of 72 cases of Scalp defects reconstructed male (88%) are more than female 12%, incidence is more in 21 -30 year group – 31%, Commonest cause is trauma RTA– 61%, Commonest site being – temporoparietal region – 45%, Commonest procedure done is local flap - 92%. One patients developed osteomyelitis of underlying bone which is managed by sequestrectomy and flap adjustment. Successful reconstruction of scalp requires detailed knowledge of scalp anatomy, skin biomechanics, the variety of available local tissue rearrangements etc. careful preoperative planning and precise execution.

**Keywords:** scalp reconstruction, transposition flap, rotation flap, galea aponeuritca

**INTRODUCTION**

Scalp occupies the most prominent body part and possesses unique anatomical & aesthetic features .It is described as an organ based on a rigid, flat aponeurosis and consisting of thick skin, penetrated by hair, nourished by a rich vascular network, situated in the subcutaneous tissue gliding over a thin sheet of pericranium. Most of the scalp is relatively inelastic, has a convex surface and repair of even a small defect is difficult. It is composed of hair bearing skin (temporal, parietal and occipital) and non-hair bearing skin (frontal).

Scalp defects are scary to the novice to look at and to reconstruct. Gracefully, guidelines do exist to accomplish this difficult task. Factors that influence the choice of reconstruction are size and location of the defect, the presence or absence of periosteum, the quality of surrounding scalp tissue, the presence or absence of hair & location of the hairline. Careful analysis of the defect and local tissues can help to tailor the method of reconstruction and result in satisfactory closure in a majority of patients.

Multiple reconstructive options exist that include primary closure, skin grafts, trephination, local tissue flaps with or without tissue expansion, regional

myocutaneous flap and microvascular free flap. Tissue expansion is one of the most important armamentaria for aesthetic scalp reconstruction. The arteries of the scalp originate peripherally and ascend to the vertex. Thus the main flaps used in scalp reconstruction have their base peripherally.

While considering reconstructive options, the plan must always be tailored to the individual patients needs and due attention be given to aesthetic outcome that specially includes preservation of hairline and hair follicle orientation, avoidance of alopecia. Although primary closure is feasible in some cases, the main stay of treatment involves local tissue rearrangement with or without split thickness skin graft. Early surgical attempt to cover the defect with a well-vascularized tissue provides excellent healing, osteogenesis, low rate of infection and requires no surgical debridement of the bone in the early phase and has a short hospital stay.

In this study we would like to present clinical observations made in regard to scalp defects admitted to our institute and comparison of our findings with others and our experience of reconstruction of scalp defects at our Institute.

#### **AIM& OBJECTIVES OF THE STUDY**

To study the various scalp defects in terms of their clinical presentation, management and their outcome & comparison of our findings with others and our experience of reconstruction of scalp defects at our Institute.

#### **PATIENTS & METHODS**

This prospective study includes 72 cases of scalp defects admitted to the department of Plastic and Reconstructive surgery, Osmania General Hospital, Hyderabad, Telangana during period from 2011 to 2015.

Patients admitted with electric burns were initially resuscitated from burn shock and after the

patient's general condition is stabilized, patients were taken up for surgery.

Patients admitted with scalp defects following trauma were thoroughly evaluated by for any associated injuries. Patients with associated injuries were treated for the conditions in the respective departments like neurosurgery, orthopedics and transferred to department of plastic surgery for reconstruction of scalp.

Detailed analysis of these 72 cases with scalp defects are done in terms of 1.Age, 2.Sex, 3.Etiology, 4.Time of presentation, 5.Site of the defect, 6.Size of the defect.7.Side of the defect, 8.Associated injuries, 9.Procedures done, 10.Timing of surgery, 11.Complications, 12. Duration of the hospital stay.

After the discharge patients were followed up initially twice weekly for 15 days followed by once a week for next one month and once in a month thereafter.

#### **APPLIED Anatomy of scalp [1-6]**

The skin layers of the scalp are easy to remember using well-known mnemonic SCALP (Fig 1&2)

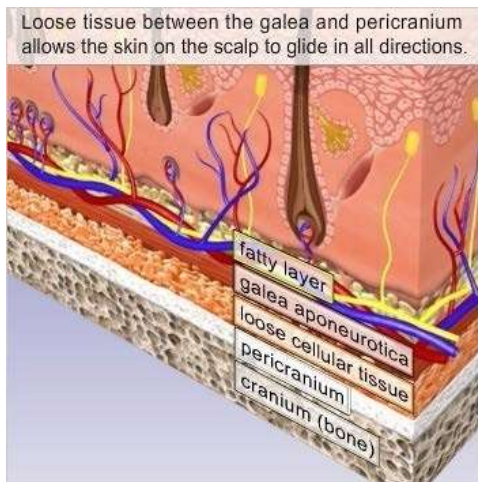
Skin is thick & less mobile. The parietal regions, located over the temporoparietal fascia are the areas of the scalp with the greatest mobility.

Connective tissue-subcutaneous layer lies superficial to the galea aponeurotica & well vascularised.

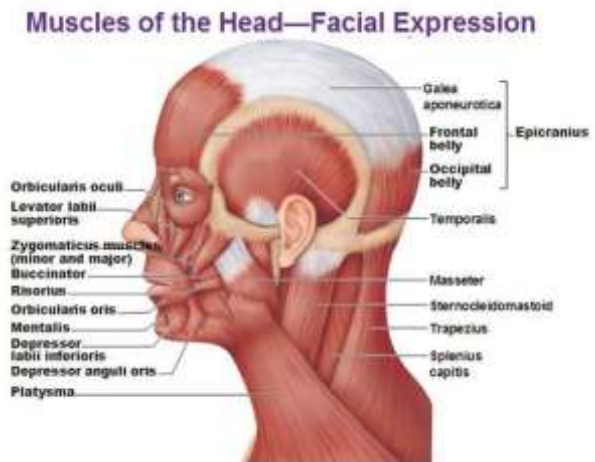
Galea Aponeurotica is poorly elastic – galeal scoring needed for expansion.

Loose areolar tissue - Sub galeal plane of elevation for local flaps / placement of Tissue expander.

#### **Pericranium: tough & non distensible**



**Fig:1: layers of scalp**



**Fig:2: muscles in aponeuritic system of scalp**

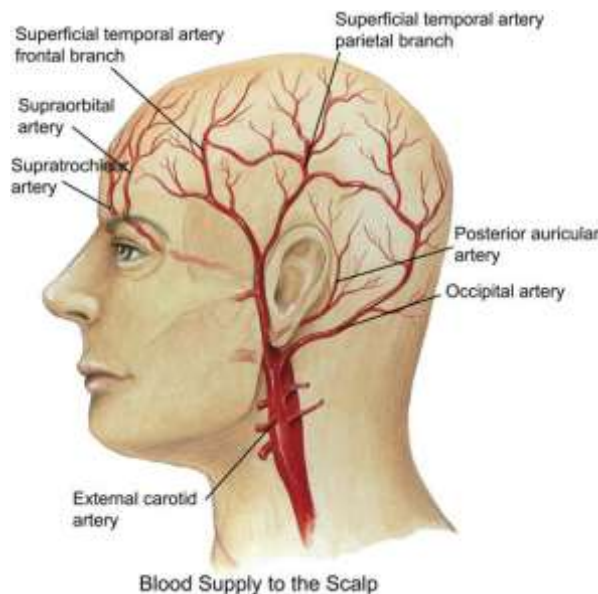
**Blood supply to scalp- fig. 3**

The vascular supply of the scalp consists of the paired

- supratrochlear,
- supraorbital - branch of the internal carotid artery
- superficial temporal,

- posterior auricular and
- Occipital - br.from the external carotid artery.

A robust choke vessel system allows relatively long local flaps to survive without distal necrosis.



**Fig-3: blood supply of the scalp**

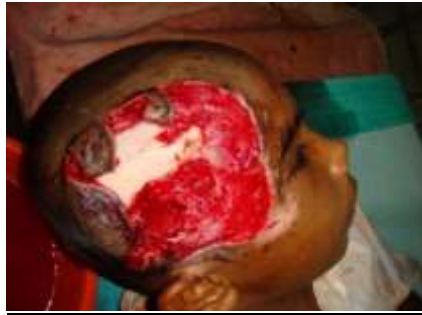**Review of guide lines OF RECONSTRUCTION**

Partial thickness defect with vascular bed – SSG

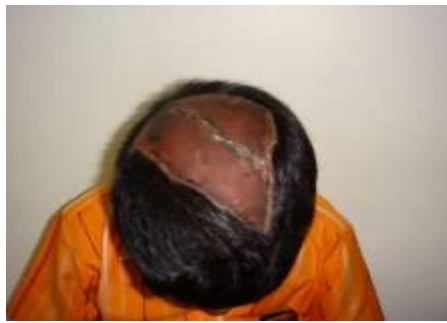Full thickness defect exposing bone – flap cover Fig:4,5,6

Base the flap such that the grafted area will be covered by the hair grown on the flap & adjacent scalp skin. Never breach hair line.

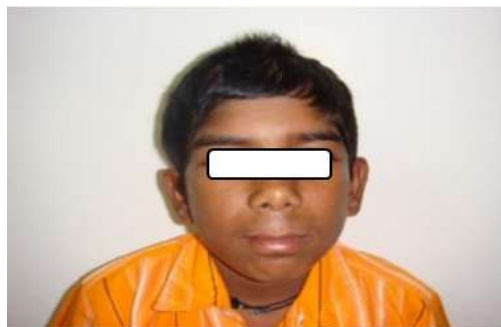Avoid putting skin grafting in occipital region to facilitate sleeping always try to plan secondary reconstruction by tissue expander to correct the alopeci.



**Fig-4: fullthickness scalp defect**



**Fig-5: post op transposition flap Top view**



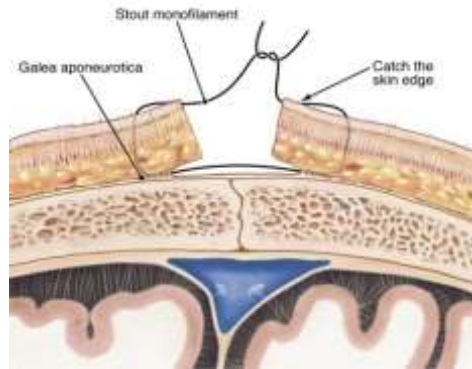
**Fig-6: Post op Front view No hairline breach**

**Scalp Reconstruction- Small & partial thickness defects fig. 7, 8, 9**

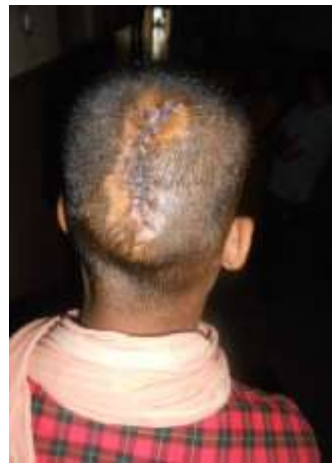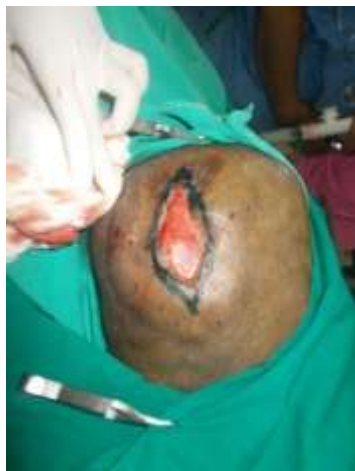- Primary Closure - typically less than 3 cm Diameter Undermine superficial to Galea

No buried sutures- just 3-0 Prolene vertical mattress sutures or staples (only if minimal tension)

- Second Intention – bald heads & superficial wounds Skin Graft - If pericranium intact



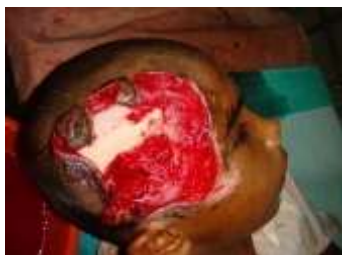**Fig-7: Pimary closure of scalp defect less than 3 cm**



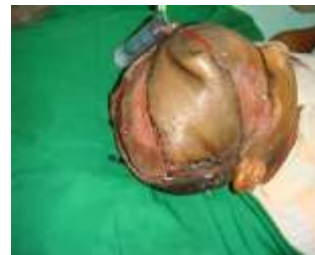**Fig-8 & 9: Pre operations**

**RECONSTRUCTION OF MEDIUM SIZE SCALP DEFECTS WITH LOSS OF PERICRANIUM  
Scalp Transposition flap: Fig-10,11,12,13**

It is a reliable flap but Leaves Pericranium at donor site which need SSG.



**Fig-10: Scalp defect exposing bone**



**Fig-11: Post op transposition flap +SSG**





Fig-12: Top view

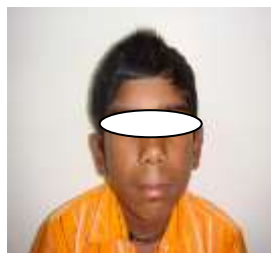

Fig-13: Front view

**BIPEDICLED FLAP SCALP RECONSTRUCTION (FIG 14, 15)**

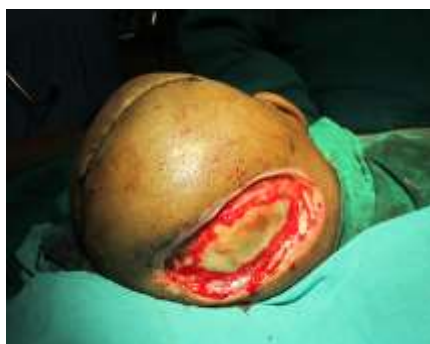

Fig-14: ELIPTICAL SHAPED SCALP DEFECT

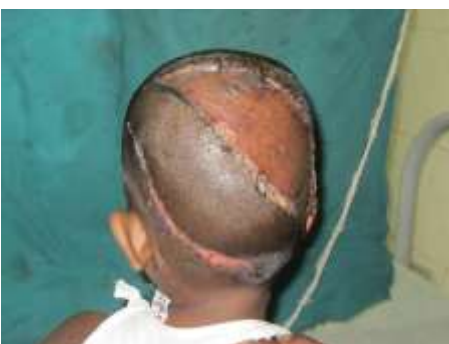

Fig-15: POST OP SCALP RECONSTRUCTION

**Scalp ROTATION FLAP (FIG- 16 TO 20)**

It is an excellent flap for hair bearing scalp. Donor site closure can be achieved primarily but needs cutting of large tissue, nerves, vessels.

Advantages of this flap are no alopecia, no donor site scar, no ssg

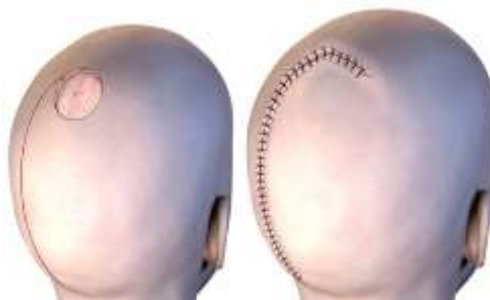

Fig-16: designing of Rotation flap for circular defect of scal

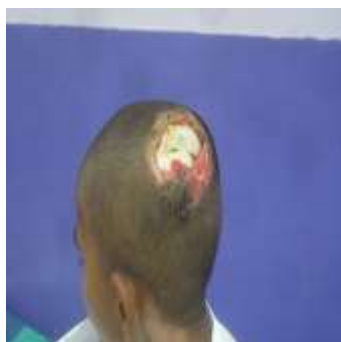

Fig-17: scalp defect

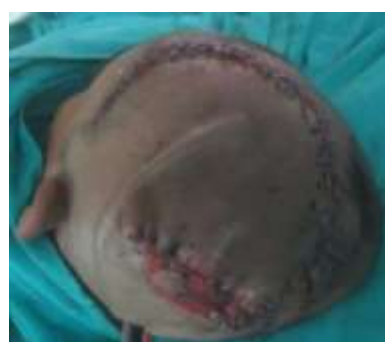
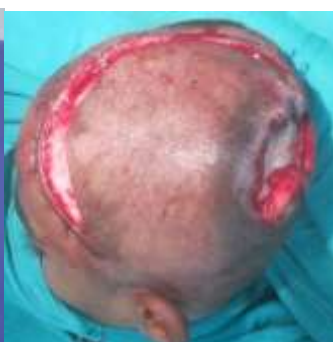
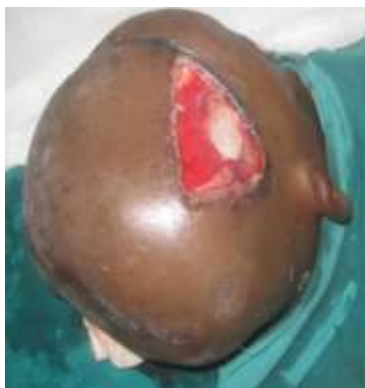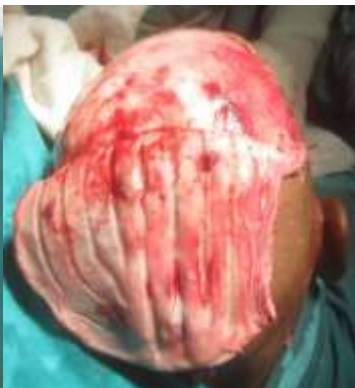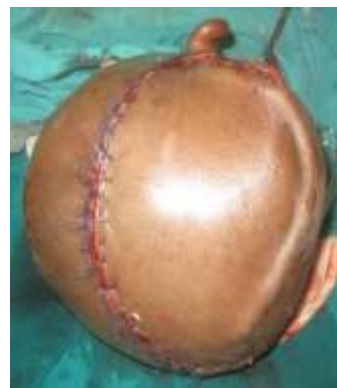Fig-18: Rotationflap reconstruction



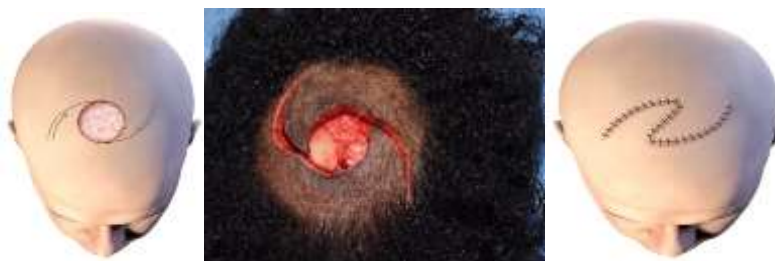**Fig-19: Scalp defect**



**Fig-20: Scalp rotation flap with galeal scoring**



Ying-Yang or O to Z Best for midline vertex defects not larger than 5 cm fig:21



**Fig-21: Scalp defect reconstructed by O-Z plasty**

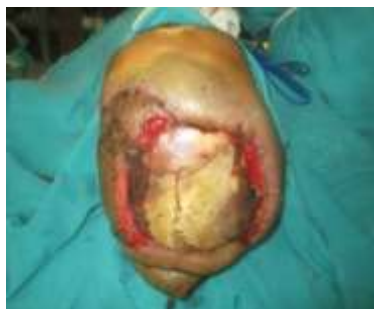**Scalp Reconstruction- Large defect**

- **Orticochea Banana Peel Flap**
- Free Tissue Transfer (FTT)
- Tissue Expansion / external device expansion
- Negative Pressure Wound Care ( Wound Vacuum device)  
Secure dressing

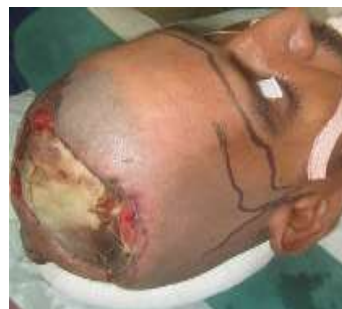Still takes a long time!  
Fairly expensive

**Orticochea Banana Peel Flap**

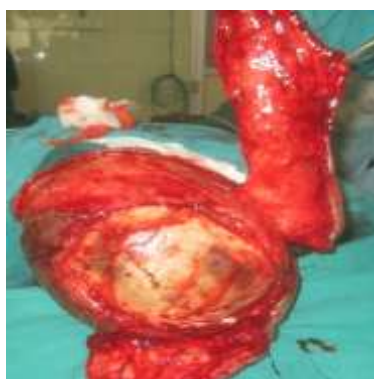- 3-5 flaps fig: 22,23,24,25
- Undermine and release lateral attachments to periosteum



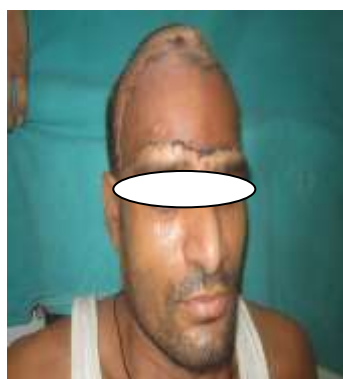**Fig-22: Large Scalp defect exposing bone**



**Fig-23: Multiple flap planned for the defect**



**Fig-24: Multiple flap raise to cover the defect**



**Fig-25: Post op rect. With multiple flaps**

**OBSERVATIONS & DISCUSSION [7-15, 17]**

The management of scalp defects remains a continuous challenge to the reconstructive surgeon. Scalp reconstruction differs from reconstruction elsewhere due to the rigid and inelastic nature of the scalp.

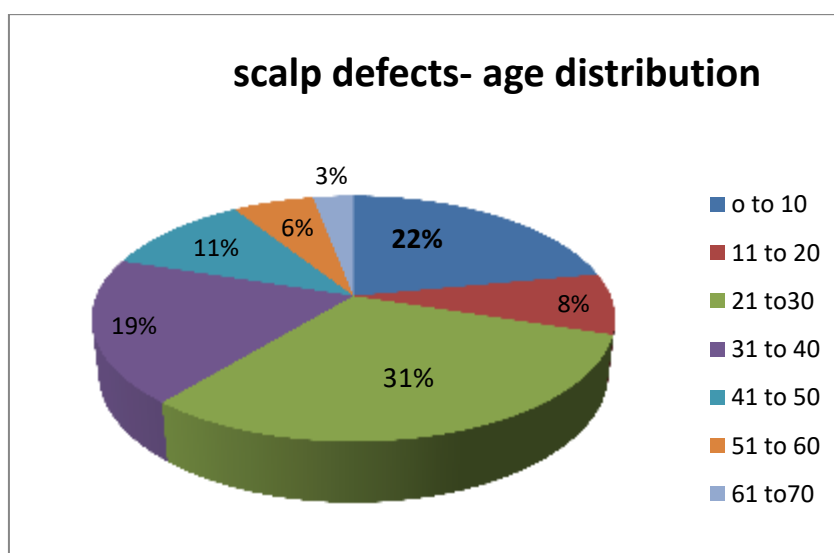
A total number of 72 cases with scalp defects were admitted between 2011 to 2015. The parameters as mentioned in the aim of study were studied in detail and compared with other studies.

**AGE DISTRIBUTION**

Our study Table -1 & pie chart -1

**Table-1: Age distribution**

Age at presentation	No. of patients	Percentage
0-11	16	22%
11-20	6	8%
21-30	22	31%
31-40	14	19%
41-50	8	11%
51-60	4	6%
61-70	2	3%



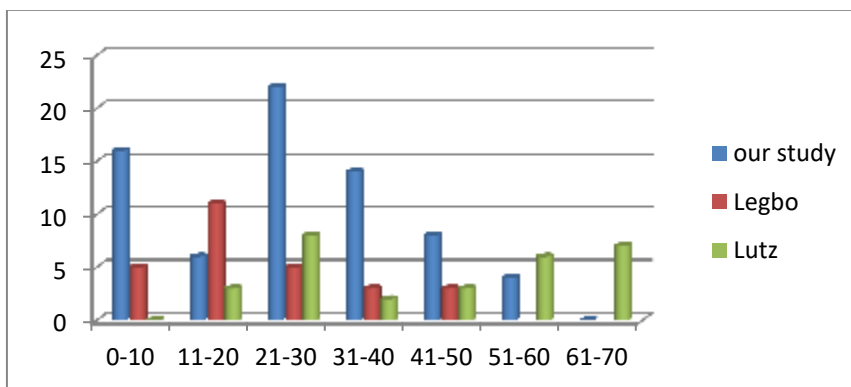
**Pie chart-1: Age distribution**



The common age group in our study is 21-30 years, with a mean age of 24.

**Comparative study**

**Bar chart-1**



**Bar Chart-1: Comparative study of Age distribution of Scalp defects.**

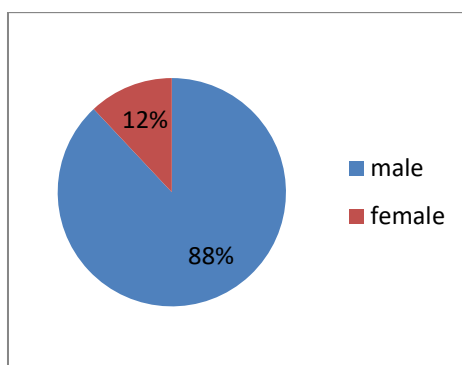
This is similar to Abdul Razak *et al.* study; the mean age in this study was 23.

In a study by Legbo and Shehu [1] on managing scalp defects, most of the patients were between 11-20 years. In our study there were 10

children of, which one was an infant, 9 were between 1-12 years, all of them presented following trauma. Our study shows that due increasing number of road traffic accidents, even younger children are prone to injuries one of which is scalp defect.

**SEX DISTRIBUTION**

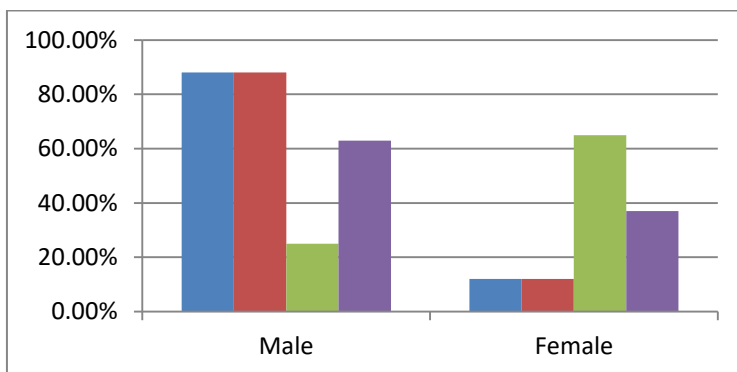
**Pie chart -2**



**Pie chart-2: Sex distribution of Scalp defects**

Most of the patients in our study are males that are 52/72 (88%), with a male to female ratio 2.8:1.

**Comparison of sex distribution Comparative Study of Sex distribution of Scalp defects**



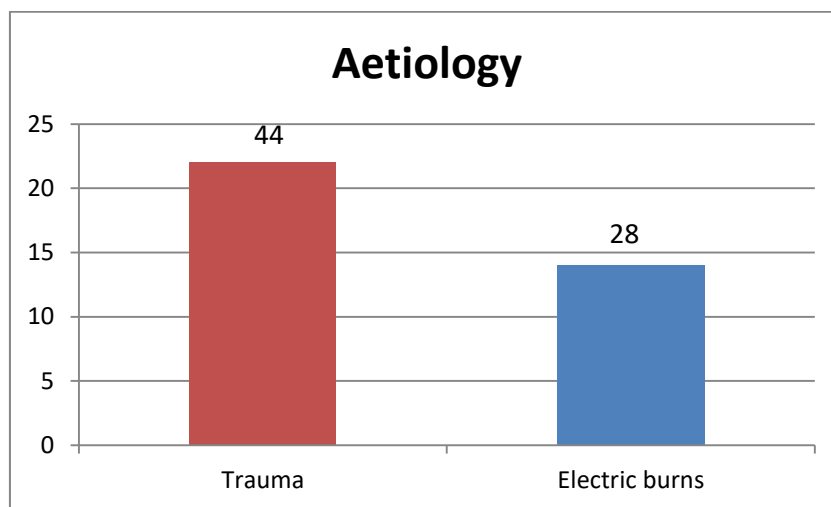
**Bar Chart-2: Comparative Study of Sex distribution of Scalp defects:**

Abdul Razak, Mahesh kumar *et al.* [2] study on scalp defects also showed male preponderance that is 28 (73%) were male patients out of 38 patients. In B.S Lutz study on reconstruction of scalp defects in 29 patients there were 19 males and 10 females. Feierbend, Bindra study also showed male preponderance with 63% males and 37% females. However, in Bhattacharya study on management of scalp injuries, the victims were predominantly young females

**ETIOLOGY OF SCALP DEFECTS**

**Bar chart -3, Table -2**

The common aetiology in our study is trauma in 44/72 cases i.e 61%. Of 44 cases, 36 are due to road traffic accidents and 4 are due to accidental fall. 28 patients had scalp defects following electric burns.

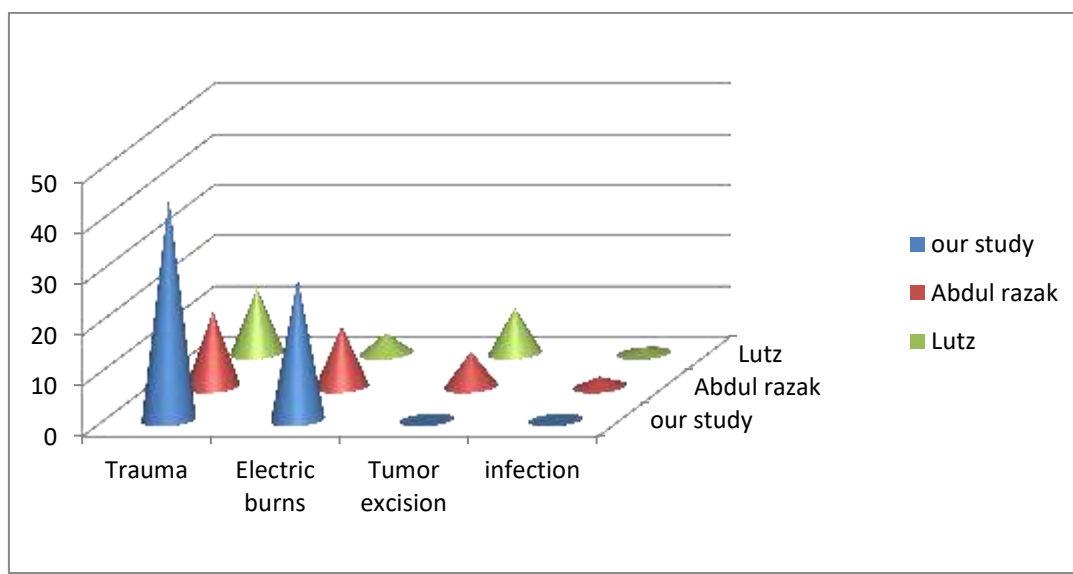


**Bar chart-3: Etiology of Scalp defects**

**Table-2: Etiology of Scalp defects**

Aetiology	No. Of patients	Percentage
Trauma	44	61%
Electric burns	28	14%

Comparison of aetiology



**Bar chart-4: Comparative study of scalp defects etiology**

As we have a separate institute for oncology, patients with malignancies go to that hospital for comprehensive management, hence our study doesn't have patients with malignancies. In Legbo study [1] also, road traffic accident was the commonest aetiological factor in 22(81.5%) patients followed by burns 2(7.4%) patients and scalp infection in one (3.7%) patient. In Abdul Razak *et al.* [2] study also trauma was the common cause 15(39%) cases, followed by electric injury in 8(21%) cases, benign & malignant lesions 8 (21%) cases, thermal burns 4(11%) cases. In B.S Lutz [3] study, scalp defects resulted from accidents 13 patients, electric burns 4 patients, tumor excision in 8 cases, chronic osteomyelitis in one case and

osteoradionecrosis in one case. In Camelia *et al.* [4] study 9 cases (64%) were due to scalp tumors and 5 cases (36%) were due to injury. The common aetiology in Cherubino *et al.* [5] study in an oncology centre was tumors 85% cases (BCC 47.5%, SCC-32.5 %) and other pathologies were 15%.

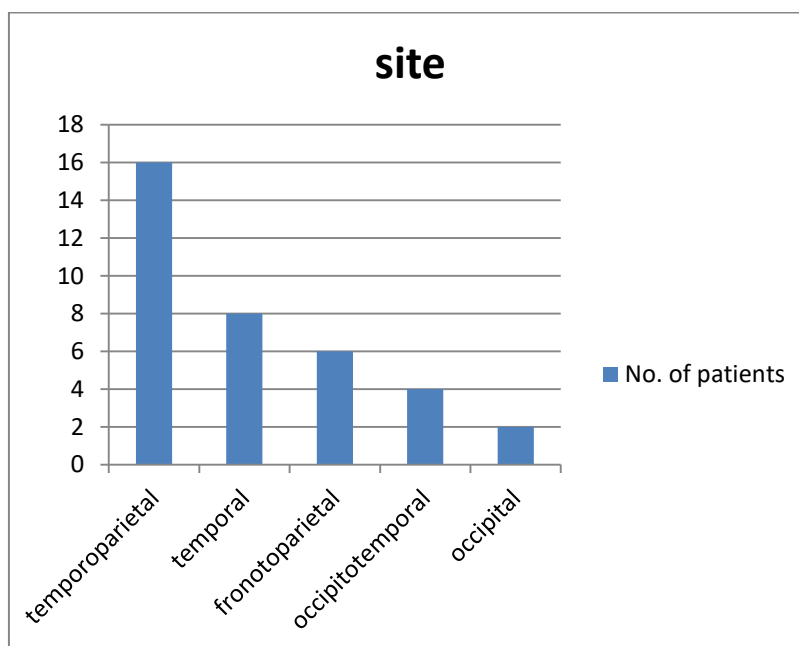
**SITE OF THE DEFECT**

**Table -3 Bar chart - 5**

In our series, 16 patients had temporoparietal scalp defects, 8 patients had temporal scalp defects, 6 patients had frontoparietal defects, 4 patients had occipitotemporal defects and 2 patients had occipital defects.

**Table-3: Site of the Defect**

Site	Number	Percentage
Temporoparietal	32	45%
Temporal	16	22%
Frontoparietal	12	16%
Occipitotemporal	8	11%
Occipital	4	6%



Bar chart-5: Site of the defect

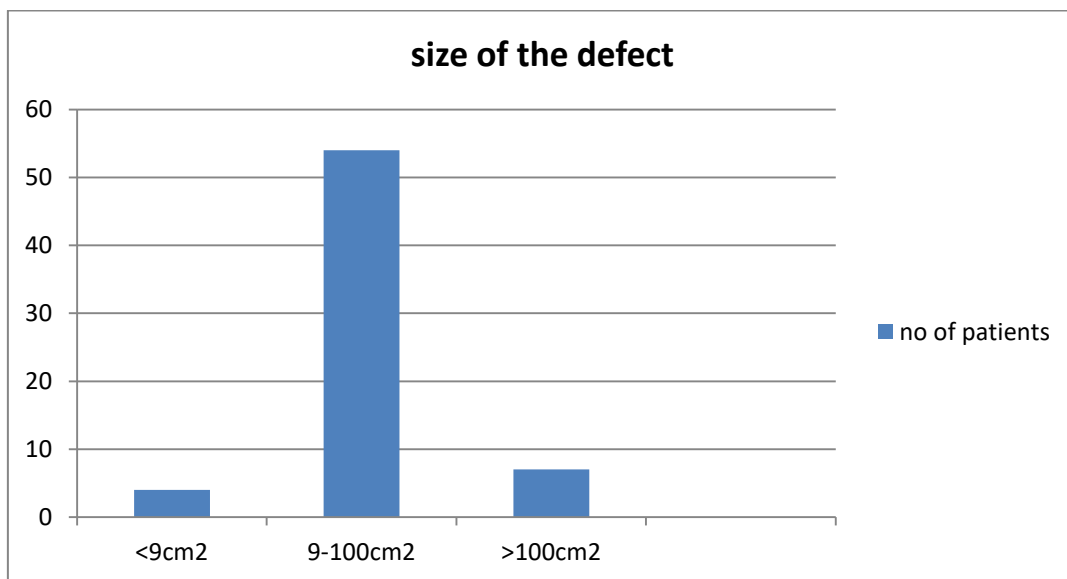
In our series, the commonest site for scalp defects is temporoparietal region. Out of 72 patients, 32 (45%) patients had temporoparietal scalp defects, 16 patients had temporal scalp defects, 12 patients had frontoparietal defects, 8 patients had occipitotemporal defects and 4 patients had occipital defects. J.N.Legbo [6] study also had temporoparietal region as the commonest site involved in 50% of cases. In Jae young et al study temporal region was more common in 5 patients followed by occipital area in 3 patients, frontal area in 1 patient, parietal area 1 case. In Wyllie E *et al.* [7] study the common sites were parietal followed by temporal regions.

#### SIZE OF THE DEFECT

The size of the defect in our study ranged from 9 sq.cm to 150sq.cm with an average of 70 sq.cm. In

Legbo [1] study the defect size ranged from 25sq.cm to 96sq.cm with mean of 64.3sq.cm. In Jae young study the average defect size was 120 sq.cm. In Wyllie [7] study the size ranged from 25 sq.cm to 140sq.cm. In Dalay *et al.* [8] study the average size of the defect was 89.45cm<sup>2</sup> for whom local flaps were applied, 193 cm<sup>2</sup> for free flaps and 143cm<sup>2</sup> for one treated with distant flaps.

All patients in our study had full thickness defects exposing the bone. Only one patient lost inner table in our study both following trauma exposing the dura with a bone defect of size 4sqcm. In Legbo [1] study 40.7% patients had bony loss which ranged from 14.6sqcm to 60.7sqcm.

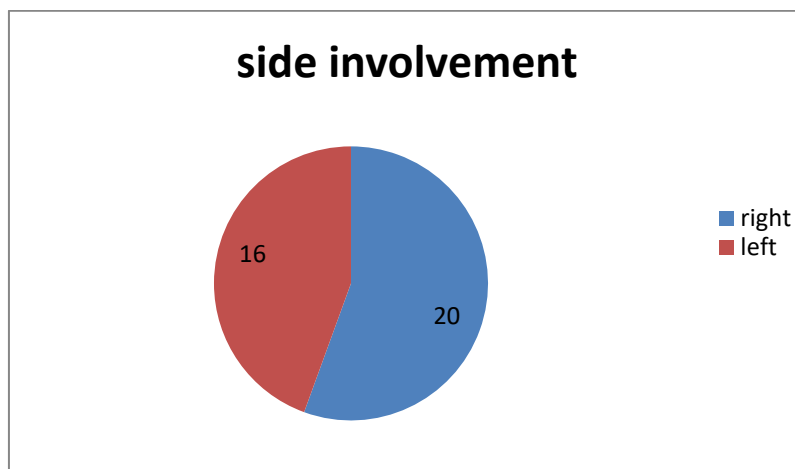


Bar chart-6: size of the defect

**SIDE INVOLVEMENT**

Pie chart-3

In our series, 40 (56%) patients had left sided involvement, 32 (44%) patients had right sided involvement.



Pie chart-3: Side of the scalp defect

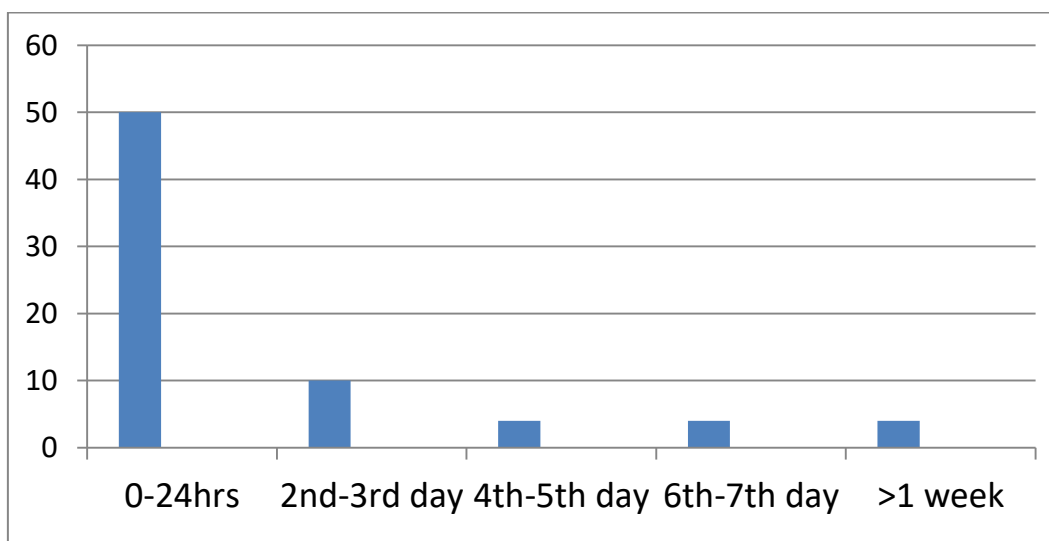
**TIME OF PRESENTATION**

Bar chart: 7

Of the 36 patients, 68 patients presented within one week (patients were treated elsewhere and were sent to Osmania hospital), 24 out of 28 patients with

electric burns presented within 24 hours and two patients presented late (three and a half months after electric burns). 26 patients of trauma presented within 24 hours, remaining 18 patients presented within 1 week.





**Bar chart-7: Time of Presentation Patient to the hospital**

**TIMING OF FLAP COVER**

The earliest flap cover could be given was within 24 hrs after trauma (when there was no associated injury) and 21 days after electrical burns.

The earliest flap cover was given within two days after trauma and 21 days after electric burns. In Norma et al study the earliest flap cover was given after 22 days following electric burns

**COMPONENT LOSS**

All patients had full thickness loss of scalp including the pericranium.

One of the two patients who presented late (three and half months) after electric burns, the outer table got osteomyelitic and separated with granulation tissue underneath and hence grafted.

**OPERATIVE PROCEDURES**

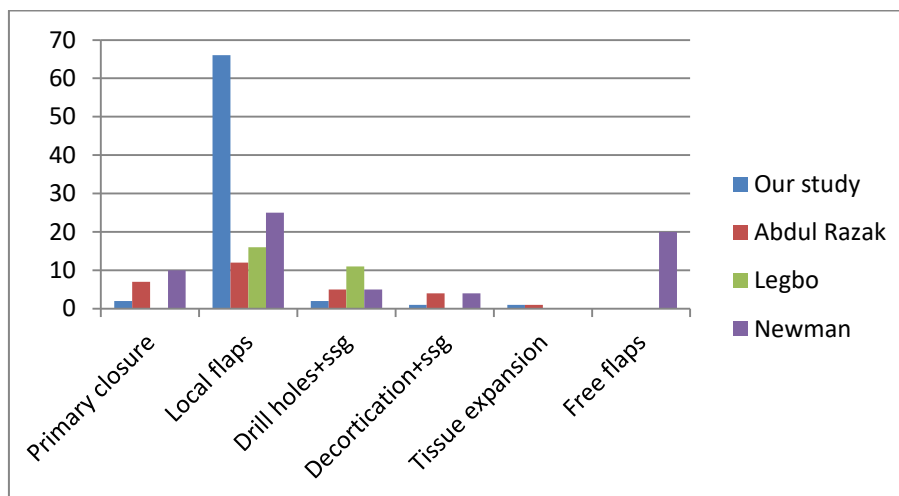
In our series, most of the patients 66 (92%) patients had Local flap cover (transposition flap-64 cases, rotation flap- 2 patients), Drill holes and SSG done in 2 (3%) patients, Decortication + SSG in 1 patients(1%), Primary closure with galeal scoring was done in 2 (3%) patients and Tissue expansion in 1 (1%) patient.

**Table-4: Operative Procedures done for Scalp Defects**

OPERATIVE PROCEDURE	NO. OF CASES	Percentage
Primary closure with galeal scoring	2	3%
Local flap cover	66	92%
Drill holes + ssg	2	3%
Decortication + SSG	1	1%
Tissue expansion	1	1%

Only one patient who presented late had osteomyelitis of the underlying bone, in which the necrosed bone removed and was covered with a skin graft.

Our results are in concordance to Abdul razak *et al.* [1] study in which local flap cover was the common operative procedure.



**Bar chart-8: Comparative Study of Reconstructive Procedures done for Scalp Defects**

In Abdul razak *et al.* [2] study done in 2010, local flap cover was given in 42% cases, outer table drilling and skin grafting was done in 31% cases. Skin grafting was done in 24% cases, primary closure was done in 17% cases and tissue expansion was done in 1 case. Bar chart: 8

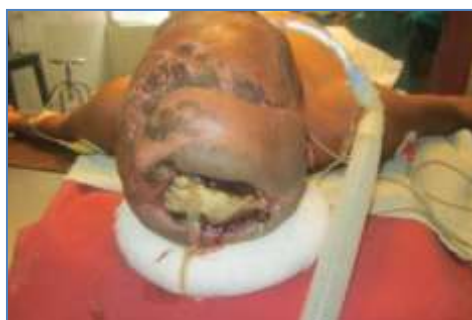In Legbo [1] study, 59% had local flap cover while the remaining 41% had split thickness skin grafting. In a study by Mueller CK and *et al.*, [9] a five year study from April 2005 to March 2010, 65 cases with scalp defects were studied. Local flaps were more effective than skin grafts ( $p=0.038$ ) and Microvascular free flaps ( $p=0.037$ ) in case of skin galea and periosteal defects. In Cherubino *et al.* [10] study, local flap cover was done in 37.5% cases, skin grafts in 35% cases, dermal regeneration plate in 20% cases primary closure in 17.5% cases and free flaps in 2 cases. In JPRS study on Management of large scalp defects with local pedicle flaps by Manikumari baswa [11] also, local flap cover is

the choice of reconstruction for scalp defects. In a BJPS study by Lutz [12] free flaps were done in all 30 cases.

In Feierabend study in 1985, chiselling of the outer cortex and covering with split skin grafting in 46 cases. Follow up revealed instability of the skin graft and also the danger of malignant transformation. According to Bhattacharya *et al.* [13] study done in 1982 on the management of scalp injuries, with intact pericranium, split thickness grafting remains the treatment of choice. In the presence of bare bone, local flap is preferred. If not the outer cortex is chiselled out or multiple drilling is done through it to accelerate the formation of granulation tissue. Subsequently, this is covered with split thickness skin graft.

**POST – OPERATIVE COMPLICATIONS: Fig:26**

Only one patient had partial loss of flap due to osteomyelitis of calvarial bone for which we have removed sequestered bone and local transposition flap done.



**Fig-26: Osteomyelitis of Skull bone after Scalp reconstruction with flap**

### HOSPITAL STAY

The shortest hospital stay was 12 days following trauma and 30 days following electric burns. The longest stay was 140 days (due to associated comorbid conditions).

The average hospital stay following electric burns is 55 days and 12 days following trauma, compared with that Normo study the average hospital stay was 30 days following electric burns. In Legbo [1] study, the duration ranged from 15 days to seven weeks with a mean of 3.5 weeks. Prolonged stay in our patients is because of associated injuries. Of the 22 patients following trauma, 14 patients had associated injuries. Associated injuries after trauma included head injury with loss of consciousness in 4 patients, 6 patients had fracture of the underlying bone, 2 patients had depressed bone fracture and 1 patient had EDH. 3 patients had upper limbs fractures which were treated in the orthopaedic department. 5 patients had soft tissue injury of the face. In Legbo [1] study, out of 22 patients involved in RTAs, 7 lost consciousnesses at the time of incident, 2 had long bone fractures.

### ASSOCIATED INJURIES

Of the 44 patients following trauma, 28 patients had associated injuries. 6 patients had fracture of the underlying skull bone, 2 patients had depressed bone fracture and 1 patient had EDH which 2 patients had full thickness defect exposing the dura. The bony defect was 2x2 cm in one case and 3x2 cm in another case. 3 patients had upper limbs fractures which were treated in the orthopaedic department. 5 patients had soft tissue injury of the face.

Of the 28 patients following electric burns, 10 patients had gangrene; upper limbs were involved in 8 cases and lower limb in 1 case. Amputation was done in all 10 cases. 3 patients had exposure of vital structures for which flap cover was done. Of the 14 patients, all the 12 patients who presented early, had burns to other parts of the body (flash burns/contact burns/arc burns/deep burns with gangrene). Of the two patients who presented late one had post burn raw area on the right arm for which grafting was done and the other had contracture of first web space.

### FOLLOW-UP

No morbidity was found other than alopecia. Dog ears settled well. Follow up of our patients was no more than six months as most of our patients are poor, illiterate and hail from remote places and did not return for follow-up

### CONCLUSIONS

Out of 72 cases of Scalp defects reconstructed male (88%) are more than female 12%, Incidence is more in 21 -30 yr group – 31% Commonest cause is trauma RTA – 61% Commonest site being – temporoparietal region –45% Commonest procedure done is local flap - 92%

Complications: One patients developed osteomyelitis of underlying bone which is managed by sequestrectomy and flap adjustment

Successful reconstruction of scalp requires detailed knowledge of scalp anatomy, skin biomechanics, the variety of available local tissue rearrangements etc. careful preoperative planning and precise execution allows satisfactory outcomes.

### REFERENCES

1. Legbo JN, Shehu BB. Managing scalp defects in sub-Saharan Africa. East African medical journal. 2004;81(2):87-91.
2. Memon AR, Kumar M, Shaikh BF, Qazi A. Surgical Reconstruction Of Scalp. Medical channel. 2010 Oct 1;16(4).
3. Lutz BS, Wei FC, Chen HC, Lin CH, Wei CY. Reconstruction of scalp defects with free flaps in 30 cases. British journal of plastic surgery. 1998 Dec 31;51(3):186-90.
4. Tamas C, Popa L, Turliuc D, Morosanu C, Lazar M, Vasilica E, Cazacu A, Anastasiu C, Taranu R, Stamate T. Surgical reconstruction in scalp defects. Jurnalul de chirurgie. 2005;1(2):196-9.
5. Cherubino M, Taibi D, Scamoni S, Maggiulli F, Di Giovanna D, Dibartolo R, Izzo M, Pellegatta I, Valdatta L. A New Algorithm for The Surgical Management of Defects of the Scalp. ISRN Plastic Surgery. 2013 Jan 21;2013.
6. Legbo JN, Shehu BB. Managing scalp defects in sub-Saharan Africa. East African medical journal. 2004;81(2):87-91.
7. Wyllie E, Chee M, Granstrom ML, DelGiudice E, Estes M, Comair Y, Pizzi M, Kotagal P, Bourgeois B, Lüders H. Temporal lobe epilepsy in early childhood. Epilepsia. 1993 Sep 1;34(5):859-68.
8. Dalay C, Kesiktas E, Yavuz M, Ozerdem G, Acarturk S. Coverage of scalp defects following contact electrical burns to the head: a clinical series. Burns. 2006 Mar 31;32(2):201-7.
9. Mueller CK, Bader RD, Ewald C, Kalff R, Schultze-Mosgau S. Scalp defect repair: a comparative analysis of different surgical techniques. Annals of plastic surgery. 2012 Jun 1;68(6):594-8.

10. Cherubino M, Taibi D, Scamoni S, Maggiulli F, Di Giovanna D, Dibartolo R, Izzo M, Pellegatta I, Valdatta L. A New Algorithm for The Surgical Management of Defects of the Scalp. *ISRN Plastic Surgery*. 2013 Jan 21;2013.
11. Baswa MK, Murmu LR. Management of large scalp defects with local pedicle flaps. *Plastic and reconstructive surgery*. 1994 Jun 1;93(7):1529.
12. Lutz BS, Wei FC, Chen HC, Lin CH, Wei CY. Reconstruction of scalp defects with free flaps in 30 cases. *British journal of plastic surgery*. 1998 Dec 31;51(3):186-90.
13. Bhattacharya V, Sinha JK, Tripathi FM. Management of scalp injuries. *Journal of Trauma and Acute Care Surgery*. 1982 Aug 1;22(8):698-702.