

Case Report

Management of Pseudo Class III malocclusion with Reverse Twin BlockDr. Nishant Negi¹, Dr. K. S. Negi²¹Lecturer, Deptt. of Orthodontics and Dentofacial Orthopedics, H. P. Govt. Dental College and Hospital, Shimla, Himachal Pradesh- 171001, India²Professor and Head, Deptt. of Orthodontics and Dentofacial Orthopedics, H. P. Govt. Dental College and Hospital; Shimla, Himachal Pradesh- 171001, India***Corresponding author**

Dr. Nishant Negi

Email: neginishant70@yahoo.in

Abstract: Class III malocclusion has been an enigma for Pediatric dentists and Orthodontists. Pseudo class III malocclusion are often accompanied with anterior cross bite, which if left untreated leads to accelerated occlusal wear, rapid periodontal destruction, TMD and irreversible skeletal changes progressing into full blown skeletal class III malocclusion. This case report describes the successful management of a young pseudo class III patient using Reverse Twin Block appliance.

Keywords: Pseudo class III, Anterior crossbite, Reverse Twin Block

INTRODUCTION

Moyer's suggested pseudo class III malocclusion as a positional malrelationship with an acquired neuromuscular reflex [1]. This malocclusion has been identified with anterior crossbite as a result of mandibular displacement. Premature contact between the maxillary and mandibular incisors results in forward displacement of the mandible so as to disengage the incisors and permit further closure into the position in which the posterior teeth can occlude. This malocclusion is also called postural or habitual class III malocclusion.

It has a reported incidence of 4-5% and is usually the result of a palatal malposition of maxillary incisors resulting from a lingual eruption path. Other etiologic factors include trauma to primary incisors resulting in lingual displacement of the permanent tooth buds, presence of supernumerary anterior teeth, crowding in incisor region, over retained teeth, delayed exfoliation of primary incisors and odontomas [2, 3].

Anterior crossbites requires early intervention as the mechanical interference by overclosure of the mandible may influence the growth of maxilla and alignment of dentition. The initial pseudo class III malocclusion if unattended can lead to true skeletal class III malocclusion. Also, early intervention in

youngsters reduces the psychological burden of facial and dental disfigurements during some of their most formative years [4].

Numerous appliances have been advocated for correction of cross bites [5]. Amongst them, the Reverse Twin Block (RTB appliance) is comfortable, esthetic, and efficient and considered as one of the most patient friendly appliance.

Diagnosis and etiology

A ten and half years old female patient presented with complaint of dissatisfaction with her appearance. She was in mixed dentition stage with angle's class I molar relationship on right side, posterior cross bite on left side, and reverse overjet and overbite of -2mm and -5mm respectively (Fig. 1). Cephalometric analysis revealed retroclined maxillary incisors, upright mandibular incisors, skeletal class I relation, normal maxilla and mandible with horizontal growth pattern (Fig. 2, table 1). There was no family history of class III malocclusion. Upon functional examination, there was anterior mandibular shift and patient was able to occlude in edge to edge incisor relationship when her mandible was retruded. She was diagnosed as having pseudo class III malocclusion due to functional shift of the mandible.

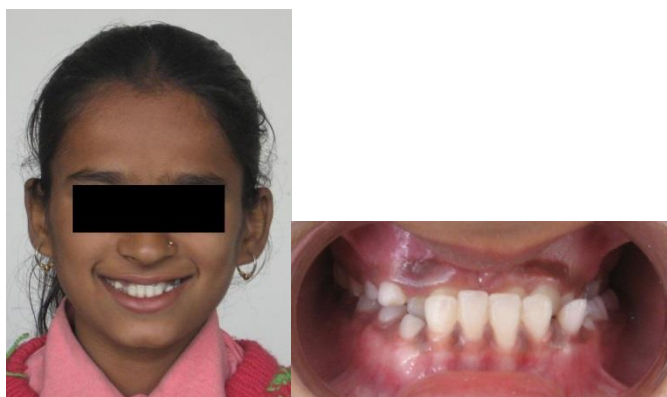

Fig-1: Pre-treatment photographs

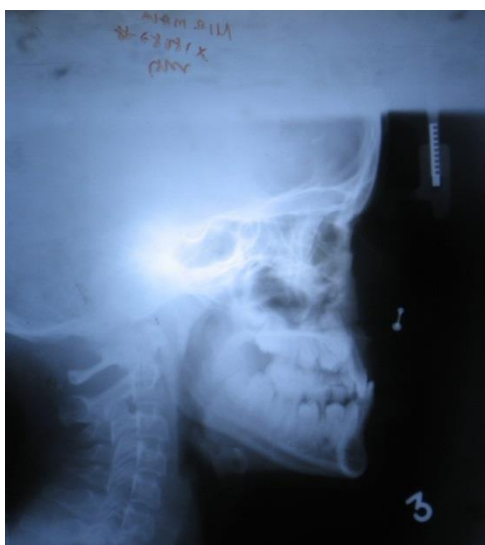

Fig-2: Pre-treatment radiographs

Table 1: Cephalometric measurements

Sr. no.	Measurement	Mean	Pre-treatment	Post-treatment
1.	SNA (°)	82	80	82
2.	SNB (°)	80	80	79
3.	ANB (°)	2	0	3
4.	Maxillary incisor to NA (°)/mm	22/4	11/1	21/3.5
5.	Mandibular incisor to NB (°)/mm	25/4	20/4.5	18/3
6.	Interincisor angle (°)	135	150	140
7.	Mandibular plane angle, FMA (°)	25	24	27
8.	Lower Incisor mandibular plane angle, IMPA (°)	90	88	84
9.	Steiner's S line to upper lip (mm)	0	0	2
10.	Steiner's S line to lower lip (mm)	2	4	3

Treatment objectives

Our primary objective was to attain normal overjet and overbite along with improvement in patient's profile.

Treatment alternatives

Treatment of true skeletal class III malocclusion warrants complex orthopedic (face mask, chin cup) and/or surgical approach. In contrast, pseudo class III malocclusion can be managed by correcting incisal malrelationships. Single tooth crossbite can be

managed by tongue blade or reverse stainless steel crown whereas crossbites involving multiple teeth requires removable appliances with screws/ springs or inclined plane. Fixed 2x4 appliance, w arch and quad helix have also been used for correcting crossbites. We decided to use RTB to achieve dental correction as well as orthopedic effects of increasing lower facial height in our patient.

Treatment progress

Construction bite was registered with incisors in edge to edge occlusion. RTB was fitted and prescribed for full time wear (Fig. 3). Patient was instructed to give one turn per week to three way expansion screw which was incorporated in maxillary appliance for sagittal and transverse expansion. To increase the forward movement of upper labial segment, lip pads were added in maxillary appliance. They were routinely adjusted so as to keep them clear of upper incisors. Total treatment time was eight months.

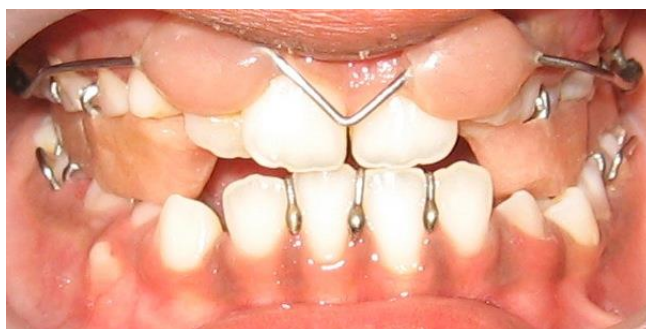

Fig-3: Stage photographs showing RTB

Treatment results

Cephalometric measurements and superimposition shows that the positive overjet and overbite was achieved by proclination of upper incisors and retroclination of lower incisors. In addition, there

was increase in lower anterior facial height. There was a noticeable improvement in patient's profile (Fig. 4, 5, 6). Patient was quite satisfied with the results obtained and rejected the option of fixed mechanotherapy for further detailing of occlusion.

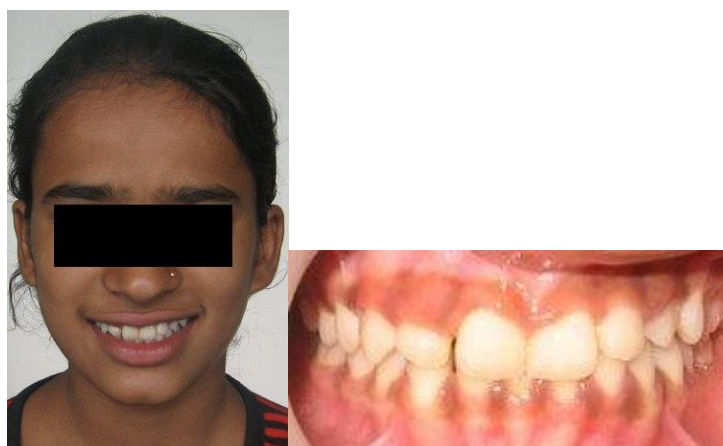

Fig-4: Post-treatment photographs

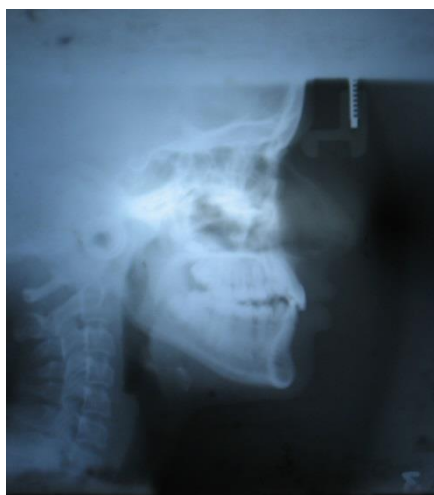

Fig-5: Post-treatment radiographs

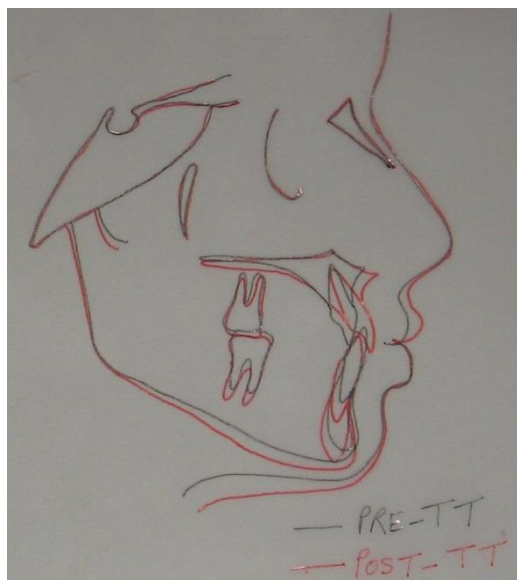


Fig-6: Cephalometric superimposition

DISCUSSION

Management of class III malocclusion remains a complex challenge. Anterior crossbite if not corrected has a functional appliance like effect causing excess growth of mandible and restricting normal development of the maxilla. In addition, untreated anterior displacements have been associated with rapid periodontal destruction, accelerated occlusal wear, and temporomandibular disorders. Early treatment of this malocclusion is advocated to create a favorable environment for future dentofacial development. Some authors suggest intervention in deciduous dentition period while others advocate intervention between 8-11 years of age when root is being formed and teeth are in active stage of eruption [6].

Differentiation that whether anterior crossbite is skeletal (true class III) or dental in nature (pseudo class III) is of prime importance. The path of closure of mandible from postural rest position to occlusion must be carefully studied. In pseudo class III malocclusion, the mandible slides anteriorly into forced protrusion because of premature contact and tooth guidance when jaw closes into full occlusion. In contrast, in true skeletal class III patient has an anterior rest position with respect to habitual occlusion [7]. Another key diagnostic feature in differential diagnosis is gonial angle, which is more obtuse in skeletal class III patients.

RTB is a simple, durable, versatile, and well tolerated appliance that can rapidly correct pseudo class III malocclusion with functional shift on closure [8].

The primary effects of RTB are dental, combined with minimal orthopedic changes [9]. This appliance was designed by Clark to achieve functional correction of class III malocclusion by reversing the angulation of inclined planes, harnessing occlusal forces as the functional mechanism to correct arch relationships by maxillary advancement, while using lower arch as the means of anchorage. RTB encourage maxillary development by the action of reverse occlusal inclined planes cut at a 70 °angle to drive the upper teeth forwards by the forces of occlusion and, at same time to restrict forward mandibular development [10]. Clark advocates that if patient can occlude squarely edge to edge on upper and lower incisors, the prognosis of anterior crossbite correction is good. If an edge to edge occlusion is achieved only with difficulty orthopedic correction using face mask should be attempted. If patient cannot close edge to edge on incisors it is likely that surgical correction would be required.

REFERENCES

1. Moyers RE. Handbook of Orthodontics. 4rd ed. Chicago: Year Book Medical Publishers Inc. 1973.
2. Major PW, Glover K. Treatment of anterior crossbites in the early mixed dentition. J Can Dent Assoc. 1992;58:574-5,578-9.
3. Bayrak S, Tunc ES. Treatment of anterior dental crossbite using bonded resin composite slopes. Case Reports. Eur J Dent. 2008;2:303-6.
4. Campbell PM. The dilemma of class III treatment. Early or late? Angle Orthod. 1983;53:175-191.
5. Seehra J, Fleming PS, Mandal N, DiBiase AT. A comparison of two different techniques for early correction of class III malocclusion. Angle Orthod 2012;82:96-101.
6. Kiyak HA. Patients and parents expectations from early treatment. Am J Orthod Dentofacial Orthop. 2006;129:s50-4.
7. Graber TM, Rakosi T, Petrovic AG. Dentofacial orthopedics with functional appliances. 2nd ed. Missouri: Mosby. 1997.
8. Chugh VK, Tandon P, Prasad V, Chugh A. Early orthopedic correction of skeletal class III malocclusion using combined Reverse Twin Block and Face Mask therapy. J Ind Soc Pedo Prev Dent. 2015;33:3-9.
9. Seehra J, Fleming PS, DiBiase AT. Reverse twin block appliance for early dental class III correction. J Clin Orthod 2010;44:602-10.
10. Clark WJ. Twin block functional therapy, applications in dentofacial orthopedics. 2nd ed. Mosby. 2002.