

The Risk of Acute Respiratory Distress Syndrome in Patients with Subarachnoid Hemorrhage, About A Case

Dr. Mohamed Mattous^{1*}, Dr. Nabil Jbili¹, Dr. Jaouad Laoutid²

¹Service de Réanimation Médicale de l'Hôpital Militaire Moulay Ismail Meknès Marocco

²Chef de service de Réanimation Médicale de l'Hôpital Militaire Moulay Ismail Meknès Marocco

DOI: [10.36347/sjmcr.2020.v08i02.040](https://doi.org/10.36347/sjmcr.2020.v08i02.040)

| Received: 09.02.2020 | Accepted: 16.02.2020 | Published: 28.02.2020

*Corresponding author: Mohamed Mattous

Abstract

Case Report

Aneurysmal arachnoid hemorrhage (AAH) is a rare disease common in the young female population and can cause many neurological complications, namely hydrocephalus, vasospasm and rebleeding. However, it can also lead to extra neurological complications, including cardiovascular failure, renal failure, metabolic disorders (hypokalaemia, hyperglycemia, dysnatremia) and acute respiratory distress syndrome (ARDS). We report a case of a 50-year-old patient who developed ARDS during her hospitalization in the resuscitation department for an AAH. The occurrence of this complication in these patients could be explained on one hand by an activation of the sympathetic nervous system hence the appointment of neurogenic pulmonary edema and on the other hand by the presence of a systemic inflammatory response syndrome (SIRS), but future studies will be needed to elucidate these pathophysiological mechanisms. According to recent studies, the treatment of ARDS is based on a mechanical ventilation strategy that uses low volumes with high PEEP, while prone position is a therapeutic alternative but with the risk of increased intracranial pressure. The management of aneurysmal arachnoid haemorrhage relies on the control of as well as other factors responsible for delayed ischemia and aneurysm treatment.

Keywords: Acute respiratory distress syndrome, subarachnoid hemorrhage, catecholaminergic stress, systemic inflammatory response syndrome, protective ventilation.

Copyright @ 2020: This is an open-access article distributed under the terms of the Creative Commons Attribution license which permits unrestricted use, distribution, and reproduction in any medium for non-commercial use (NonCommercial, or CC-BY-NC) provided the original author and source are credited.

INTRODUCTION

Aneurysmal arachnoid haemorrhage (AAH) is a rare disease common in the young female population. It can cause many neurological complications, namely hydrocephalus, vasospasm and rebleeding. However, it can also lead to extra neurological complications, including cardiovascular failure, renal failure, metabolic disorders (hypokalemia, hyperglycemia, dysnatremia) and acute respiratory distress syndrome (ARDS) [1]. We report a case of a 50-year-old patient who developed ARDS during her hospitalization resuscitation service for aneurysmal Arachnoid hemorrhage.

CLINICAL OBSERVATION

A 50 years old female patient, followed for type 2 diabetes for 3 years under metformin, admitted to the emergency department for intense headaches in thunderclap, vomiting and photophobia. The clinical examination at admission found a patient confused (GCS 14/15), subfebrile (temperature at 37.9° C), hemodynamically stable (BP=130/70 mmHg, Cardiac frequency= 90 beats / min) and respiratory (16 cycles / min, SpO2 at 98% in

ambient air), not exhibiting a sensorimotor deficit. The brain CT-scan performed revealed the presence of meningeal and intraventricular haemorrhage (Figure-1), the lumbar puncture brought a haemorrhagic liquid, incoagulable, microscopically characterized by the presence of 14,400 red blood cells / mm³, of 3 white elements / mm³ and without germs to direct examination, the initial chest x-ray was normal, the electrocardiogram showed no abnormalities, troponin was slightly elevated (7 times the normal value) and metabolic status showed hypokalemia at 3.05 mmol / l and hyponatremia at 130 mmol / l. The patient had been transferred to the intensive care unit, placed in a low-light unit, put under oxygen (3l / min), antiemetic to control vomiting, nimodipine (2 tablets every 6 hours by the nasogastric tube) to prevent vasospasm, paracetamol or morphine to calm headaches. The maintenance of the hemodynamic stability was essential with the aim of a Systolic blood pressure between 160 and 180mmHg. The evolution was marked by the respiratory and infectious aggravation of the patient with a polypnea at 24 cycles / min, an SpO2 at 86% under oxygen (telescope), bilateral pulmonary opacities at chest x-ray, leukocytosis at 15,680 elements / mm³ and a CRP at 28

0 mg / l. PaO₂ / FiO₂ ratio was 150 mmHg. Cardiac ultrasonography had eliminated cardiogenic hydrostatic edema. The diagnosis of moderate ARDS (Figure-2) and systemic inflammatory response syndrome (SIRS) was made. Protective ventilation was set up with low current volu

mes (6ml / kg) and high PEEPs combined with antibiotic therapy. The evolution was marked by the improvement of the patient after one week and its transfer to the neurosurgery department for additional support.

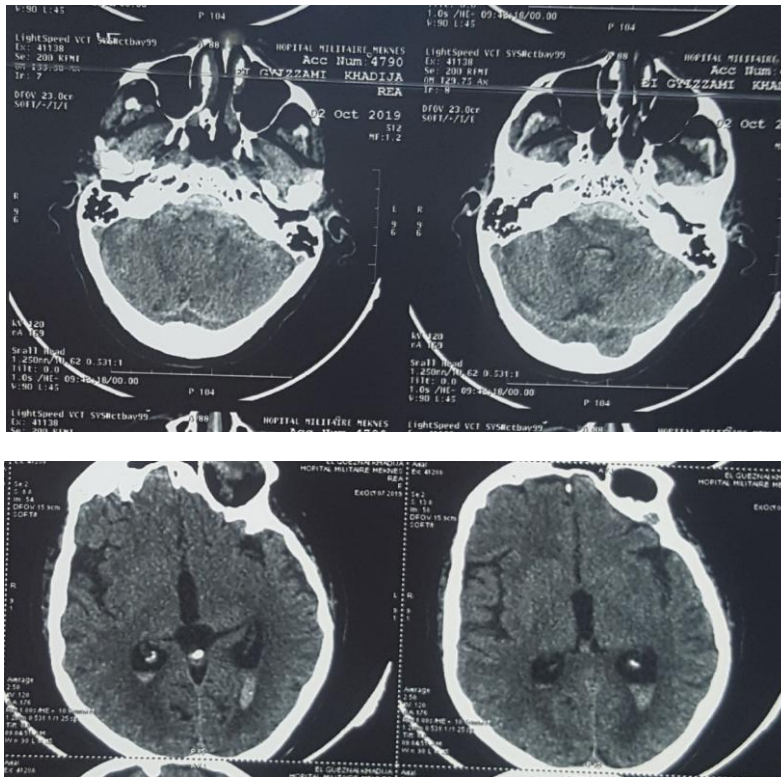


Fig-1: Brain scanner, subarachnoid and intraventricular hemorrhage

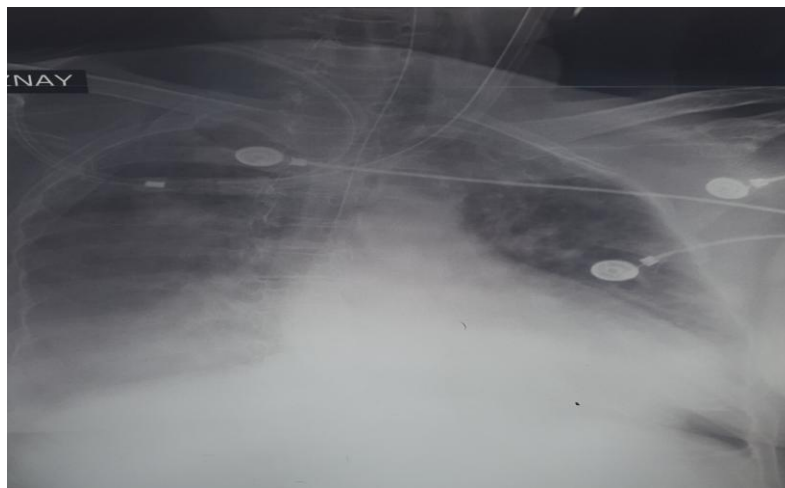


Fig-2: Pulmonary Radiography, bilateral pulmonary opacities

DISCUSSION

According to the new Berlin definition, ARDS is defined by the installation of respiratory symptoms for less than a week after the occurrence of a usual risk factor for ARDS if it is identified, the presence of bilateral pulmonary opacities radiography or chest CT scan, exclusion of left heart failure and hypoxemia with a PaO₂ / FiO₂ ratio of less than or equal to 300mmHg. There are 3 types of ARDS depending on the severity of this hy

poxemia, mild when the PaO₂ / FiO₂ ratio is between 200 and 300 mmHg, moderate when it is between 100 and 200 mmHg and severe if it is below 100 mmHg. This is valid if the patient is under invasive, noninvasive ventilation or VS-PEP [2]. It is responsible for significant morbidity and mortality in patients with aneurysmal arachnoid hemorrhages. In fact, the mortality is of the order of 50%, and 60% of the survivors will have neurological sequelae [3]. It occurs in severe forms of The AAH (W

FNS > 3 and / or modified Fisher score > 2) [4]. The occurrence of this complication in these patients could be explained on one hand by an activation of the sympathetic nervous system hence the appointment of neurogenic pulmonary edema and on the other hand by the presence of a systemic inflammatory response syndrome (5). The massive release of catecholamines secondary to aneurysmal rupture would lead to myocardial lesions objectified by the presence of electrical abnormalities in the electrocardiogram and by an increase in cardiac enzymes including troponin and CPK mb [6], this catecholaminergic discharge lasted on average seven at ten days with normalization at the 6th month [7]. The presence of SIRS in patients with AAH increases the risk of neurogenic pulmonary edema and is of poor prognosis if present at admission [8]; it is manifested by a fever at admission, hyperleukocytosis and elevation of CRP [9]. In the aftermath of aneurysmal rupture, there is a sharp increase in systemic and pulmonary vascular resistance that causes ventricular compliance impairment and then hydrostatic edema [10]. Intracranial hyperpressure outbreaks, in case of aneurysmal arachnoid haemorrhage, transiently cause the increase in intravascular pressure at the origin of alveolocapillary membrane damage explaining plasma leakage in pulmonary interstitial tissue [11]. Several recent studies suggested that a mechanical ventilation strategy using low volumes with high PEEPs could reduce mortality in these patients [12]; ventral decubitus is a therapeutic alternative but with a risk of increased intracranial pressure [13]. A study conducted by the National Heart Lung (NHL) had shown a 22% reduction in the risk of death in patients ventilated at 6ml / kg theoretical ideal weight compared to 12ml / kg [14], the management of the AAH relies on the control of Intracranial pressure as well as other factors responsible for delayed ischemia and treatment of the aneurysm.

CONCLUSION

The pathophysiological mechanisms that may explain the association of AAH with ARDS remain to be elucidated, and future studies are needed. The strategy of mechanical ventilation based on low current volumes and high PEP would nevertheless improve the prognosis, reduce mortality, and reduce the duration of mechanical ventilation.

REFERENCE

1. Heuschmann PU, Di Carlo A, Bejot Y, Rastenyte D, Ryglewicz D, Sarti C, Torrent M, Wolfe CD. European Registers of Stroke (EROS) Investigators. Incidence of stroke in Europe at the beginning of the 21st century. *Stroke*. 2009 May 1;40(5):1557-63.
2. Legros V. The Berlin definition of acute respiratory distress syndrome. Why is this important for medical practice? *Réanimation*, (2013; 22:1-2.
3. Zacharia BE, Hickman ZL, Grobelny BT, DeRosa P, Kotchetkov I, Ducruet AF, Connolly ES. Epidemiology of aneurysmal subarachnoid hemorrhage. *Neurosurgery Clinics*. 2010 Apr 1;21(2):221-33.
4. Solenski NJ, Haley EC, Kassell NF, Kongable G, Germanson T, Truskowski L, Torner JC. Medical complications of aneurysmal subarachnoid hemorrhage: a report of the multicenter, cooperative aneurysm study. *Critical care medicine*. 1995 Jun 1;23(6):1007-17.
5. Legros V, Bard M, Rouget D, Kleiber JC, Gelisse E, Lepouse C. Extra-Neurologic Complications of Subarachnoid Hemorrhage. *REANIMATION*. 2018 Sep 1;27(5):413-20.
6. Mayer SA, Lin J, Homma S, Solomon RA, Lennihan L, Sherman D, Fink ME, Beckford A, Klebanoff LM. Myocardial injury and left ventricular performance after subarachnoid hemorrhage. *Stroke*. 1999 Apr;30(4):780-6.
7. Fontes RB, Aguiar PH, Zanetti MV, Andrade F, Mandel M, Teixeira MJ. Acute neurogenic pulmonary edema: case reports and literature review. *Journal of neurosurgical anesthesiology*. 2003 Apr 1;15(2):144-50.
8. Yoshimoto Y, Tanaka Y, Hoya K. Acute systemic inflammatory response syndrome in subarachnoid hemorrhage. *Stroke*. 2001 Sep 1;32(9):1989-93.
9. Hocker SE, Tian L, Li G, Steckelberg JM, Mandrekar JN, Rabinstein AA. Indicators of central fever in the neurologic intensive care unit. *JAMA neurology*. 2013 Dec 1;70(12):1499-1504.
10. SARNOFF SJ, SARNOFF LC. Neurohemodynamics of pulmonary edema: II. The role of sympathetic pathways in the elevation of pulmonary and systemic vascular pressures following the intracisternal injection of fibrin. *Circulation*. 1952 Jul;6(1):51-62.
11. Theodore J, Robin ED. Speculations on neurogenic pulmonary edema (NPE). *Am Rev Respir Dis*, 1976;113:405-411.
12. Brower RG, Rubenfeld GD. Lung-protective ventilation strategies in acute lung injury. *Critical care medicine*. 2003 Apr 1;31(4):S312-6.
13. Ashton-Cleary DT. Prone ventilation for refractory hypoxaemia in a patient with severe chest wall disruption and traumatic brain injury. *BJA: British Journal of Anaesthesia*. 2011 Dec 23;107(eLetters Supplement), 1009–1010.
14. Acute Respiratory Distress Syndrome Network. Ventilation with lower tidal volumes as compared with traditional tidal volumes for acute lung injury and the acute respiratory distress syndrome. *New England Journal of Medicine*. 2000 May 4;342(18):1301-8.