

"Too Beautiful" Sylvian Artery

Jonathan Esperence Ongoka Ahouet^{1*}, Mohamed Boussif¹, Nabil Hammoune¹, Abdelilah Mouhsine¹

¹Radiology Department, Avicenne Military Hospital, Marrakech, Morocco

DOI: [10.36347/sjmcr.2022.v10i09.023](https://doi.org/10.36347/sjmcr.2022.v10i09.023)

| Received: 16.08.2022 | Accepted: 22.09.2022 | Published: 25.09.2022

*Corresponding author: Jonathan Esperence Ongoka Ahouet
 Radiology Department, Avicenne Military Hospital, Marrakech, Morocco

Abstract

Case Report

Despite the advent and increasing availability of magnetic resonance imaging, the imaging modality of choice in the acute care of stroke patients in many institutions remains CT. The hyperdense artery sign is the primary marker of acute ischaemic stroke. We report the case of a 70-year-old patient, in whom brain CT without contrast injection performed in emergency following a neurological deficit, allowed the objectification of an early ischemic stroke.

Keywords: Computed tomography, early ischaemic signs, Hyperdense artery, Stroke.

Copyright © 2022 The Author(s): This is an open-access article distributed under the terms of the Creative Commons Attribution 4.0 International License (CC BY-NC 4.0) which permits unrestricted use, distribution, and reproduction in any medium for non-commercial use provided the original author and source are credited.

INTRODUCTION

CT scan without contrast injection represents the key examination in the initial management of ischaemic stroke. Its role is to look for early signs of cerebral ischaemia [1]. Among these early signs, we have the intravascular signs consist of the visualization of an intra-arterial hyperdensity related to the direct visualization of the clot inside the artery. This spontaneous hyperdensity is defined as an increase in contrast within the artery, which should not only be denser than the surrounding tissue but also denser than

the contralateral artery. This abnormality is most commonly seen in the middle cerebral artery (MCA)

OBSERVATION

We report the case of a 70 year old patient who was admitted to the emergency department with a neurological deficit on awakening, associating aphasia, a right brachiofacial deficit and a deviation of the head and eyes to the left. The NIHSS (National Institute of Health StrokeScore) was 19.

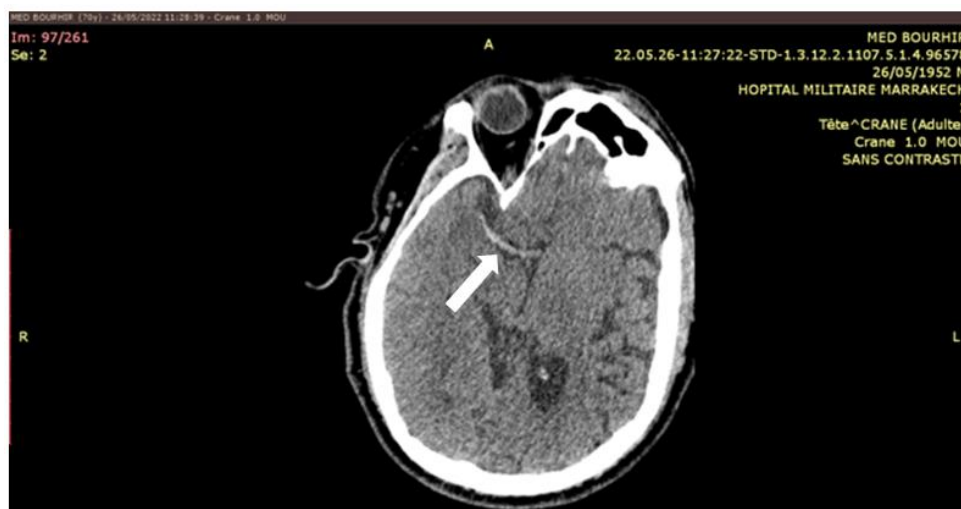


Fig 1: Spontaneous hyperdensity of the left middle cerebral artery (white arrow)

A CT scan without contrast injection (Fig 1) showed hyperdensity of the right middle cerebral artery (MCA), associated with effacement of the cortical sulci

in the territory of the right MCA, indicating a recent ischemic stroke in the right sylvian territory. The visualisation of a "too beautiful" sylvian artery or

Citation: Jonathan Esperence Ongoka Ahouet, Mohamed Boussif, Nabil Hammoune, Abdelilah Mouhsine. "Too Beautiful" Sylvian Artery. Sch J Med Case Rep, 2022 Sept 10(9): 959-960.

"dense" sylvian artery on the brain scan is an early sign of ischaemic stroke in the sylvian territory, indicating the presence of an intraluminal thrombus in the M1 branch of the ACM [2]. It corresponds to a spontaneous, unilateral hyperdensity (relative to other vessels of the same calibre), not caused by intravascular calcification. In the absence of any recanalisation treatment, its presence is associated with a poor prognosis because the infarcted territory will be extensive. In post-thrombolysis, the disappearance of spontaneous hyperdensity is indicative of recanalisation of the ACM, whereas its persistence is an early predictor of poor prognosis [3].

CONCLUSION

Early signs of cerebral ischaemia should be systematically sought on the initial CT scan of a patient being managed for a stroke [1]. They are early indicators of developing ischaemia. Because of their Sensitivity, specificity and predictive value, they represent predictive markers of the subsequent extension of the infarct. A better evaluation is thus

possible as soon as the patient is taken care of, allowing the adaptation of therapies.

REFERENCES

1. Moulin, T., Cattin, F., Crepin-Leblond, T., Tatu, L., Chavot, D., Piotin, M., ... & Bonneville, J. F. (1996). Early CT signs in acute middle cerebral artery infarction: predictive value for subsequent infarct locations and outcome. *Neurology*, *47*(2), 366-375.
2. Leys, D., Pruvo, J. P., Godefroy, O., Rondepierre, P. H., & Leclerc, X. (1992). Prevalence and significance of hyperdense middle cerebral artery in acute stroke. *Stroke*, *23*(3), 317-324.
3. Paliwal, P. R., Ahmad, A., Shen, L., Yeo, L. L., Loh, P. K., Ng, K. W., ... & Sharma, V. K. (2012). Persistence of hyperdense middle cerebral artery sign on follow-up CT scan after intravenous thrombolysis is associated with poor outcome. *Cerebrovascular Diseases*, *33*(5), 446-452.