

Case Report

Osteosarcoma or Ewing's sarcoma? Radiologist's Dilemma

Rahul kansal*, Puneet gupta, Manjit Arora, Priyanka Mattoo, Arti Khurana, Indu Bhasin

Department of Radio-diagnosis and Imaging, ASCOMS Hospital, Sidhra, Jammu (J&K), India

***Corresponding author**

Rahul kansal

Email: rahulkansal35@gmail.com

Abstract: Misdiagnosis of osteosarcoma is usual with the condition commonly known as Ewing's sarcoma. It is the second most frequent primary malignant bone cancer, after osteosarcoma. We report a case of 13 year old boy who radiologically presents all features of Ewing's sarcoma but histopathologically comes out to be osteosarcoma.

Keywords: Osteosarcoma, Ewing's sarcoma, Distal femur, Bone neoplasias.

INTRODUCTION

There was a broad spectrum of misdiagnoses between ewing's sarcoma and osteosarcoma. Symptoms that might aid diagnosis include early local volume increase and the presence of fever. Early symptom of osteosarcoma and Ewing's sarcoma is local pain. This case report is helpful in identifying signs, symptoms and imaging features of both osteosarcoma and Ewing's sarcoma that could be used in differentiating the two types of tumors, providing information and impetus for shorten the delay to diagnosis which ultimately results in improved prognosis.

CASE REPORT

A 13-year old boy with limping, staggering gait and pain and soft tissue swelling in the lower thigh region for 20 days i.e. distal femur, referred by an orthopaedician, presented in our department. X-ray (Fig. 1) and CT scan (Fig. 2) revealed diffuse circumferential cortical thickening and associated presence of saucerization of the cortical margin and interrupted type of periosteal reaction along the posterolateral aspect of distal femur as evidenced by sunburst/onion-peel type of reaction with associated Codman's triangle. MR imaging of the right thigh was performed and T1- T2- and IR images were obtained in the axial and coronal planes (Fig. 3a & 3b). MR study revealed altered signal intensity of the bone marrow of right femoral diaphysis exhibiting hypointense signal on T1W1 and hyperintense signal on T2W1/STIR images. Associated large soft tissue component was seen predominantly along the posterolateral aspect of femur exhibiting heterogeneously hyperintense signal on T2W1 and iso to hypointense signal on T1W1 images. Displacement of the adjoining myofascial planes was noted, while femoral epiphysis was unremarkable and major neurovascular structures were normal.

Radiologists described the case as sign of malignant bone tumor, probably Ewing's sarcoma. The case was forwarded for histopathological correlation. On histopathology examination, on cut-section grey-white tumour was seen in diaphysis of femur. It also extended into soft tissue. Histologic type was conventional osteosarcoma with percentage of necrosis being 20-30% having high grade. The patient was later referred to specialist cancer institute for further treatment. On post operative follow up child is doing well.

MR Imaging of right thigh with T1, T2, IR Images obtained in axial & coronal view shows altered signal intensity of the bone marrow of right femoral diaphysis exhibiting hypointense signal on T1W1 & hyperintense signal on T2W1/ STIR images with aggressive sunburst periosteal reaction, codman's triangle & large soft tissue component.

DISCUSSION

Ewing's sarcoma and Osteosarcoma are the most common primary malignant bone tumors in children [1]. For tumour diagnosis, focus should be on early signs and symptoms in order to distinguish it from other conditions, such as osteomyelitis and tendonitis, and to distinguish different bone tumours from one another [2]. Prognosis is improved by early diagnosis and treatment. The prognosis of Ewing's sarcoma and osteosarcoma is mainly depend on the local extent of the tumor and presence of metastases [3]. During the last 20 years, new knowledge and studies on bone sarcomas have been presented, and great advances in the treatment of these diseases have been achieved [4]. Limb salvage treatment allows tumor resection while preserving the limb, moreover, modern prostheses preserve limb function also. [5]. Primary osteosarcoma is classified according to site as central (conventional

high-grade and low-grade), intracortical or surface (parosteal, periosteal or high-grade). Osteosarcoma may sometimes be multicentric (osteosarcomatosis) or arise within the soft tissues (extraskelatal). Intramedullary component sometimes shows dense sclerosis. Extra osseous component occurs after destruction of cortex resulting in typical osseous ‘cloud-like’ matrix mineralization. The extraosseous mass appears dense and prominent due to periosteal reaction, which typically shows ‘sunburst’ appearance. Reactive Codman’s triangles may be seen at the margin of the lesion [6]. Although MRI contributes little help in the diagnosis of the variety of the tumour, it is useful for local staging of the tumour. Both intramedullary and extraosseous extension are clearly demonstrated, as is extension into the adjacent articular joint. Skip metastases, if any can be identified and therefore it is very essential to image the entire bone [7]. Ewing’s sarcoma accounts for approximately 5% of biopsied primary tumours and, along with osteosarcoma, represents 90% of primary malignant bone tumours in children [8]. 75% of patients are between 5 and 15 years of age [9]. Localized pain and swelling are the

most common chief complaints. Diaphysis (35%) or the metadiaphyseal region (59%) of a long bone are the most common sites.. Bones most commonly affected are the femur and humerus (together 31% of cases), the pelvic bones (21% of cases, most commonly the ilium) and ribs (6.5-8% of cases) [10]. A wide zone of transition with permeative lytic bone destruction is seen. The tumour rapidly extends through the cortex producing a large extraosseous, sub-periosteal mass. Soft tissue component is clearly appreciated on imaging. There is erosion of the outer cortex, producing so-called ‘saucerization’ of the cortex. Occasionally Codman’s triangle is also seen. A vertical ‘hair-on-end’ type of periosteal reaction is also classical of Ewing’s sarcoma. Other reported features include cortical thickening and rarely bone expansion or pathological fracture. Ewing’s sarcoma may occasionally show a mixed or mainly sclerotic lesion, especially in the flat bones and spine. These lesions may resemble osteosarcoma [11]. CT and MRI are helpful in demonstrating a large extraosseous component. Intraosseous component is accurately demonstrated and ‘skip’ metastases may be identified [12].

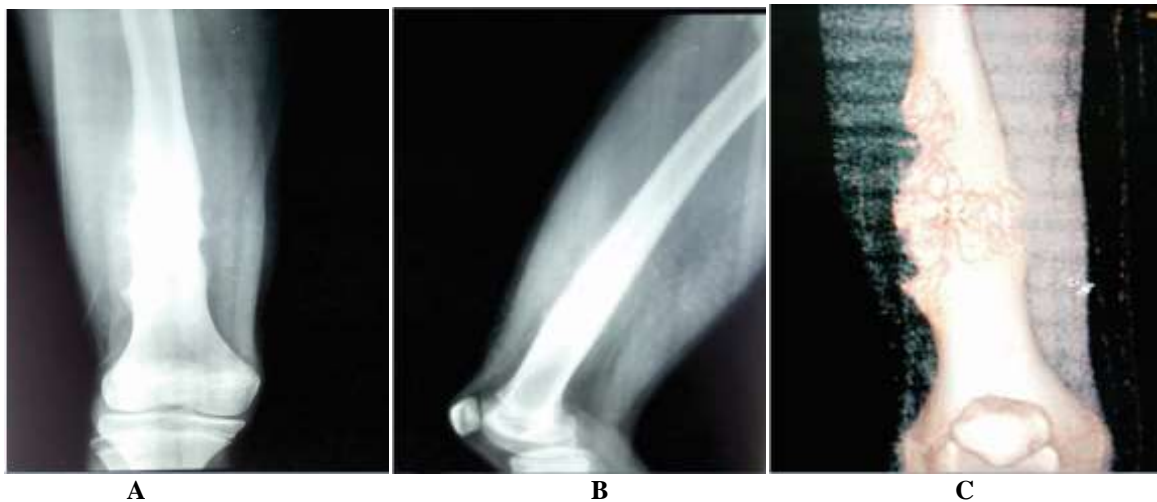

Fig. 1 : X-ray AP (A), Lateral view (B) and 3D (C) image of right thigh shows interrupted, sunburst periosteal reaction seen involving the distal femoral diaphysis with saucerization along the lateral femoral aspect, obliteration of medullary cavity and soft tissue swelling.

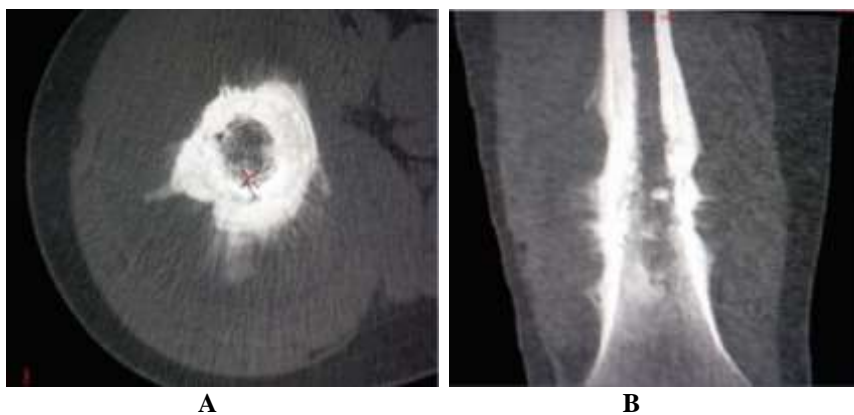


Fig. 2: CT A) Axial & B) Coronal image shows aggressive, interrupted, sunburst/onionpeel periosteal reaction & codman’s triangle involving the femoral diaphysis with associated diffuse circumferential cortical thickening & obliteration of medullary cavity with soft tissue extension.

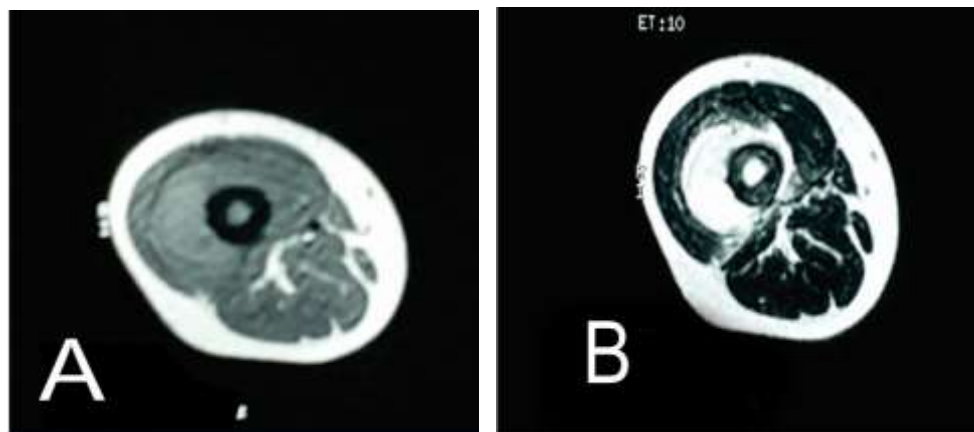


Fig. 3a: Axial A) T1W1 & B) T2W1 images

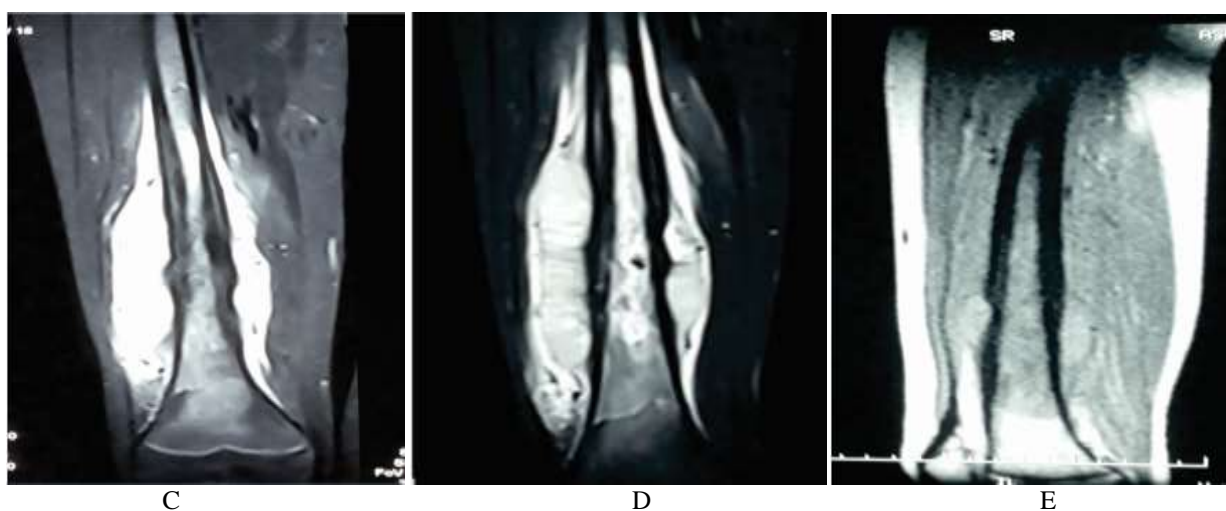


Fig. 3b : Coronal C) T1W1 D) T2W1 E) STIR images

CONCLUSION

Lower femoral diaphyseal permeative destructive, lytic bone lesion with extraosseous extension into the surrounding soft tissue in young child could be Ewing's or osteosarcoma. As the age of patient, presenting signs and symptoms and radiological (x ray, CT and MRI) features are common in both the tumors and could be proved only on histopathological diagnosis. Therefore it could be diagnostic dilemma for the radiologist and osteosarcoma should always be put in the differential diagnosis of Ewing's sarcoma.

REFERENCES

1. Yaw KM; Pediatric bone tumors. *Semin Surg Oncol.*, 1999; 16(2): 173-183.
2. Widhe B, Widhe T; Initial symptoms and clinical features in osteosarcoma and Ewing sarcoma. *J Bone Joint Surg Am.*, 2000; 82(5): 667-674.
3. Ferrari S, Bertoni F, Mercuri M, Sottili S, Versari M, Bacci G; Ewing's sarcoma of bone: relation between clinical characteristics and staging. *Oncol Rep.*, 2001; 8(3): 553-556.
4. Vlasak R, Sim FH; Ewing's sarcoma. *Orthop Clin North Am.*, 1996; 27(3): 591-603.
5. Sluga M, Windhager R, Lang S, Heinzl H, Krepler P, Dikus M *et al.*; The role of surgery and resection margins in the treatment of Ewing's sarcoma. *Clin Orthop.*, 2001; 392: 394-399.
6. White LM, Kandel R; Osteoid-producing tumours of bone. *Semin Musculoskelet Radiol.*, 2000; 4(1): 25-43.
7. Saifuddin A; The accuracy of imaging in the local staging of appendicular osteosarcoma. *Skeletal Radiol.*, 2002; 31(4): 191-201.
8. Zelazny A, Reinus WR, Wilson AJ; Quantitative analysis of the plain radiographic appearance of Ewing's sarcoma of bone. *Invest Radiol.*, 1997; 32(1): 59-65.
9. Kransdorf M, Smith SE; Lesions of unknown histogenesis: Langerhans cell histiocytosis and Ewing sarcoma. *Semin Musculoskelet Radiol.*, 2000; 4(1):1123-1126.
10. Shapeero LG, Vanel D, Sundaram M, Ackerman LV, Wuisman P, Bauer TW *et al.*; Periosteal

- Ewing sarcoma. *Radiology*, 1994; 191(3): 825-831.
11. Saifuddin A, Whelan J, Pringle JA, Cannon SR; Malignant round cell tumours of bone: atypical clinical and imaging features. *Skeletal Radiol.*, 2000; 29(11): 646-651.
 12. Stoker DJ, Saifuddin A; Bone tumours: malignant lesions. *Adam: Grainger and Allison's Diagnostic Radiology*. 5th edition, Chapter 48, Churchill Livingstone, 2008.