

## **Research Article**

### **Benign Lacrimal Gland Tumors: A Histopathologic Study**

**Kavitha Toopalli<sup>1\*</sup>, Sailaja Vallury<sup>2</sup> Modini Pandharpurkar<sup>3</sup>**

<sup>1</sup> Assistant Professor of Pathology, Sarojini Devi Eye Hospital, Hyderabad, India

<sup>2</sup> Associate Professor of Pathology, MNR Medical College, Sanga Reddy, Hyderabad, India

<sup>3</sup> Associate Professor of Ophthalmology, Government Medical College, Nizamabad, Hyderabad, India

#### **\*Corresponding author**

Kavitha Toopalli

**Email:** [toopalli@gmail.com](mailto:toopalli@gmail.com)

---

**Abstract:** Lacrimal gland tumors are rare. The most common benign epithelial tumor of the lacrimal gland is pleomorphic adenoma or benign mixed tumor. We did a retrospective study of benign epithelial tumors of lacrimal gland to analyze the histological pattern and correlate with the clinical findings. Out of a total 31 specimens of lacrimal gland tumors received at the Department of Pathology, Sarojini Devi Eye Hospital, Hyderabad, over a period of five years, 20 cases of histologically proven benign epithelial tumors were included in the study. A detailed analysis of the cases was done, taking into consideration the clinical details such as age, sex and size of the tumor. The histological patterns were studied on hematoxylin and eosin stained sections. The age range in our study was between the second to seventh decades. Females were more commonly affected. Benign tumors constituted 74.07% of the epithelial tumors and all of them were pleomorphic adenomas. Microscopically, all the cases showed proliferation of epithelial and stromal elements. Extensive squamous metaplasia was seen in two cases and chondroid differentiation in two cases. A definite pre-operative diagnosis is essential for the proper management of pleomorphic adenoma. Clinical and radiological features suggest the diagnosis in most cases. Complete excision of the tumor along with the capsule prevents recurrence. Needle and incisional biopsies are largely contraindicated with few exceptions. Pathologists should be aware of the histologic diversity of pleomorphic adenoma to prevent misdiagnosis.

**Keywords:** Lacrimal gland tumors, rare, epithelial, benign mixed tumor, complete excision, recurrence, histologic diversity.

---

#### **INTRODUCTION**

Lacrimal gland is a bilobed eccrine secretory gland in the shape of an almond located in the supero lateral extra conal fat in the lacrimal fossa [1]. The two lobes are, the larger orbital lobe and the much smaller palpebral lobe. The lacrimal gland is a non-encapsulated structure composed histologically of ducts and acini [2]. It is composed exclusively of serous cells entirely lacking mucinous cells [3]. Lacrimal gland tumors comprise about 5 to 25% of all orbital tumors [4]. Lacrimal gland may be considered as a minor salivary gland and the tumors of the lacrimal gland are classified like salivary gland tumors [5]. The most common tumor is the benign pleomorphic adenoma that comprises around 50% of epithelial tumors [6]. The most common age of onset of pleomorphic adenoma of lacrimal gland is in the fifth and sixth decades with a mean age of onset at 48 years [7]. It presents as a painless and slowly growing mass and also as exophthalmos [8]. Clinical, radiological, and ultrasonographic characteristics suggest the diagnosis of pleomorphic adenoma [9]. Lacrimal gland pleomorphic adenomas (LGPAs) should be excised completely with

a margin of normal tissue as incomplete resection may lead to recurrence even decades later. In select cases, a preoperative biopsy will help the clinician choose the correct management strategy [10].

#### **MATERIALS AND METHODS**

Out of total 31 cases of Lacrimal gland tumors diagnosed at Sarojini Devi Eye Hospital, Hyderabad, over a period of 5 years from 2010 to 2014, the study group consisted of 20 cases of benign epithelial tumors. A detailed analysis of the cases was done, taking into consideration the clinical details such as age, sex and size of the tumor. Complete ophthalmic examination was done in all the cases including investigations such as orbital B mode USG, plain X ray, MRI and CT scan. The gross appearance and histological features of the resected specimen were studied. Routine histological examination was done using hematoxylin and eosin stain on multiple sections from various sites of the tumor. The arrangement of cells, cell type, size and shape of the cells and nuclear characteristics were taken into consideration. Presence of metaplastic tissues and evidence of malignancy were specifically searched for.

**RESULTS**

Of In the present study, there were 20 benign epithelial tumors diagnosed over a period of five years. The age range of the patients was between the second and the seventh decades. The age of the youngest patient was 19 years and the oldest patient was 69 years. Though benign tumors had a wide age range of occurrence, the maximum number of cases occurred in the fourth decade (Table 1). Females were more commonly affected. There were fifteen female patients and five male patients (Table 2). Pleomorphic adenoma

which comprised 74.07% of the total epithelial tumors was the only histological type of benign tumor in our study. Microscopically, pleomorphic adenoma or benign mixed tumor showed both epithelial and mesenchyme like tissues (Fig. 1 &2). The epithelial component formed ducts lined by epithelial and myoepithelial cells. The stroma showed myxoid and hyaline change. Squamous metaplasia was seen in four cases which was extensive in two cases (Fig. 3). Prominent cartilaginous differentiation was seen in two cases of pleomorphic adenoma (Fig. 4).

**Table 1: Showing the age distribution**

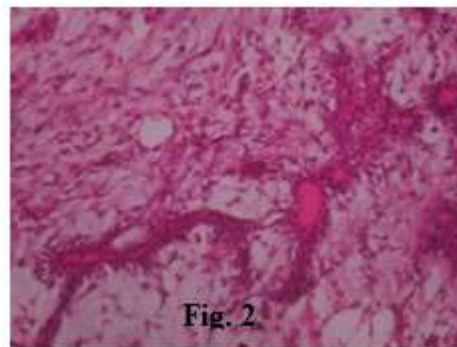
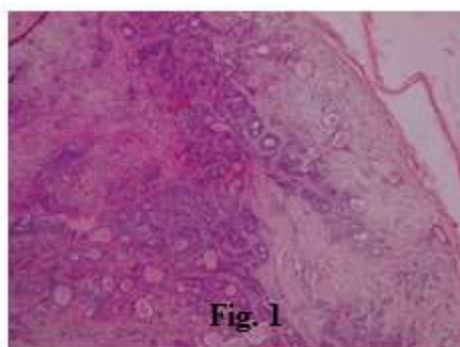
Pleomorphic adenoma (Age in years)	No. of cases
10 - 19	1
20 - 29	3
30 - 39	8
40 - 49	4
50 - 59	2
60 - 69	1
70 - 79	1
Total cases	20

**Table 2: Showing the sex distribution of pleomorphic adenoma**

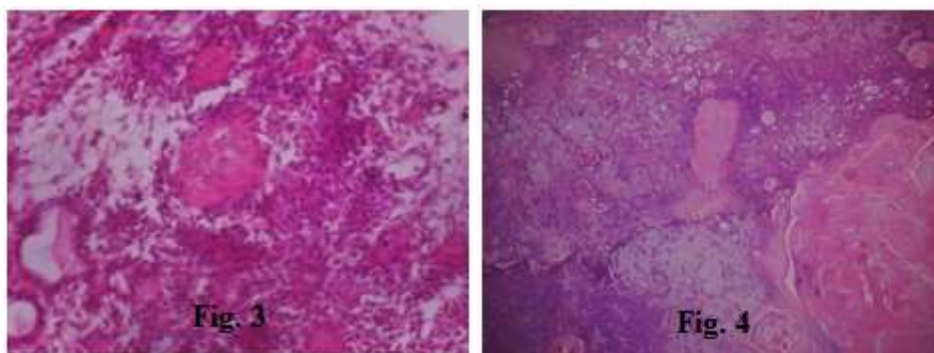
Pleomorphic adenomas	No. of cases
Females	15
Males	05
Total	20

Image analysis showed pleomorphic adenomas as circumscribed round to oval masses. Grossly, pleomorphic adenomas typically had a pseudo capsule and ranged in size from 1.5 to 4.0 cm with a mean diameter of 2.5 cm. Cut section showed glistening gray white and gritty areas in some cases. Microscopically, pleomorphic adenoma or benign mixed tumor showed both epithelial and mesenchyme like tissues (Fig. 1 &2). The epithelial component formed ducts lined by

epithelial and myoepithelial cells. The stroma showed myxoid and hyaline change. Squamous metaplasia was seen in four cases which was extensive in two cases (Fig.3 & 4). Prominent cartilaginous differentiation was seen in two cases of pleomorphic adenoma. One case of pleomorphic adenoma was a recurrent tumor which had recurred 20 years after initial diagnosis. However no malignant elements were detected in the recurrent tumor.



**Fig.1 &2: Histopathology of pleomorphic adenoma showing ducts lined by double layered epithelium & myxoid stroma**



**Fig. 3& 4: Sections showing areas of squamous metaplasia**

**DISCUSSION**

Tumors of the lacrimal gland occur in <1/1,00,000 population per year [6]. Lacrimal gland tumors comprise about 5 to 25% of the orbital masses [4]. They are divided into epithelial and non-epithelial tumors. Epithelial tumors of the lacrimal gland are more common compared to the non-epithelial tumors [1, 2]. In our study also, epithelial tumors were more common constituting 87% of the total. Among the epithelial tumors, benign tumors were more common than malignant tumors. All the 20 cases of benign tumors in our study were pleomorphic adenomas or benign mixed tumors. Pleomorphic adenoma remains the most common benign epithelial tumor of the lacrimal gland.(12). There were sixteen female patients and four male patients, ages ranging from second to seventh decades. The mean age of occurrence for benign epithelial tumors in our study was 40 years which correlated with the study of Sarah *et al.* The female to male ratio of our study group was 3:1 compared to the study of Kohli *et al* in which it was 2:1. All the benign

tumors in our study presented as slowly progressive painless masses of about two to three years duration. Similar mode of presentation was seen in other studies also [6, 8]. Preoperative diagnosis was done based on the clinical and radiological features. The mass was excised entirely with the capsule. No preoperative FNAC or biopsy was done. Incisional biopsy is believed to increase the risk of recurrence due to disruption of the pseudocapsule and tumour spillage according to many older studies. Hence, we followed the traditional recommendation contraindicating incisional or needle biopsy [11]. However according to more recent studies, in selected cases, when a strong presumptive diagnosis is not possible preoperatively or to prevent exposing the patient to the morbidity of a lateral orbitotomy and unnecessary removal of the orbital lobe, a preoperative biopsy will help the clinician choose the correct management strategy [10]. Histologically, 74.07% were benign epithelial tumors and 26% were malignant epithelial tumors in our study, which correlated with the study of Kohli *et al.* [2].

**Table 3: Shows comparative studies of epithelial tumors of lacrimal gland with our study**

Epithelial tumors	Wright <i>et al.</i> [11]	Kohli <i>et al.</i>	Our Study
Benign tumors	61%	71.1%	74.07%
Malignant	38%	28.4%	25.93%

Microscopically, prominent areas of chondroid differentiation was seen in two cases. Four cases of Pleomorphic adenoma showed squamous metaplasia, which may sometimes be confused with squamous cell carcinoma [2]. One case in our study was a recurrent tumor, which recurred 20 years after initial resection. However the patient did not give any history of FNAC or incisional biopsy prior to the initial resection. So it is difficult to ascertain the cause of recurrence though there is a possibility of incomplete removal during the initial surgery. There were no malignant elements in the recurrent tumor. The numbers of recurrent cases in our study are insufficient to comment regarding malignant transformation in recurrent cases. However review of literature regarding recurrence and malignant transformation showed that while it is generally accepted that there is a progression from benign to malignant change in pleomorphic adenoma, there is no

evidence that recurrent tumours have a greater malignant potential [10].

**CONCLUSION**

Lacrimal gland tumors are rare. They can be divided into epithelial and non-epithelial tumors. Epithelial tumors are commoner than non-epithelial. Among the epithelial, benign tumors are commoner than malignant. Pleomorphic adenoma or benign mixed tumor is the most common benign tumor. The incidence is more common in females more commonly with a mean age of occurrence in the fourth decade. No cases were detected in children below the age of 15 years. Diagnosis is based on clinical and radiological features in most cases. A definite pre-operative diagnosis is essential for the proper management of the cases. Needle and incisional biopsies, strictly contraindicated in the past, are now recommended in selected cases. Complete resection of the tumor along with the capsule

prevents recurrence. All recurrent tumors may not show malignant transformation. The varied histologic presentation of pleomorphic adenomas should be kept in mind by pathologists to prevent misdiagnosis.

#### REFERENCES

1. Mafee MF, Edward DP, Koeller KK, Dorodi S; Lacrimal gland tumors and simulating lesions. *Radiologic Clinics of North America*, 1999; 37(1): 219-239.
2. Kohli M, Shah A, Bhatt S, Aggarwal S; Lacrimal gland tumors: A retrospective histopathological study. *Gujarat Medical Journal*, 2011; 66(1): 39-41.
3. Yanoff M, Fine BS; *Ocular Pathology*. 5<sup>th</sup> edition, Chapter 14, Mosby, St. Louis, 2002: 547.
4. Weis E, Rootman J, Joly TJ, Berean KW, Al-Katan HM, Pasternak S *et al.*; Epithelial lacrimal gland tumors pathologic classification and understanding. *Archives of Ophthalmology*, 2009; 127 (8): 1016-1028.
5. Kumar V, Abbas AK, Aster JC; *Robbins and Cotran Pathologic basis of Disease*. 9<sup>th</sup> edition, Chapter 28, Saunders, Philadelphia, 2014: 1321.
6. von Holstein SL, Coupland SE, Briscoe D, Le Tourneau C, Heegaard S; Epithelial tumors of the lacrimal gland: a clinical, histopathological, surgical and oncological survey. *Acta Ophthalmologica*, 2013; 91(3): 195-206.
7. Gupta A, Bansal S, Kumar S; Pleomorphic adenoma of the lacrimal gland mimicking a fungal granuloma. *The Internet Journal of Ophthalmology and Visual Science*. 2004; 3(2). Available from <https://ispub.com/IJOVS/3/2/8730>
8. Binatli O, Yaman O, Ozdemir N, Erdogan IG; Pleomorphic adenoma of lacrimal gland. *J Surg Case Rep.*, 2013. Available from <http://jscr.oxfordjournals.org/content/2013/10/rjt089>
9. Stefko ST, Di Bernardo C, Green WR, Merbs SL; Pleomorphic adenoma of lacrimal gland with extensive calcification. *Archives of Ophthalmology*, 2004; 122(5): 778-780.
10. Lai T, Prabhakaran VC, Malhotra R, Selva D; Pleomorphic adenoma of lacrimal gland : Is there a role for biopsy? *Eye*, 2009; 23: 2-6
11. Wright JE, Rose GE, Garner A; Primary malignant neoplasms of the lacrimal gland. *British Journal of Ophthalmology*, 1992; 76: 401-407.
12. Alkatan HM, Al-Harkan DH, Al-Mutlaq M, Maktabi A, Elkhamary SM; Epithelial lacrimal gland tumors: A comprehensive clinicopathologic review of 26 lesions with radiologic correlation. *Saudi J Ophthalmol.*, 2014; 28(1): 49-57.