

Cervical Lymphangioma of the Cystic Hygroma Type in an Adult Patient: Case Report of a Rare Condition

Paul Alejandro Aldaz Apolo^{1*}, Jorge Jarrin Menéndez², Erika Martínez Oviedo¹, Yessenia Aguilar Duran¹, Santiago Barragán Pozo¹, Julián Acosta Bermeo¹, Kory Reinoso Trujillo³, Katty Córdoba Cabrera³

¹Resident, Vascular Surgery Service, Military Hospital N°1, Gran Colombia y Queseras del medio, Quito 170112, Ecuador

²Vascular Surgery Specialist, Military Hospital N°1, Gran Colombia y Queseras del medio, Quito 170112, Ecuador

³Resident, General Surgery Service, Military Hospital N°1, Gran Colombia y Queseras del medio, Quito 170112, Ecuador

DOI: [10.36347/sasjs.2022.v08i10.002](https://doi.org/10.36347/sasjs.2022.v08i10.002)

| Received: 25.08.2022 | Accepted: 06.10.2022 | Published: 10.10.2022

*Corresponding author: Paul Alejandro Aldaz Apolo

Resident, Vascular Surgery Service, Military Hospital N°1, Gran Colombia y Queseras del medio, Quito 170112, Ecuador

Abstract

Case Report

Introduction: Cervical lymphangiomas are lymphatic malformations that occur rarely in adult patients, they are usually masses that have their diagnosis and resolution at early ages, their origin is produced by embryological defects during development, they are frequently located in the cervical region particularly in the posterior triangle. Computed tomography scan is the study of choice due to its great contribution to determine extension and relationship with neighboring structures. As for treatment, the indication is complete resection of the mass. The definitive diagnosis will be based on the histopathological study of the sample. **Clinical case:** We introduce the case of a 78-year-old patient, who comes to consultation due to a cervical mass of 1 year of evolution and progressive growth. A right cervical mass is evidenced on physical examination; complementary tests are performed. Therefore, a complete resection of the mass is decided, procedure that is carried out without complications. In the histopathology study, a mass compatible with lymphangioma of the cystic hygroma type was reported. **Conclusions:** Cervical lymphangiomas are masses frequently found in children and exceptionally rare in adult patients, however, they should be included in the differential diagnosis of cervical masses. The treatment of choice is complete resection of the mass to avoid recurrence. In our case, complete resection of the cervical mass was achieved, without any complication and in subsequent controls no signs suggesting recurrence were observed.

Keywords: Lymphangioma, Cystic hygroma, Cervical mass.

Copyright © 2022 The Author(s): This is an open-access article distributed under the terms of the Creative Commons Attribution 4.0 International License (CC BY-NC 4.0) which permits unrestricted use, distribution, and reproduction in any medium for non-commercial use provided the original author and source are credited.

INTRODUCTION

Lymphangiomas are congenital vascular malformations that usually occur in children, 80% before the age of 2 [1], being extremely rare their appearance in adult patients [2]. Its etiology in children is related to developmental anomalies while in adults it is not clear. There is no relation with gender and its location is variable, they may be located in the neck, axilla, groin, mediastinum even retroperitoneal space and pelvis. It is reported that 75% are found in the cervical region, specifically the posterior triangle [3]. The great majority are asymptomatic, in isolated cases, especially in large lymphangiomas that compress neighboring structures of the cervical region, symptoms such as airway obstruction, dysphagia and hoarseness may occur [4]. Different tests such as FNA, ultrasound and computed tomography scan may be used as diagnostic aids, however, the definitive diagnosis is

made by histological study of the sample. The treatment of choice is complete surgical resection to avoid recurrences [5], always previously performing imaging studies that allow evaluating its extension and relation with neighboring structures to avoid future complications. Other treatment alternatives include electrocoagulation, laser therapy, sclerotherapy and radiotherapy [1].

CLINICAL CASE

A 78-year-old female patient with a history of osteoporosis, hypothyroidism and depression. She went to consultation on vascular surgery due to a 1-year-old lump in the right cervical region, with progressive growth.

Physical examination revealed the presence of an oval mass of approximately 12 cm in the right

cervical region, of soft consistency, mobile, elastic,

non-painful, non-throbbing.

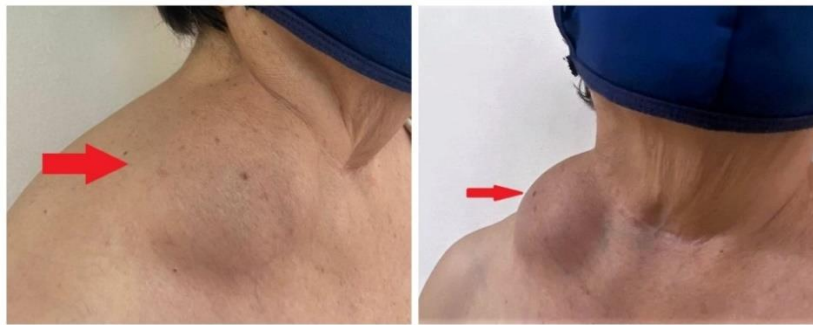

Figure 1: 12 cm right cervical lymphangioma

Extension tests are performed. Ultrasound of the neck which reports a right supraclavicular cystic lesion of possible lymphatic origin, in addition to taking a fluid sample with results of cytochemical (Yellow liquid, cloudy appearance, Cell count: 2298%, Polymorphonuclear leukocytes: 98.10% Glucose: 102.1, Proteins: 5.51 LDH: 134) and histopathological (blood smear on a serous background with abundant

mature lymphocytes of variable sizes, some show reactivity, few degenerated macrophages and occasionally plasma cells, presence of fibrin) analyses.

Simple contrast-enhanced neck CT scan shows images suggestive of a right cystic lymphangioma with displacement of the jugular vein towards the midline, no infiltration of vascular structures is observed.

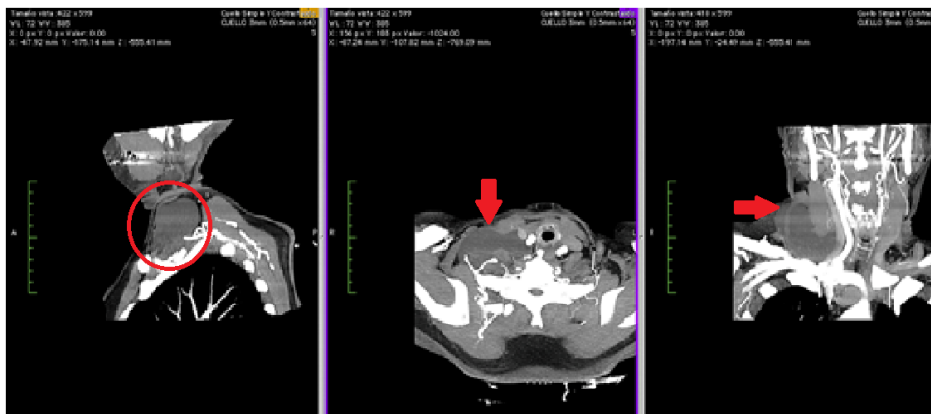


Figure 2: Tomography suggesting right cervical lymphangioma

Therefore, surgery such as excision of right cystic lymphangioma was decided, without complications, surgical sample was sent for biopsy in which histological sections show dilated lymphatic vessels (cystic) with flat endothelium, in its lumen

erythrocytes and proteinaceous material were occasionally identified, accompanied by chronic lymphocytic inflammation, compatible with lymphangioma of cystic hygroma type.

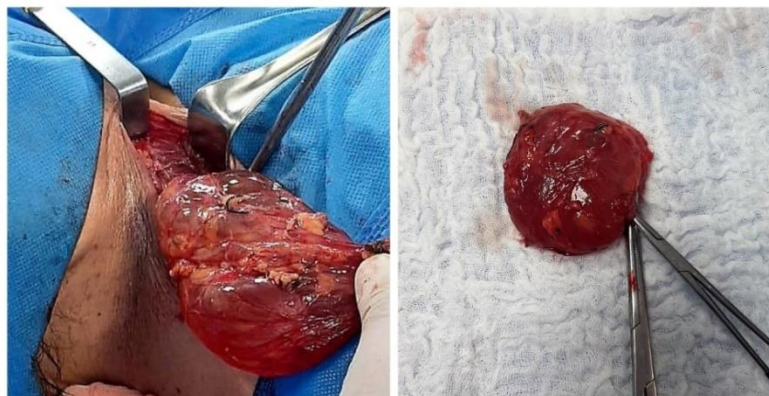


Figure 3: Surgical sample of 6x7 cm, vascularized with multi-cavity surface

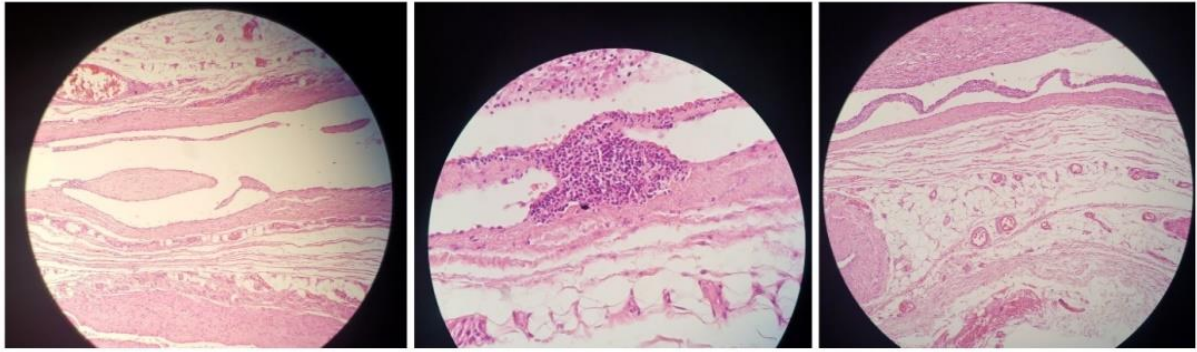


Figure 4: Histologic sections showing dilated lymphatic vessels lined with flat endothelium, abundant lymphocytic inflammation and presence of lymphoid aggregates, characteristic of cystic hygroma

Periodic outpatient follow-ups were performed for one year, in which no signs suggesting recurrence of the lymphangioma were observed.

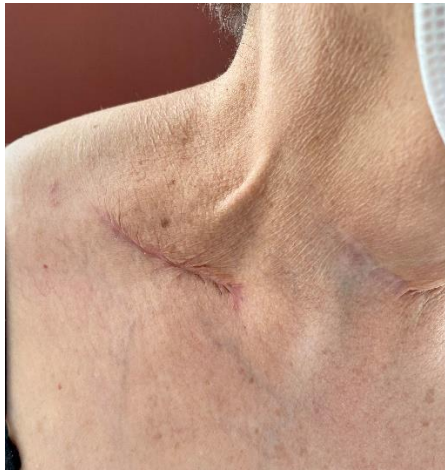

Figure 5: Patient follow-up after one year

DISCUSSION

Cervical lymphangioma in adults are rare congenital malformations of the lymphatic system that give rise to benign cystic tumors [4]. Their onset usually occurs before the age of 2, thus representing 5% of pediatric benign congenital masses [2]. They have an incidence of 1.2 to 2.8 per 100,000 newborns [4]. Their location is more frequent in the cervical region, specifically in the posterior triangle (75%), axilla (20%), mediastinum (5%), groin and retroperitoneal space and pelvis [3].

There are 4 types of classification: Cavernous lymphangioma, cystic hygroma, circumscribed lymphangioma and acquired progressive lymphangioma or benign lymphoendothelioma [1].

In adult patients, due to the rarity of their occurrence, they should be associated with differential diagnoses such as branchial cleft cysts, dermoid cysts and lymph node neoplasms [1, 3].

Embryologically, there are several theories that try to clarify its origin, the deficient union of the

primary lymphatic spaces with the central lymphatic system is apparently the most accepted hypothesis. Another probability describes a defective origin of the venous system, and it is also considered that certain viral infections or trauma events may be its etiology [1, 4].

In adults, some authors suggest that its origin is caused by late proliferation of cell remains [1].

As in our case, most lymphangiomas are asymptomatic, and when there are symptoms, they depend on their location [1, 3], the most frequent symptoms when there is compression of neighboring organs, dysphagia when it compresses the esophagus and obstruction of the respiratory tract when it is related to the trachea, in some occasions it may cause mild pain [4, 5].

The histology of the sample surgical will indicate the definitive diagnosis [6], however, several studies can be performed to determine the origin and extension and to have a correct surgical planning. Ultrasound is of great help to examine first-hand the type of mass [2], FNA has a high sensitivity for the diagnosis of benign cervical masses with an accuracy of up to 95%, however, its use is discussed because of the risk of complications such as bleeding, infections and recurrence [3, 6]. Simple and contrast-enhanced CT scan is the study of choice in this pathology, due to its level of precision regarding location, extension, mediastinal involvement, relation with neighboring structures and also allows us to plan an adequate surgical approach [2, 4, 6].

Histologically, lymphangiomas are characterized by dilated and ecstatic lymphatic spaces lined with attenuated endothelium, presence of lumens with lymphatic fluid, spaces containing lymphoid aggregates [1, 7].

The main treatment is complete surgical resection [1, 3, 4], safeguarding the neighboring anatomical structures, however, the recurrence rate reaches 15% [3], while with partial excision it reaches

up to 88% [1]. Treatment alternatives such as CO2 laser, electrocoagulation, sclerotherapy and cryotherapy are also reported, their use is determined by the location and invasion of neighboring structures [3].

The most frequently reported complications in surgery are the presence of hemorrhage, hematoma, seroma and, with greater severity, injury to nerves in the region [4].

CONCLUSIONS

Cervical lymphangiomas are masses that are frequent in children and exceptionally rare in adult patients, however, it should be included in the differential diagnosis. Diagnosis is based mainly on clinical history, ultrasound and CT scan, which will be essential in identifying the anatomical features of the mass for surgical preparation and thus avoid complications. The treatment of choice is complete resection of the mass to avoid recurrence.

In our case, we successfully achieved complete resection of the mass without any complications and in subsequent controls no signs suggesting recurrence were observed.

Conflict of Interest

We, the authors, declare that we have no personal, financial, intellectual, economic, and corporate conflicts of interest.

Financing: Self-funded

Acknowledgments

We thank the Angiology, Vascular and Endovascular Surgery Service of the Military Hospital No. 1 Quito, for allowing us access to the information to carry out this case report, as well as the Pathology Service.

REFERENCES

1. Kaira, V., Kaira, P., & Agarawal, T. (2021). Cervical Cystic Lymphangiomas in Adults: A Case

Series of a Rare Entity with Literature Review. *Head and Neck Pathology*, 15(2), 503-508.

2. Costache, A., Dumitru, M., Tweedie, D., Sarafoleanu, C., & Anghel, I. (2015). Adult cervical lymphangioma –ultrasonography, surgical removal, and pathology results. Case report. *Medical Ultrasonography*, 17(3), 411-413. Available from: <http://medultrason.ro/medultrason/index.php/medultrason/article/view/685>
3. Tzortzis, A. S., Maniatakos, V. P., Tsintzos, S., & Tzortzis, G. (2022). Cervical Cystic Lymphangioma in an Adult Patient. A Case Report of a Rare Entity. *ACTA MEDICA*, 64(4), 224-226. Available from: <http://www.ncbi.nlm.nih.gov/pubmed/35285445>
4. Basurto-Kuba, E. O. P., Hurtado-Lopez, L. M., Campos-Castillo, C., Garcia-Figueroa, R. B., Figueroa-Tentori, D., & Pulido-Cejudo, A. (2016). Cervical lymphangioma in the adult. A report of 2 cases. *Cirugía y Cirujanos (English Edition)*, 84(4), 313-317. Available from: <http://www.ncbi.nlm.nih.gov/pubmed/26259743>
5. Evman, M. D., & Aydin, S. (2019). A giant cervical lymphangioma. *Journal of Craniofacial Surgery*, 30(3), e275-e276. Available from: <http://journals.lww.com/00001665-201905000-00121>
6. MJ, V. M., Santero, M. P., Arribas, M. D., Córdoba, E., & Martinez, F. (2009). Cervical cystic lymphangioma in adults. *Cirugia Espanola*, 87(2), 122-123. Available from: <http://www.ncbi.nlm.nih.gov/pubmed/19540467>
7. Damaskos, C., Garpmpis, N., Manousi, M., Garpmpis, A., Margonis, G. A., Spartalis, E., ... & Antoniou, E. A. (2017). Cystic hygroma of the neck: single center experience and literature review. *Eur Rev Med Pharmacol Sci*, 21(21), 4918-4923. Available from: <http://www.ncbi.nlm.nih.gov/pubmed/29164568>