

## Cotyledonoid dissecting leiomyoma of the uterus: a case report

MD. Recep BEDİR<sup>1</sup>, MD. Rukiye YILMAZ<sup>2</sup>, MD. Afşin Rahman MÜRTEZAOĞLU<sup>2</sup>, MD. İbrahim ŞEHİTOĞLU<sup>1</sup>, MD. Hasan GÜÇER<sup>1</sup>, MD. Cüneyt YURDAKUL<sup>2</sup>

<sup>1</sup>Assistant Profesor, Recep Tayyip Erdogan University of Medical Faculty, Department of Pathology , Rize /TURKEY

<sup>2</sup>Recep Tayyip Erdogan University of Medical Faculty, Department of Pathology , Rize /TURKEY

### \*Corresponding Author:

Name: MD. Recep BEDİR

Email: [bedirrecep@gmail.com](mailto:bedirrecep@gmail.com)

**Abstract:** Cotyledonoid dissecting leiomyoma known as “Sternberg tumor of the uterus” is rare variant of benign uterine leiomyoma. We report a case of cotyledonoid dissecting leiomyoma in a 46-year-old woman who presented with menorrhagia and abdominal pain. A transvaginal ultrasound scan showed a 12cm sized, irregular contoured mass in the left lateral aspect of the uterus. A total abdominal hysterectomy with bilateral salpingoophorectomy was performed with complete lateral mass in the subserosal region. Microscopic examination showed variable sized micronodules of benign smooth muscle fascicles, which were separated by fibrous connective tissue with a marked hydropic change. Immunohistochemically, the tumor showed a strong staining for both desmin and muscle-specific actin. Final diagnosis reported as cotyledonoid dissecting leiomyoma. Cotyledonoid dissecting leiomyoma may be gross appearance lead to a mistaken diagnosis of a malignant tumors. Therefore, both clinicians and pathologists should be well aware of these leiomyoma variants. This type of leiomyomas should be subjected to frozen section in order to avoid over treatment for especially preserve the fertility in young women.

**Keywords:** Leiomyoma, Uterus, Immunohistochemistry.

### INTRODUCTION

Conventional leiomyomas are the most common neoplasm of the female genital tract. Recently, cotyledonoid dissecting leiomyoma (CDL) was proposed for a new form of uterine leiomyoma which distinctive gross features resembling cotyledon of the placenta. CDL is categorized as a leiomyoma with an unusual growth pattern. CDL is an extremely rare variant that mimics malignant gross features but has a benign histology and biological behavior [1-3].

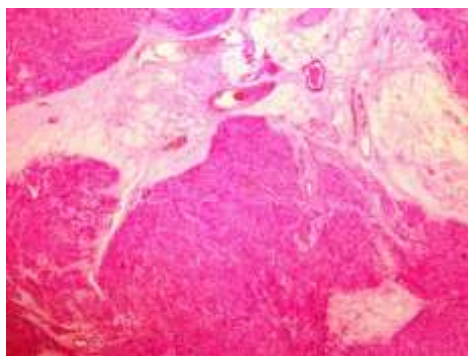
### CASE REPORT

A 46-year-old woman, presented with a 7 months history of menorrhagia, and abdominal pain. A transvaginal ultrasound scan showed a bulky uterus and left lateral aspect subserozal localization irregular borders mass. Preoperative diagnosis was estimated leiomyosarcoma. Frozen-section examination revealed a benign histology. The patient performed a total abdominal hysterectomy and bilateral salpingoophorectomy operation. Mass numerous pieces separate from the uterus was removed. Macroscopic examination specimen consisted of innumerable fragments of nodules weighing upto 192gr and measuring 12x7x6 cm. The nodules were rubbery reddish and solid, ranging from 0.7 to 3.5 cm in diameter, and these nodules were closely packed (Fig. 1). Microscopically, the tumor showed variable sized micronodules of muscle fascicles, which were separated

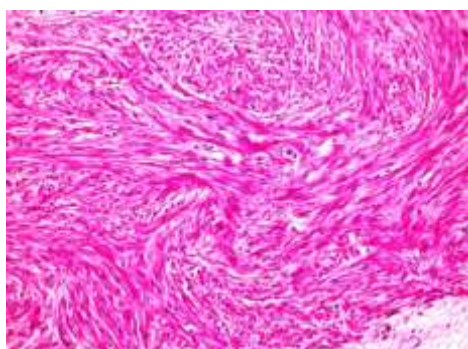
by fibrous connective tissue with a prominent hydropic change and increased vascularity (Fig. 2). Tumor was showed multinodular appearance with composed of bland smooth muscle cells growing in broad, sweeping fascicles (Fig. 3). Tumor was absent cellular atypia, abnormal cellularity, coagulative tumour necrosis or increased mitotic activity. Immunohistochemically, the tumor showed a strong staining for both desmin and muscle-specific actin (SMA) (Fig. 4). Histopathological diagnosed cotyledonoid dissecting leiomyoma of the uterus.

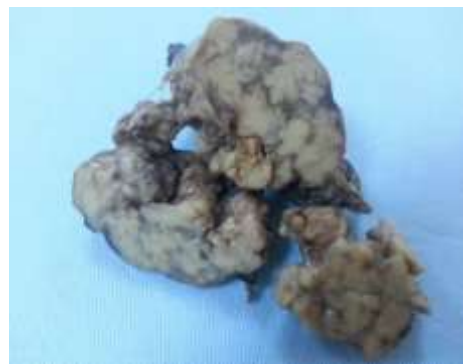

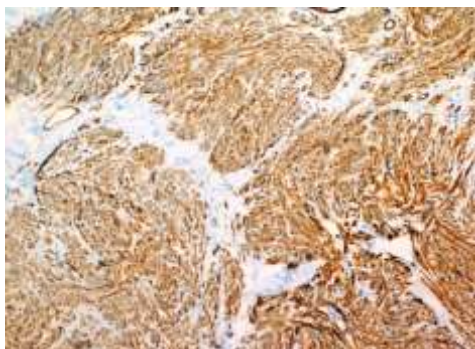
Fig. 1: Gross appearance of the resected exophytic mass shows innumerable bulbous nodules



**Fig. 2: Markedly perinodular hydropic degeneration and congested vessels around their regular bordered smooth muscle nodules (H&E stain, x100)**



**Fig. 3: The tumor cells show a swirled fascicular growth pattern. There are not present cellular atypia, abnormal cellularity, coagulative tumour necrosis and increased mitotic activity (H&E stain, x400)**



**Fig. 4: Tumor was observed diffuse positive with SMA (immunostain, x200)**

## DISCUSSION

Uterine smooth muscle tumours are known to exhibit a wide variety of growth patterns. CDL was first in 1996 described by Roth *et al.* [4]. CDL can be presented in a wide age range of patients between 23-65 years of age (mean 40.3). The most common clinical presentations are pelvic mass and abnormal uterine bleeding. CDL is usually large with an average diameter of 17.7 cm [5]. In most of the reported cases, the gross appearance of the tumor had misdiagnosis both clinicians and pathologists to malignancy suspicious.

Most of those cases had arisen from the fundus or the posterior aspect of the cornu of the uterus. Probably there is relatively more potential space for serosal tumor growth in these localizations. These cases demonstrated an exophytic component of bulbous smooth muscle, grossly resembling placental tissue protruding from the uterine surface. This exophytic mass is usually in continuity with an intramural component dissecting the surrounding myometrium [6]. Microscopically growing in dissecting pattern in the intrauterine component and cotyledonoid extrauterine extension was composed of disorganized tumorous nodules with marked hydropic degeneration. CDL revealed thin-walled, dilated, and congested vessels in the extrauterine nodules and round, muscular, and sometimes hyalinized vessels in the intramural portion. The vascular proliferation was more prominent in the fibrous septa than within the fascicles of smooth muscle [4]. In our case were observed similar findings.

Differential diagnosis includes intravenous leiomyomatosis, and leiomyoma with perinodular hydropic change. Intravenous leiomyomatosis grossly demonstrates multinodularity however exophytic component of the tumor does not show congestion and intravascular growth is characteristic [7]. Intravenous leiomyomatosis is also regarded as a benign variant of smooth muscle tumour, the vascular invasion may extend so the extrauterine pelvic veins, the inferior vena cava and even the right heart. Pulmonary metastases have also been reported and the rate of recurrence and progressive growth is higher than in typical leiomyoma [8, 9]. Multinodularity of the intrauterine component and hydropic changes in connective tissue are features of both cotyledonoid dissecting leiomyomas and some leiomyomas with perinodular hydropic degeneration. For this reason, care should be taken not to confuse these new variants of smooth muscle tumours with unusual growth patterns. This is especially important for tumours with different prognostic implications like the proposed "cotyledonoid hydropic intravenous leiomyomatosis" [10].

## CONCLUSION

CDL is a rare variant of benign leiomyoma with unusual growth patterns that gross appearance lead to a mistaken diagnosis of a malignant tumors. Therefore, both clinicians and pathologists should be well aware of such cases. This type of leiomyomas should be subjected to intraoperative frozen section in order to avoid overtreatment and fertility preservation, especially in young women.

## REFERENCES

1. Smith CC, Gold MA, Wile G, Fadare O; Cotyledonoid dissecting leiomyoma of the uterus: a review of clinical, pathological, and radiological features. *Int J Surg Pathol.*, 2012; 20(4): 330-341.

2. Kim NR, Park CY, Cho HY; Cotyledonoid dissecting leiomyoma of the uterus with intravascular luminal growth: a case study. *Korean J Pathol.*, 2013; 47(5): 477-480.
3. Weissferdt A, Maheshwari MB, Downey GP, Rollason TP, Ganesan R; Cotyledonoid dissecting leiomyoma of the uterus: a case report. *Diagn Pathol.*, 2007; 2:18.
4. Roth LM, Reed RJ, Sternberg WH; Cotyledonoid dissecting leiomyoma of the uterus: the Sternberg tumor. *Am J Surg Pathol.*, 1996; 20(12):1455-1461.
5. Saeed AS, Hanaa B, Faisal AS, Najla AM; Cotyledonoid dissecting leiomyoma of the uterus: a case report of a benign uterine tumor with sarcomalike gross appearance and review of literature. *Int J Gynecol Pathol.*, 2006; 25(3): 262-267.
6. Roth LM, Reed RJ; Dissecting leiomyomas of the uterus other than cotyledonoid dissecting leiomyomas: a report of eight cases. *Am J Surg Pathol.*, 1999; 23(9):1032-1039.
7. Kim MJ, Park YK, Cho JH; Cotyledonoid dissecting leiomyoma of the uterus: a case report and review of the literature. *J Korean Med Sci.*, 2002;17(6): 840-844.
8. Mulvany NJ, Slavin JL, Ostor AG, Fortune DW; Intravenous leiomyomatosis of the uterus: a clinicopathologic study of 22 cases. *Int J Gynecol Pathol.*, 1994; 13(1): 1-9.
9. Lo KW, Lau TK; Intracardiac leiomyomatosis. Case report and literature review. *Arch Gynecol Obstet.*, 2001; 264(4): 209-210.
10. Jordan LB, Al-Nafussi A, Beattie G; Cotyledonoid hydropic intravenous leiomyomatosis: a new variant leiomyoma. *Histopathology*, 2002; 40(3): 245-252.