

A Rare Presentation of Glomus Tumour of the Nose

Ayyagari Sudha¹, Namala Vivekanand², S A Rahman³, Nagendra Mahendra⁴

¹Consultant Pathologist, Yashodha Hospitals, Hyderabad, India

²Associate Professor, Department of Pathology, Govt. ENT Hospital, Hyderabad, India

³Consultant Pathologist, Yashodha Hospitals, Hyderabad, India

⁴Consultant ENT Surgeon, Yashodha Hospitals, Hyderabad, India

*Corresponding Author:

Name: Dr. N. Vivekanand

Email: drnivek2010@gmail.com

Abstract: Glomus tumors arise from the glomus body, a neuro-arterial structure that regulates the body temperature. Most common site is the skin and superficial soft tissues of the distal extremities, especially the subungual region. Up to 10 % of patients may have multiple lesions. Rare anatomic sites include bone, particularly phalanges, stomach, mediastinum and lung. The head and neck region is a rare site for glomus tumor, particularly nasal cavity. To the best of our knowledge this is the 26th case of glomus tumor of nasal cavity reported in literature. Our Patient is a 71 year old male presenting with nose block and nasal discharge. On examination a reddish polypoidal mass was seen medial to the right middle turbinate. There was no pain, no regional lymphadenopathy and no skin changes. An excision biopsy of the swelling was done which revealed histology of a glomus tumor. Patient was on regular follow up and is asymptomatic.

Keywords: Glomus, Nasal cavity, Polypoidal mass, Epistaxis, Vimentin

INTRODUCTION

Glomus tumors are rare tumors that are derived from the glomus cells, specialized cells that surround small blood vessels and are important in regulating peripheral blood flow. The classic presentation is a painful nail with triad of pain, tenderness and cold sensitivity. Rare anatomic sites include bone, particularly phalanges, stomach, mediastinum and lung [1]. The peak incidence is the third to fifth decades of life. The head and neck is a very rare site, representing less than 0.5% of nasal non-epithelial tumors [1].

In the subungual region, glomus tumors are observed more frequently in women; elsewhere, there is no gender bias. Superficial lesions usually appear as small, red-purple to blue nodules, often associated with pain that is sharp, paroxysmal or radiating in nature. Deeply seated tumors may be asymptomatic [2].

Malignant lesions are more likely to be larger (>2 cm) and localized in deep soft tissues. Three different clinical variants of glomangioma have been recognized: solitary, multiple, and nodular, or plaque like.

CASE REPORT

A 71 year old male presented with nose block, nasal discharge more on left side. There was no history of post nasal drip, headache, epistaxis, throat pain, tinnitus or giddiness. Patient is a known case of

hypertension and bronchial asthma on inhalers. On examination nasal Septum is grossly deviated to left, polyps are observed under medial turbinate on both sides. A reddish polypoidal mass is also seen medial to right middle turbinate (Fig. 1). All preoperative baseline investigations were within normal limits.

The patient was subjected to DNE with Excision biopsy of the right nasal mass under local anesthesia. Postoperative period was uneventful. There was no epistaxis post surgery.

Grossly, the mass was received as multiple grey white to grey brown bits of tissue with focal congested and hemorrhagic areas. Histopathological examination revealed tumor composed uniform oval and polygonal uniform cells arranged in groups. They were mostly seen lying around narrow vascular channels (Capillary sized) lined by a single layer of flattened endothelium (Fig. 2). The individual cells showed moderate cytoplasm and round uniform nuclei with uniform chromatin. Marked cytologic atypia, brisk mitotic activity or necrosis was not seen. Spindling of tumor cells is focal. Immunohistochemistry was done to look for myogenic differentiation. Smooth muscle actin showed strong cytoplasmic positivity in the tumor cells. Collagen IV, and vimentin were also positive in the tumor cells (Fig. 3). The tumor cells were negative for Pan cytokeratin, chromogranin and focal nuclear and cytoplasmic activity of S-100. These findings confirmed glomus tumor.

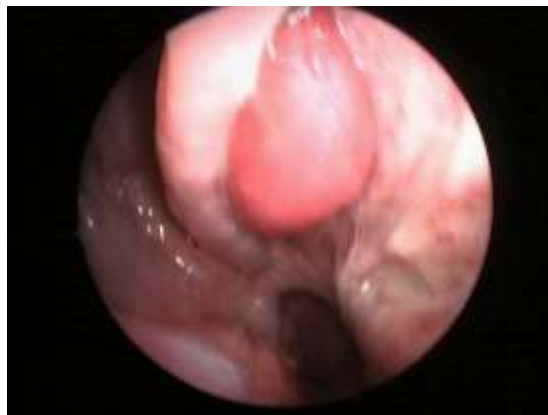

Fig. 1: Clinical Photograph: Reddish polypoidal mass

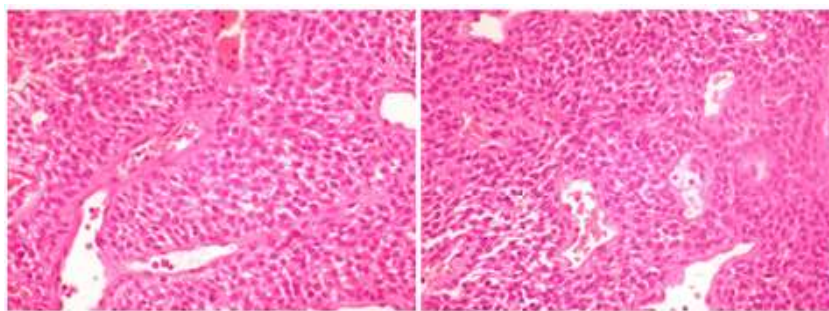


Fig. 2: 40x Hand E section of tumor showing monomorphic appearance of nuclei and pale cytoplasm in close relation to capillaries. Mitoses are not appreciated

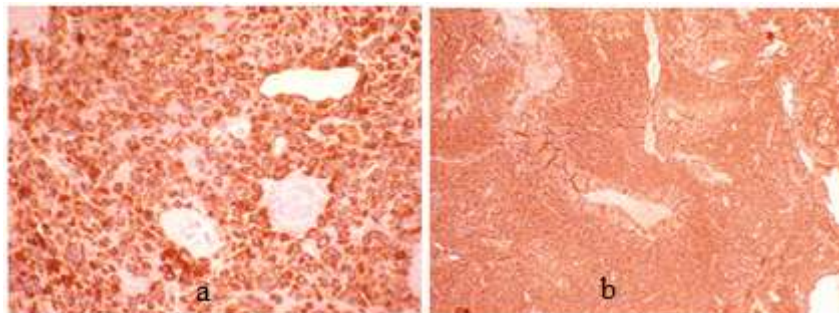


Fig. 3: (a) Vimentin: 40x IHC stain for vimentin shows diffuse strong cytoplasmic positivity, (b) 40 x IHC stain for smooth muscle actin showing diffuse strong cytoplasmic positivity

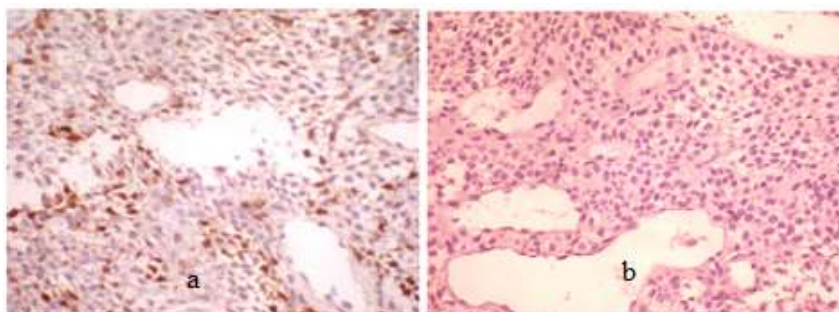


Fig. 4: (a) 40 x IHC stain for S 100 protein showing focal nuclear and cytoplasmic positivity, (b) Chromogranin-Negative

DISCUSSION

Glomus tumours are mesenchymal tumours composed of modified smooth muscle cells representing a neoplastic counterpart of the perivascular glomus body. The peak incidence is the third to fifth decades of life.

In the subungual region, glomus tumors are observed more frequently in women; elsewhere, there is no gender bias. They are found across a wide range from children to the elderly with a peak in young adults. Most glomus tumours are small benign neoplasms of the dermis or subcutis, occurring most commonly in the distal extremities (subungual or lateral digits). They also rarely occur in the sinonasal region, oral cavity, gastrointestinal tract, liver, pancreas, bone, nerve, mediastinum, lung, kidney and female genital tract [3]. The common glomus tumour is composed of capillary-sized vessels surrounded by collars of glomus cells. The glomus cells are round with a rounded nucleus. The cell outline is sharply defined, particularly with PAS or toluidine blue stains. Occasionally, abundant eosinophilic cytoplasm confers an "oncocytic" appearance [4].

Glomus cells are believed to be derived from modified smooth muscle cells which can be shown by positive immunohistochemical staining for smooth muscle actin. There are two variants of glomus tumor, glomangioma and glomangiomyoma which are characterized by a prominent angiomatous pattern and a vasculomuscular component, respectively [1].

The differential diagnoses for glomus tumor in the nasal cavity are esthesioneuroblastoma, hemangiopericytoma and myoepithelioma of minor salivary glands [3]. Clinically bleeding septal polyp (Granuloma telangiectatum sive pyogenicum sive pedunculatum) has to be considered because it often arises from Kieselbach's plexus and has a mushroom like appearance with slight bleeding [5].

Glomus tumor is distinguished from esthesioneuroblastoma by the absence of Homer-Wright rosettes. Additionally, cells of a glomus tumor contain more eosinophilic granular cytoplasm in contrast to esthesioneuroblastoma which is composed of densely packed small round cells with a scant amount of cytoplasm [9].

A hemangiopericytoma contains irregular staghorn-shaped vascular spaces and spindle tumor cells. In addition, hemangiopericytoma usually does not stain to smooth muscle actin. Myoepithelioma of the

salivary gland may be confused with a glomus tumor. Both tumors are positive for Smooth muscle actin. However, myoepithelioma is also reactive to cytokeratin and S-100 while a glomus tumor is negative for both [3].

It is proposed that glomus tumours be subdivided into benign, symplastic glomus tumour-glomus tumour with nuclear atypia but otherwise lacking criteria for malignancy (the atypia is probably a degenerative feature), and glomangiomas - angiomatosis with prominent glomus component but lacking criteria for malignancy.

Glomus tumour of uncertain malignant potential – criteria-Superficial location with high mitotic rate (5 mitoses / 50 HPF), or large size, or deep location. Malignant glomus tumour (arising from a benign glomus tumour or de novo) – Criteria -Large size (> 2 cm) and deep location, or atypical mitotic figures, or marked atypia with mitotic activity (5 mitoses / 50 HPF) [6].

Immunohistochemistry shows glomus tumor cells to be positive for vimentin and Smooth muscle Actin. Cytokeratin and S-100 are negative in glomus tumor cells. Desmin staining gives variable results and focal positivity is seen in most cases for CD 34. The neoplasm is also reactive to immunostaining for laminin and type IV collagen, which outline each tumor cell resulting in chicken wire pattern of staining. Electron microscopic studies show typical smooth-muscle myofibrils that course into typical smooth-muscle "dense bodies" in the cytoplasm and at the plasma membrane [7].

Intranasal glomus tumor is managed by complete surgical excision either by endonasal access or lateral rhinotomy. Radiotherapy should be considered when the tumor is inoperable. Most glomus tumors of the sinonasal region are benign [3]. However, local recurrences have been described in patients whose tumors have been incompletely excised. There has been only one case of aggressive glomus tumor of the nasal region, reported by Hayes et al, which presented with six local recurrences within 18 years after complete removal on all occasions. The tumor had an infiltrative edge. It seems that morphology alone is not helpful to predict the biological behavior of the tumor. Few studies suggesting that the absence of actin in a glomus tumor is correlated with a more aggressive biological behavior. In the case reported by Hayes et al the neoplasm was also negative to smooth muscle actin [8].

The terms glomus tympanicum or glomus jugulare should not be confused with glomus tumors per se. Glomus of the middle ear or carotid body are paragangliomas and the term glomus is a misnomer. Genuine glomus tumors arise from the glomus bodies which are histologically distinct from paragangliomas. To avoid further confusion the terms glomus jugulare or glomus of the middle ear should be abandoned and paraganglioma should be used instead. A paraganglioma is derived from the neural crest with neuroendocrine differentiation, demonstrable by immunohistochemical and electron microscopic studies [1]. In addition it must be understood that glomus tumor of carotid body or tympanic membrane are essentially paragangliomas. The term glomus tympanicum or glomus jugulare are misnomers and they should be called paragangliomas

CONCLUSION

This case was presented because of its rarity and clinical presentation. The histologic variants and differential diagnoses should be kept in mind as glomus can mimic hemangiopericytoma.

REFERENCES

1. Yi-Lun L, Ching-Zong L; Intranasal Glomus tumor. *Tzu Chi Med J.*, 2007; 19: 94-96.
2. Koh YW, Lee BJ; Glomus tumor of sinonasal tract- Two reports and areview of literature. *The Korean Journal of Pathology*, 2010; 44: 326-329.
3. Keelawat S, t Hirunwiwatkul P; Recurrent Epistaxis from an intranasal glomus tumor: the 22nd case report. *J Med Assoc Thai*, 2004; 87: 442-445.
4. Weiss SW; Perivascular tumors. In Goldbum JR editors; *Soft Tissue Tumors*, 4th edition, St Louis: Mosby, 2001: 985-1035.
5. Matschiner F, Bilkenroth U; Glomus tumor of the nose. 1999; 47(2): 122-125.
6. Folpe AL, Fanburg-Smith JC, Miettinen M, Weiss SW; Atypical and malignant glomus tumors: analysis of 52 cases, with a proposal for the reclassification of glomus tumors. *Am J Surg Pathol.*, 2001; 25(1): 1-12.
7. Chu PG, Chang KL Wu AY, Weiss LM; Nasal glomus tumors: report of two cases with emphasis on immunohistochemical features and differential diagnosis. *Hum Pathol.*, 1999; 30(10):1259-1261.
8. Hayes MM, Van der Westhuizen N, Holden GP; Aggressive glomus tumor of the nasal region. Report of a case with multiple local recurrences. *Arch Pathol Lab Med.*, 1993; 117(6): 649-652.