

Accessory middle lobe in the left lung:a morphological Variation

Dr. H P Sarma*, Dr. Manirul Islam

Department of Anatomy, AGMC & GBP Hospital, Aartala, Tripura (W), India

*Corresponding Author:

Name: Dr. H P Sarma

Email: hpsarma71@rediffmail.com

Abstract: Morphological variations in presence of fissures and lobes of lung are of great significance to anatomists as well as cardiothoracic surgeon. The present case reports a rare middle lobe as well as an additional fissure in left lung in an adult male cadaver. The clinical importance of the variations is correlated and discussed.

Keywords: Lung, Lobes, Fissures, Accessory

INTRODUCTION

The anatomical knowledge of the fissures and the lobes of the lung is important for accurate interpretation on x-rays and CT scans. The right lung is divided into superior, middle and inferior lobe by an oblique and horizontal fissure. The oblique fissure divides the inferior from superior lobe. A short horizontal fissure separates the middle lobe from the superior lobe. But in case of left lung, the oblique fissure separates the superior and inferior lobe. There is no middle lobe and horizontal fissure in left lung. The superior lobe includes the apex, anterior border and most of the costal and medial surface of lung. At the lower end of anterior border of lung the cardiac notch and a small process called lingual is present [1,2]. This lingual of left lung represents the middle lobe of right lung. The inferior lobe represents the base, much of costal and lower part of posterior border of lung. But occasionally the left horizontal fissure is a normal variant [2]. The knowledge of anatomical variations of lobes of the lung is important for the identification of identifying broncho pulmonary segments. Radiologists may misinterpret an x-ray or a CT scan many a times. Anatomical knowledge of such variations is useful for lobectomies and surgical resections involving individual segments [3].

CASE REPORT

During routine dissection of undergraduate teaching of a 45 years old adult male cadaver in the dept of Anatomy, AGMC, it was observed that in the left lung there is presence of additional horizontal fissure. The fissure extends from the anterior axillary line to the above the cardiac notch of anterior border of lung. The fissure extends on the medial surface above the hilum. A wedge shaped middle lobe is present between the oblique fissure and horizontal fissure which includes the cardiac notch and ligula. The structure of the hilum is normal. The right lung is

normal with two fissures and three lobes with normal hilum. The specimen is collected and preserved. Fig. 1 shows the accessory lobe in the left lung seen from medial surface.

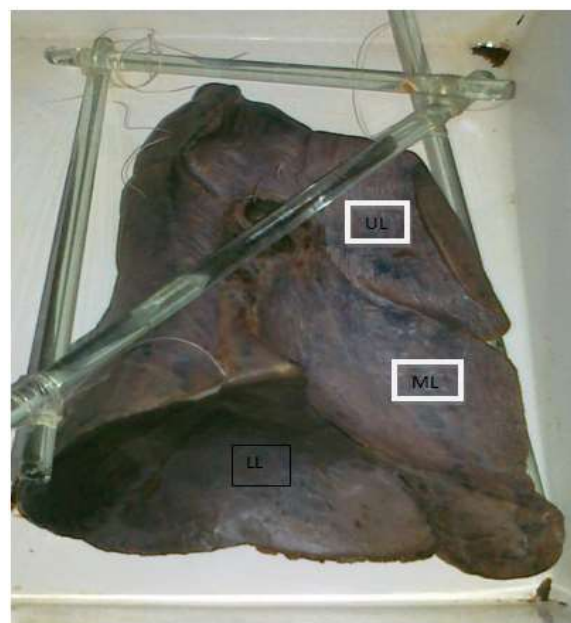


Fig. 1: Shows the accessory lobe in the left lung seen from medial surface.

DISCUSSION

During the development of lungs the spaces or fissures that separate individual bronchopulmonary buds/segments become obliterated except along two planes, evident in the fully developed lungs as oblique or horizontal fissures. Absence or incomplete oblique or horizontal fissure could be due to obliteration of these fissures either completely or partially. Accessory fissure could be the result of non-obliteration of spaces which normally are obliterated. The accessory fissure may be

of varying depth occurring between bronchopulmonary segments. The inferior accessory fissure which demarcates the medial basal segment, and superior fissure which demarcates the superior segment, are the most common accessory fissures detected on CT scan. The presence of middle lobe and a horizontal fissure is a normal variant occasionally [2]. The number of lobe in the right lung may be two, accessory lobes may also be present. Accessory lobe in the right lung is a common variant than the left lung and is present in one percent of cases [4]. In some cases, lung fissures may not be complete to divide the lobes separately [5]. Accessory lobes of the lung when present may be due to developmental anomaly [6]. It is also noted that right lung may have as many as five lobes with one infracardiac and one azygos lobe [7]. In a study on morphological variation of lung fissures and lobes, to know the lobes anatomy and broncho pulmonary segment in 30 pairs of lung in cadaver, it was found that 5 nos of right lung horizontal fissure is absent. In 19 nos of cases there was incomplete horizontal fissure and in 2 cases horizontal fissure was absent. Accessory lobe was present in 3 left lung [8]. In another study accessory fissure in left lung was observed in 35% cases. Horizontal fissure was absent in 7% and incomplete in 39% cases [9]. Knowledge of an accessory fissure is helpful for clinicians in order to differentiate it from other normal anatomical and pathological structures. Interpretations of various radiographic appearances of inter lobar fluid are important for clinicians. In x-ray, incomplete fissure always give an atypical appearance of pleural effusion. Many a times the accessory fissure fails to be detected on CT scans, because of their incompleteness, thick sections and orientation in relation to a particular plane [9]. The knowledge of anatomy of fissures of lung may help clarifying confusing radiographic findings like extension of fluid into an incomplete major fissure or spread of various diseases through different pathways [10]. Considering the clinical and surgical importance of such variations, from anatomical point of view, one can opine that prior anatomical knowledge and high index of suspicion for probable variations in the fissures, lobes and broncho pulmonary segments in the lung may be important for clinicians, surgeons and radiologists.

REFERENCES

1. Romanes GJ; Cunningham's manual of practical anatomy. Volume 2, Oxford Medical Publications, New York, 1996: 32–33.
2. Larsen WJ; Human Embryology. Churchill Livingstone, New York, 1993: 111–130.
3. Nene AR, Gajendra KS, Sarma MVR; A variant oblique fissure of left lung. International Journal of Anatomical Variations, 2010; 3: 125–127.
4. Kent EM, Blades B; The surgical anatomy of the pulmonary lobes. J Thorac Surg., 1942; 12: 18–30.
5. Rosse C, Gaddum-Rosse P; Hollinshed's Textbook of Anatomy, Lippincot-Raven, Philadelphia, 1997: 441–461.
6. Aldur MM, Denk CC, Celik HH, Tascioglu AB; An accessory fissure in the lower lobe of the right lung. Morphologie, 1997; 81(252): 5–7.
7. Ariyurek OM, Gulsun M, Demirkazik FB; Accessory fissures of the lung: evaluation by high-resolution computed tomography. EurRadiol, 2001; 11(12): 2449–2253.
8. Walker WS, Craig SR; A proposed anatomical classification of the pulmonary fissures. J R CollSurgEdinb, 1997; 42(4): 233–234.
9. Godwin JD, Tarver RD; Accessory fissures of the lung. AJR Am J Roentgenol, 1985; 144: 39–47.
10. Dandy WE Jr, Incomplete pulmonary interlobar fissure sign. Radiology, 1978; 128(1): 21–25.