

## Congenital Familial Clubbing: A Case Report

Shubhankar Mishra, Bhagabata Swain

Department of paediatrics, M.K.C.G. Medical College, Berhampur, Odisha, India

### \*Corresponding Author:

Name: Dr.Shubhankar Mishra

Email: [dr.subham.sc.b@gmail.com](mailto:dr.subham.sc.b@gmail.com)

**Abstract:** Clubbing of digit is always thought to be acknowledgement of some internal disease. Sometimes it may be a silent finding. Very rarely child is born with clubbing. In some families clubbing is seen without any disease. We are presenting a case where we found isolated clubbing of fingers and toes of a family in four generations.

**Keywords:** Congenital familial clubbing, Autosomal recessive

### INTRODUCTION

The history of evidence of clubbing dates back to 400 BC. Hippocrates described about it in an empyema patient. Digital clubbing is characterized by a bulbous enlargement of the terminal segments of the fingers and/or toes due to proliferation of connective tissue between nail matrix and the distal phalanx. It results in increase in both antero-posterior and lateral diameter of the nails. Clubbed fingers are also known as watch-glass nails, drumstick fingers [1]. Till today clubbing is controversial. The causes are exhaustive list. Cardiac, respiratory, gastrointestinal causes are much more common. The congenital form of clubbing is very rare phenomenon which are two types [2]:

a) Congenital familial clubbing, b) congenital clubbing associated with pachydermoperiostitis

Congenital familial clubbing is a very rare phenomenon. It is autosomal recessive trait [3]. There are other schools of thoughts also. Previously it was hypothesized to be autosomal dominant [4]. Yet lots of works to be done on these families, still today congenital familial clubbing is very rarely reported in our country. The cause and its association with development of child is not derived. The aim of this report is to highlight the familial cause of clubbing and facilitate further research in this field. It will further broaden our knowledge about aetiology and pathophysiology of the Hippocrates finger.

### CASE REPORT

A 3 year male child was presented with chief complaint of fever for 15 days and swelling of fingers and toes since birth.

Fever was high grade and was associated with chills and rigors, and was measured to be 101 degree F. fever subsided taking medication but to relapse again.

Swelling in fingers and toes were painless and non progressive. No history of any other abnormality was there. He had no significant past history and developmental history. He was immunized according to age and was taking regular Indian diet. On careful history taking it was found that his paternal grandmother had similar swelling in finger and toes. The grandmother revealed that some of her family member had similar swelling in fingers and toes.

The pedigree chart:

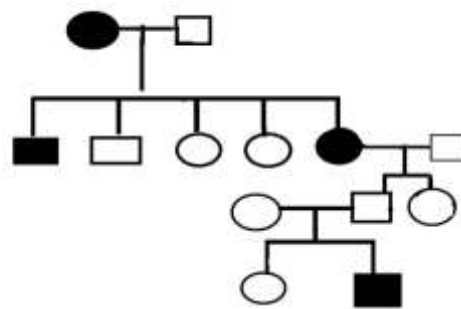


Fig. 1: Pedigree chart of involved family, Black marked circle and squares are effected progeny

On general examination the patient was conscious cooperative. Pulse rate was 120/min and BP was 90/60mmhg. Mild pallor was there with grade 3 clubbing. No lymphadenopathy icterus,cyanosis was there. Clubbing was present in all the fingers and toes. Clubbed fingers and toes were fluctuation test positive,increased onychodermal angle,convex nailfold and distal fingers and toes were all thickened.

All respiratory,cardiovascular and central nervous system examinations were in normal limits.The abdominal

The patient was worked up for any hidden disease. Blood test revealed normal range except Hb-6 gm% MP ICT (optimal) was positive. Widal test was negative. Routine microscopy of urine was normal. Chest X-Ray and ECG were normal. X-Ray of hand and foot showed no abnormality. The abdominal examination revealed mild enlargement of spleen in midaxillary line towards umbilicus. Splenic notch was not palpable. The photos of grandmothers hand and patients hand taken. They are very similar.

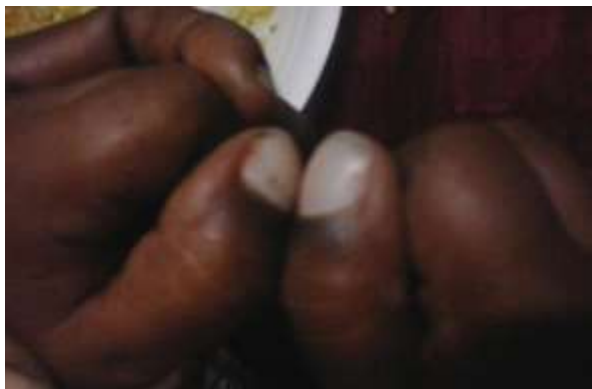

Fig. 2: Bilateral clubbing

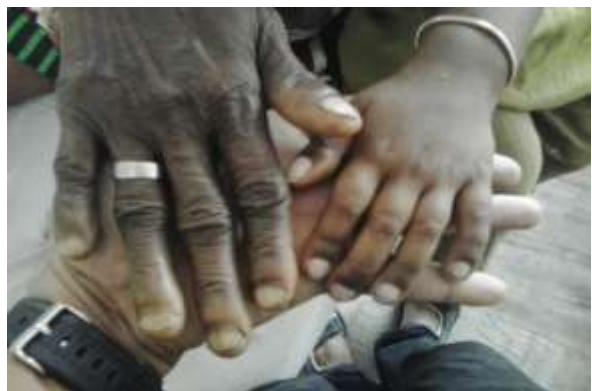

Fig. 3: similar type of clubbing in grandmother and patient

## DISCUSSION

The hippocratic finger is still an enigma to the physicians. Its cause is yet to be understood completely. Congenital nail clubbing is usually symmetrical and bilateral, but different fingers and toes may be involved to varying degrees. Some may be spared, but the thumbs are always involved [1]. Though very rare its found in some families. Researches reveal that the anomaly is due to mutation of HPGD gene encoding NAD<sup>+</sup> dependant 15-hydroxy prostaglandin dehydrogenase [3]. Mutations in the prostaglandin transporter (PGT) encoding gene SLCO2A1 which result in reduced metabolic clearance by 15-PGDH due to diminished cellular uptake of prostaglandin E<sub>2</sub>, PGE<sub>2</sub> by mutant PGT [5]. The linkage is associated in 4q [3]. Patients with unexplained clubbing, genetic

testing for HPGD mutation, and measurements of PGE<sub>2</sub> may become an important diagnostic tool in future. The trait is previously identified as autosomal recessive. Due to this mutation there is major production of connective tissue in nail bed and abnormal function of nail matrix. There are very less documented cases of families having such connective tissue proliferation in nail bed without any abnormal systemic features.

## CONCLUSION

This family of congenital familial clubbing is most probably showing the autosomal recessive trait features. So our report is with the previous studies.

## REFERENCES

1. Sarkar M, Mahesh DM, Madabhavi I; Digital clubbing. Lung India, 2012; 29(4): 354-362.
2. Peerbhoy MS, Rajan KE, Deoskar RB, Barthwal MS; Idiopathic Clubbing. J Assoc Physicians India, 2006; 54: 506.
3. Tariq M, Azeem Z, Ali G, Chishti MS, Ahmad W; Mutation in the HPGD gene encoding NAD<sup>+</sup> dependent 15-hydroxyprostaglandin dehydrogenase underlies isolated congenital nail clubbing (ICNC). J Med Genet., 2009; 46(1):14-20.
4. Seaton DR; Familial Clubbing of the Fingers and Toes. The British Medical Journal, 1938; 1: 614.
5. Seifert W, Kühnisch J, Tüysüz B, Specker C, Brouwers A, Horn D; Mutations in the prostaglandin transporter encoding gene SLCO2A1 cause primary hypertrophic osteoarthropathy and isolated digital clubbing. Hum Mutat., 2012; 33(4): 660-664.