

## Malignant Sclerosing Sertoli Cell Tumour of Testis: A Rare Case Report with Review of Literature

I.Sreelakshmi<sup>1</sup>, Anunayi J<sup>2</sup>, V.V.Sreedhar<sup>3</sup>, Lavanya Motrapu<sup>4</sup>, Keerthi Prakash K<sup>5</sup>, K.Praveen Kumar<sup>6</sup>

<sup>1,2</sup> Associate Professor, Upgraded Department of Pathology, Osmania Medical College/ General hospital, Hyderabad, Andhra Pradesh-500001, India

<sup>3</sup> Professor & HOD, Upgraded Department of Pathology, Osmania Medical College/ General hospital, Hyderabad, Andhra Pradesh-500001, India

<sup>4</sup> Assistant Professor, Upgraded Department of Pathology, Osmania Medical College/ General hospital, Hyderabad, Andhra Pradesh-500001, India

<sup>5,6</sup> Postgraduate Resident, Upgraded Department of Pathology, Osmania Medical College/ General hospital, Hyderabad, Andhra Pradesh-500001, India

### \*Corresponding Author:

Name: Dr. I. Sreelakshmi

Email: [sreelakshmi123123@rediffmail.com](mailto:sreelakshmi123123@rediffmail.com)

**Abstract:** Sex cord stromal tumors of testis are rare, in which Sertoli cell tumor accounts for <10% of testicular neoplasms. Commonest age group includes 1<sup>st</sup> to 7<sup>th</sup> decade. Mean age being 42 years. Malignancy in sertoli cell tumor is very rare accounting for 1/10 and very few cases are reported in literature. These tumors are seen mostly in descended testes and known to have variable histological appearances. Vast majority are sporadic but some are associated with genetic syndromes. Here we report a case of rare sclerosing sertoli cell tumor with malignant transformation in a 29 years old patient representing a distinctive, therefore less described sub type of sertoli cell tumor in the testis. The purpose of this article is to describe a tumor which originates from primitive gonadal mesenchyme and shows the potentiality of its cells. This case is presented for its extreme rarity.

**Keywords:** Malignant Sertoli cell tumour , sex cord stromal tumour, testicular tumour, tubular pattern

### INTRODUCTION

Testicular tumors are classified into five general categories [2]. Germ cell tumors arising from germinal epithelium of seminiferous tubules, sex cord stromal tumors, and mixed germ cell sex cord stromal tumors, primary tumors not specific to testis and metastatic tumors. Sertoli cell tumors arise in the descended testis of normal individuals and sometimes associated with gynecomastia [1].

Vast majority of sertoli cell tumors are sporadic but some tumors have been associated with genetic syndrome such as androgen insensitivity syndrome, Carney syndrome and Peutz Jeghers syndrome. 40% patients have endocrine disorders which include precocious puberty, gynecomastia, with bilaterality. Imaging characteristics are non specific and indistinguishable from germ cell tumors. Sometimes calcifications are readily seen by ultrasound [3].

Sertoli cell tumor is strongly suggested when calcified testicular masses are identified in the pediatric age group. About 1/10<sup>th</sup> of sertoli cell tumors show malignant transformation. The most common site of metastatic involvement being the iliac and para aortic lymphnodes [3, 4]. Features that should raise the

suspicion of malignancy in sertoli cell tumor include tumor size 5cms or greater, pleomorphism, mitotic activity of more than 5/10 HPF,vascular invasion and necrosis.

### CASE REPORT

A 29 year old patient presented with left scrotal swelling, was apparently normal 1 year back and gradually increasing from three months and attained present size of 13X10X7 cms. Past history revealed treatment for hydrocele by a local doctor. On examination Right side testis was normal in size of 4.5X1.5cms left side testicular mass measured 13X10X7cms, tender on palpation and firm to hard in consistency. Ultrasound of scrotum revealed changes of chronic epididymoorchitis with minimal hydrocele with a suspicion of malignancy. No clinical evidence of hormonal disturbances noted. Routine laboratory investigations were within normal limits. Serum Alpha Feto Protein (AFP) levels were within normal limits. Other hormonal assays were normal. No evidence of organomegaly in the abdomen.

### Pathological features

Orchidectomy specimen measured 13X10X6.5+ cms along with tunica. Cut section of

tumor revealed lobulated, solid grey-white nodular areas with focal areas of haemorrhage. No necrotic areas seen. No normal testis identified. Microscopic examination of sections revealed nodular aggregates of tumor tissue with partial encapsulation, cells arranged predominantly in tubular, tubulopapillary pattern and in solid sheets. Tumor cells were round to oval, hyperchromatic and pleomorphic nucleus, with pale eosinophilic cytoplasm. Mitotic activity was 3-4/10 HPF. Large areas of fibrosis and hyalinised stroma were conspicuous with microcalcifications. Areas of haemorrhage, necrosis were seen. With differential diagnosis of sertoli cell nodule and leydig cell tumor, Immunohistochemistry was done for cytokeratin and vimentin which confirmed the diagnosis of sclerosing sertoli cell tumor.

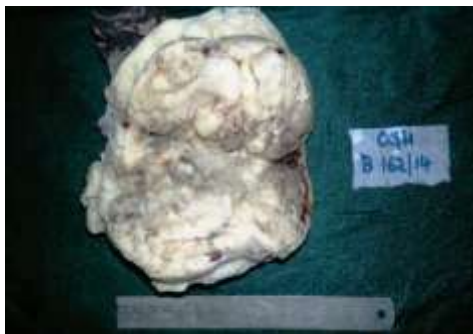

Fig 1: Cut section of orchidectomy specimen revealed grey white nodular areas

#### Microscopy

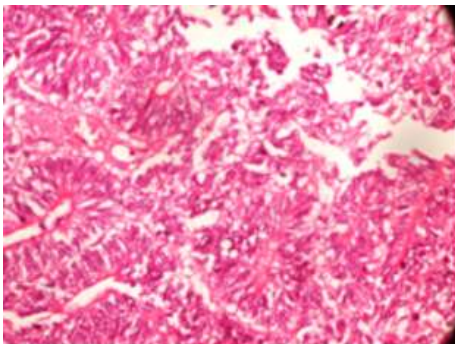


Fig. 2: 10X H&E showing tumor cells arranged in tubules

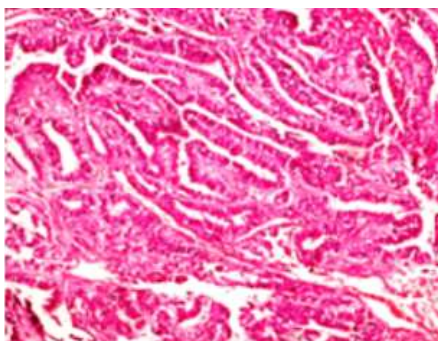


Fig. 3: 10X H&E showing tumor cells near rete testis

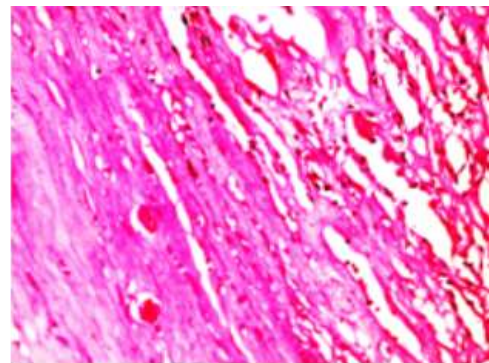


Fig. 4: 10X H&E extensive stromal fibrosis and micro calcifications

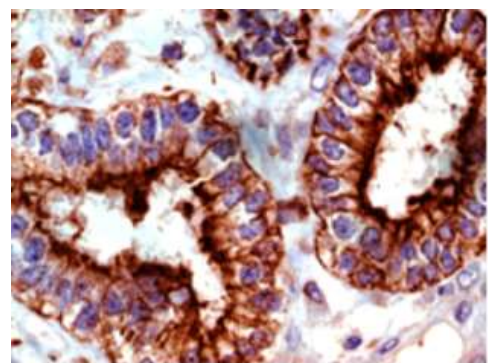


Fig. 5: Immuno Histo Chemistry with Epithelial Membrane Antigen (EMA clone E29) shows membrane positivity in tumor tissue

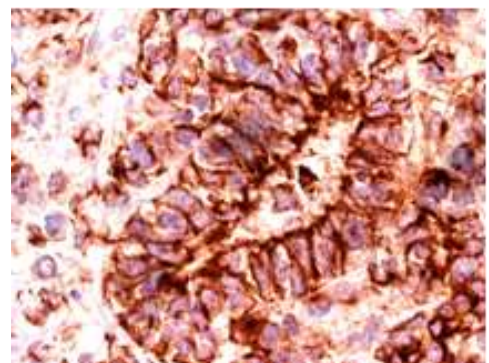


Fig. 6: Immuno Histo Chemistry with Vimentin (clone V9) shows strong diffuse cytoplasmic positivity

#### DISCUSSION

Sex Cord – stromal tumors of the testis are uncommon and have been less well characterized than similar tumors of the ovary, majority of them fall in the “Unclassified” category [4]. Sertoli cells normally seen only in the testis, but sertoli cell tumors occur not only in the testis but also in the ovary.

Sertoli tumors are classified under gonadal sex cord stromal tumors and account for <1% of testicular neoplasms. It occurs in males between 1<sup>st</sup> and 7<sup>th</sup>

decade. About 1/10<sup>th</sup> of sertoli cell tumors are reported malignant. Such tumors have tendency to invade locally and to metastasize. Most common site of metastatic involvement are iliac and para aortic lymph nodes. Left side involvement of testis is the common observation noted in most of the studies [4].

Sertoli cell tumor needs to be distinguished from sertoli cell nodule which are non neoplastic lesions composed of aggregates of small tubules lined by immature sertoli cells and contain prominent basement membrane deposits, spermatogonia in varying proportions, confined, no infiltration to surrounding stroma [6]. Leydig cell tumor is another differential diagnosis, here the tumor cells are medium to large polygonal with abundant eosinophilic cytoplasm with distinct cell borders. Reinke crystalloids are noted in 30-40% of cases. Usually these tumors are hormonally active leads to either feminizing or virilizing syndromes. Immunohistochemistry with  $\alpha$ -inhibin, calretinin and melan-A helps in differential diagnosis [7].

Sertoli cell tumors are positive for antibodies to Vimentin (90%) and Cytokeratin (80%) where as Leydig cell tumors are negative for Cytokeratin and positive for steroid hormones and S100 protein [2, 3]. Large cell calcifying sertoli cell tumors shows broad areas of calcification [8]. Prognosis is generally good as the tumor tends to grow slowly. It is considered that conservative resection of tumor is treatment of choice [9].

## CONCLUSION

Sex-cord tumors of the testis are uncommon and have been less well characterized than similar tumors of the ovary with a much greater proportion of them falling in the "Unclassified" category. Hence we report pathological features of sclerosing sertoli cell tumor representing a distinctive, rare subtype of sertoli cell tumor in testis for its prognostic implications and treatment modalities.

## REFERENCES

1. Mostofi FK, Thesis EA, Ashley DJ; Tumors of specialized gonadal, stroma in human male patient androblastoma, Sertoli cell tumor, granulosa-theca cell tumor of the testis, and gonadal stromal tumor. *Cancer*, 1959; 12: 944-957.
2. Rosai J; Rosai and Ackerman's Surgical Pathology. 10<sup>th</sup> edition, Volume 1, chapter 18, 2011: 1338
3. Eble JN, Sauter G, Epstein JI, Sesterhenn IA; World Health Organization Classification of Tumors. Pathology and genetics of tumors of the Urinary System and Male Genital Organs. IARC Press, Lyon 2004.
4. Young RH, Koelliker DD, Scully RE; Sertoli cell tumors of the testis, not otherwise specified: a clinicopathologic analysis of 60 cases. *Am J Surg Pathol.*, 1998; 22(6): 709-721.
5. Zukerberg LR, Young RH, Scully RE; Sclerosing sertoli cell tumor of the testis: a report of 10 cases *Am J Surg Pathol.*, 199;15(9): 829-834.
6. Vallangeon BD1, Eble JN, Ulbright TM; Macroscopic Sertoli Cell Nodule: A Study of 6 Cases That Presented as Testicular Masses Vallangeon, *American Journal of Surgical Pathology*. 2010; 4(12): 1874-1880.
7. Al-Agha OM, Axiotis CA; An in depth look at leydig cell tumor of the testis. *Arch Pathol Lab Med.*, 2007; 131(2): 311-317.
8. Proppe KH, Scully RE; Large cell calcifying sertoli cell tumor of the testis. *Am J Clin Pathol.* 1980; 74(5): 607-19.
9. Golombos D, Brison D, Sadeghi-Nejad H; Malignant Sertoli tumor of testis with a large retro peritoneal mass in an elderly man. *Urology Journal*, 2010; 7(4): 281-283.