

## Malignant Granular Cell Tumor (Abrikossoff Tumor)

Raouah Mehdi\*, Saadoune Mohamed, Bouchabaka Yassine, El Matlini Abdelali, Igarramen Tariq, Laatitioui Sana, Bounid Oumyama, Darfaoui Mouna, Lalya Issam, Abdelahamid El Omrani, Khouchani Mouna

Radiation Oncology Department, Mohammed VI University Hospital, Marrakech, Morocco

DOI: [10.36347/sjmcr.2020.v08i04.011](https://doi.org/10.36347/sjmcr.2020.v08i04.011)

| Received: 24.03.2020 | Accepted: 31.03.2020 | Published: 14.04.2020

\*Corresponding author: Raouah Mehdi

### Abstract

### Case Report

A granular cell tumour (GrCT) is a benign soft tissue tumor which is quite rare, that likely arises from Schwann cells, with unknown etiology. Approximately 0.5% - 2.0% of GrCTs are reported as malignant. Differentiating a malignant GCT (MGCT) from a benign one is important as the former is aggressive and has a poor prognosis, whereas the latter, after surgical resection, has excellent outcomes. A malignant lesion can be suspected on clinical presentation and confirmed via histopathological examination using the Fanburg-Smith criteria. We believe that wide local excision is the best treatment for both benign and malignant tumours. The role of adjuvant chemotherapy and radiotherapy in malignant GrCTs should be studied. All patients with GrCTs should receive follow-up to check for recurrence and metastasis. We report a rare case of swelling of soft tissue involving the lower lip in a 89 years old female patient which was histopathologically diagnosed as MGCT with a brief on review of literature has been discussed.

**Keywords:** Malignant granular cell tumor, radiation therapy.

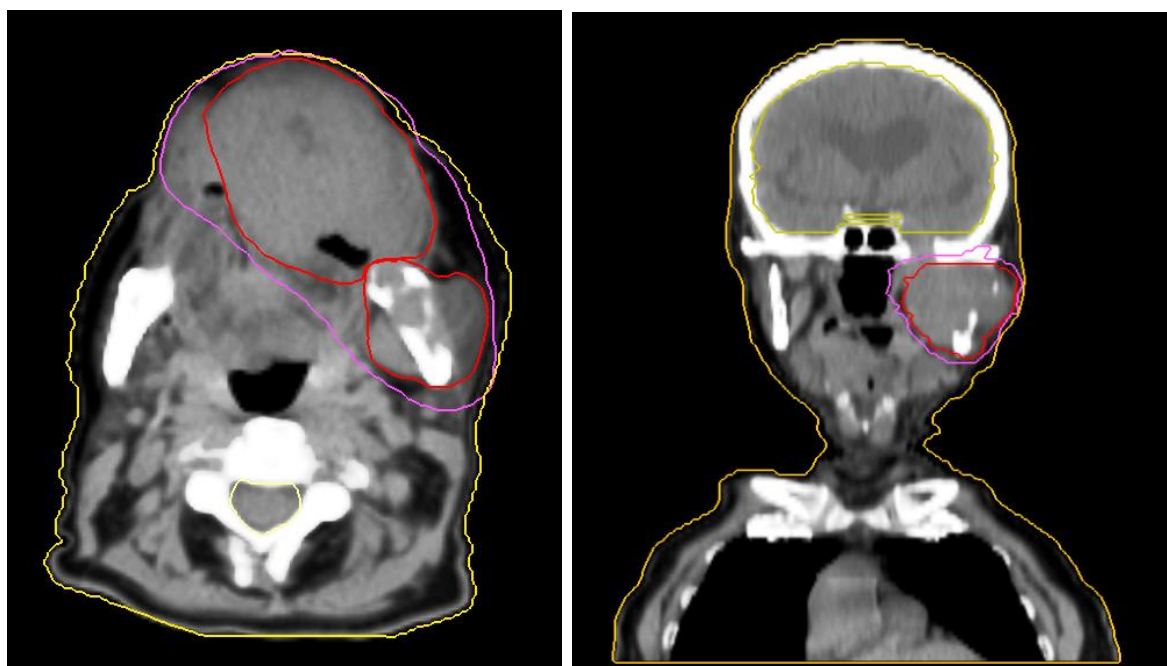
**Copyright @ 2020:** This is an open-access article distributed under the terms of the Creative Commons Attribution license which permits unrestricted use, distribution, and reproduction in any medium for non-commercial use (NonCommercial, or CC-BY-NC) provided the original author and source are credited.

## INTRODUCTION

Granular cell tumor (GCT) is rare and accounts for approximately 0.5 % of all soft tissue tumors [1]. Described by Abrikossoff as "myoblastic myomata" in 1926, GCT is a fairly common soft tissue lesion of Schwann cell origin [2, 3]. Arising most commonly from the head and neck region followed by the chest wall and the arm, it pursues a benign clinical course with low recurrence rate [3, 4]. Approximately 0.5%–2.0% of GCTs are reported as malignant [5]. A malignant Granular cell tumor (MGCT) is aggressive and has a poor prognosis [6], whereas a benign lesion has excellent outcomes after surgical resection [5]. MGCTs have a high rate of metastasis and recurrence, with a mortality rate of 40% [7]. Thus, differentiating a malignant tumour from a benign tumour is important. A malignant lesion can be suspected on clinical presentation and confirmed via histopathological examination using the Fanburg-Smith criteria [6, 8]. We herein present a new case of MGCT with gross, cytological, light microscopic, immunohistochemical, and electron microscopic findings and emphasize the features that appear to be associated with malignancy in conjunction with a review of the recent literature.

## CASE REPRESENTATION

An 81 year-old female patient, presented with painful growth, non-movable, bleeding, sub mucosal lump in the lower lip of approximately ten months duration. No specific history could be elicited, patient suffering from diabetes and hypertension otherwise she was healthy. Physical examination revealed ulcerative budding lesion of the lower lip, with irregular and raised edges, brittle, with bleeding on contact. Lesion was 5.5 cm in size. The OPG results were non contributory. Computed tomography (CT) of the head and neck region showed a 53×32×36 mm soft tissue mass centered on the lower lip, extended down to the ramus of the mandible with bony destruction, involved the floor mouth muscles, the masseter muscle, and the pterygoid muscle. An excisional biopsy was performed under local anesthesia and tissue was sent for histopathology. Histopathological examination revealed enough criteria to give diagnosis of malignancy: nuclear pleomorphism, increased mitotic activity, vesicular nuclei with large nucleoli. Immunohistochemistry findings confirmed the diagnosis of granular cell tumor which is positive for S100 protein and CD68 antibodies. The tumor was judged unresectable, and the patient inoperable, therefore exclusive radiationtherapy was decided as a therapeutic option and alternative to surgery. Currently our patient is undergoing radiotherapy sessions.



## DISCUSSION

Granular cell tumor was first described in German literature in 1926 and named myoblastoma, with believed to be of myogenic origin because of its origin from the tongue muscle [2]. The tumor was thought to have a neural origin because it was assumed to be from the radial and sciatic nerves within the extremities in 1960s [9]. Schwannian features have been documented ultrastructurally and immunohistochemically [10-14]. This rare tumor can affect various regions of the body, but more frequently found in the head and neck commonly involving the tongue.

Malignant granular cell tumors constitute an infrequent entity (1-2% of all granular cell tumors) [3]; their existence has been questioned, and it remains a controversial neoplastic disease. The majority of GCT are benign, although they may be locally aggressive. Despite the fact that the malignancy of these tumors depends on clinical parameters such as the presence of relapses and metastatic disease or location in deep soft tissues, the majority of MGCT are located deep in soft tissue. Granular cell tumor usually presents with a painless mass occurring most during 30–50 years old. Women are more commonly affected with a ratio of 1.8-2.9:1 to men. The best imaging modality for the characterization of this tumor is magnetic resonance imaging (MRI) [9]. Clinical findings for prediction of malignancy includes large tumor size (>5 cm), older age, female gender, oval or round shape, deep location (intramuscular), occurrence in the lower extremities, rapid recent growth after an extended period, and local recurrence [15]. In our case, the following factors in the patient were highly indicative of the tumour's malignancy: a tumour that was (a) large (> 5 cm), (b)

showed rapid recent growth, and being of (c) an older age group and (d) of female gender.

The differential diagnosis of MGCT includes renal cell carcinoma, rhabdomyosarcoma, and alveolar soft part sarcoma, ect. However, the diagnosis usually can be confirmed by the histomorphology and immunohistochemical profile. A diagnosis of GrCT can be made easily as such tumours have distinctive histological features [7, 16]. However, the origin of the cells and its pathogenesis are still under debate. GrCTs were initially named 'granular cell myoblastomas' as it was thought that the tumours arose from striated muscle cells [6]. Under microscopy, the tumour cells are visualised as large and polygonal or round in shape, with vesicular nuclei and abundant eosinophilic granular cytoplasm [7]. The cells are usually separated by fine bands of connective tissue [4] or sclerotic collagenous tissue [6]. It is possible for the overlying skin to undergo pseudoepitheliomatous hyperplasia [17]. Currently, the hypothesis that the tumours are neural in origin is widely accepted. Most GrCTs are cytoplasmic and nuclear positive for S-100 and neuron-specific enolase [6] supporting this hypothesis. GrCTs are also strongly positive for vimentin and CD68 [16, 6]. The tumours are occasionally found near nerves [17].

Fanburg-Smith et al. reported histologic criteria for MGCT by analyzing the clinical and histologic data of 73 cases of granular cell tumors. According to their report, the six features include necrosis, spindling, vesicular nuclei with large nucleoli, increased mitotic activity (>2 mitoses/10 high-power fields at 200× magnification), high nuclear to cytoplasmic (N:C) ratio, and pleomorphism. Neoplasms that met three or more of these criteria were classified

as histologically malignant, which may result in death in 40 % of cases because of the high chance of local recurrence and metastasis. Those that met one or two criteria were classified as atypical; and those that displayed only focal pleomorphism but fulfilled none of

the other criteria were classified as benign with no metastasis or local recurrence after adequate resection. Poor prognostic factors associated with MGCT include large tumor size, older patient age, increased mitotic activity and Ki-67 greater than 10 % [6].

**Table-1: Fanburg-Smith criteria and immunohistochemical findings**

Patient	Fanburg-Smith criteria						Diagnosis	Immunohistochemical stainings (+ve)
	Spindling cells	Increased nuclear: cytoplasmic ratio	Vesicular nuclei, large nucleoli	Pleomorphic nuclei	Necrosis	Increased mitotic activity		
1	NA	NA	NA	NA	NA	NA	Benign	NA
2	NA	X	NA	X	X	X	Benign	S100,NSE,Vimentin
3	NA	NA	NA	NA	NA	NA	Benign	CD68,S100,NSE,Vimentin
4	✓	X	✓	✓	X	✓	Malignant	S100
5	NA	NA	NA	✓	X	NA	Atypical	CD68,S100,NSE

NA : not available; NSE : neuron-specific enolase

It is challenging to differentiate benign GrCTs from malignant GrCTs histologically. Often, the tumour is not well-circumscribed and can present with a thin capsule or without a capsule. Microscopically, it is frequently poorly encapsulated and grossly infiltrating [8, 16]. It is usually found invading the surrounding structures. A case series by Thacker et al included a case in which a tumour was treated as a benign GrCT, according to histological findings, but the patient presented a year later with lung metastasis [17]. Thus, the diagnosis of a malignant GrCT requires evaluation of both clinical findings and histological results. While the reported extent of surgical excision for GrCTs is variable, wide local excision is recommended, irrespective of the benign or malignant nature of the tumour, so as to ensure negative margins. Although it is not always possible because of lacking a complete capsule. Tumours that have a high risk of malignancy can be treated using adjuvant radiotherapy, which usually results in a good outcome [8]. Thacker et al reported a case of a malignant GrCT in which the patient received adjuvant radiotherapy after surgery and was disease-free for 17 months [17]. In contrast, Arai et al reported a case of mortality due to lung metastasis despite adjuvant radiotherapy and chemotherapy after surgical resection [8]; the patient presented with lymph node metastasis [8]. Khansur *et al.*, reported a series of 40 cases of GrCTs – 37 were benign and three were malignant tumours; the rate of malignant GrCTs was reported to be 7.5%, which is considered high compared to other malignancies [18].

As there are no proper guidelines on the management of these tumours, we are of the opinion that it is best to carry out wide local resection rather than a marginal resection or observation.

Local recurrence and metastasis are relatively common in MGCT, with 32 % rate of recurrence and 50 % metastasis in the Fanburg-Smith analysis [6]. Distant and lymph node metastases are common, presenting

between 3 and 37 months after initial diagnosis, and distal metastases often occur in the lung, liver and bone [6, 15, 19, 20]. Thus, a sentinel lymph node biopsy during the initial surgical resection should be necessary.

## CONCLUSION

Although benign GrCTs have excellent outcomes after wide local excision, malignant GrCTs have poor clinical outcomes and prognoses. Malignant GrCTs can be differentiated from benign GrCTs via thorough examination of the patient during clinical presentation and histological examination of the excised specimen using the Fanburg-Smith criteria. We believe that wide local excision is the best treatment, irrespective of whether the lesion is benign or malignant. The role of adjuvant chemotherapy and radiotherapy is uncertain, but should be considered in patients with recurrent malignant GrCTs or metastatic disease. All patients should be followed up for recurrence and distant metastasis regardless of the initial nature of the disease.

## REFERENCES

- Rose, B., Tamvakopoulos, G. S., Yeung, E., Pollock, R., Skinner, J., Briggs, T., & Cannon, S. (2010). Granular cell tumours: a rare entity in the musculoskeletal system. *Sarcoma*, 2009.
- Abrikossoff AL. Uber Myome auesgehend von der querqestreiften wilkurlichen muskulatur. *Virchows Arch A Pathol*, 1926;260:215-233.
- Enzinger FM, Weiss SW (eds). Benign tumors of peripheral nerves, in *Soft Tissue Tumors*. St. Louis, MO, Mosby-Year Book, 1995, 864-875
- Strong EW, McDivitt RW, Brasfield RD. Granular ceil myoblastoma. *Cancer*, 1970;25:415-422.
- Elkousy H, Harrelson J, Dodd L, Martinez S, Scully S. Granular cell tumors of the extremities. *Clin Orthop Relat Res*, 2000; (380):191-8.
- Fanburg-Smith JC, Meis-Kindblom JM, Fante R, Kindblom LG. Malignant granular cell tumor of

- soft tissue: diagnostic criteria and clinicopathologic correlation. *Am J Surg Pathol*. 1998; 22:779-94.
7. Torrijos-Aguilar A, Alegre-de Miguel V, Pitarch-Bort G, Mercader-García P, Fortea-Baixauli JM. Cutaneous granular cell tumor: a clinical and pathologic analysis of 34 cases. *Actas Dermosifiliogr*, 2009;100:126-32.
  8. Arai E, Nishida Y, Tsukushi S, Sugiura H, Ishiguro N. Intramuscular granular cell tumor in the lower extremities. *Clin Orthop Relat Res*, 2010;468:1384-9.
  9. Fisher ER, Wechsler H. Granular cell myoblastoma—a misnomer. Electron microscopic and histochemical evidence concerning its Schwann cell derivation and nature (granular cell schwannoma). *Cancer*. 1962;15:936–54.
  10. Abenzoa P, Sibley RK. Granular cell myoma and schwannoma: fine structural and immunohistochemical study. *Ultrastruct Pathol*. 1987;11(1):19–28.
  11. Mazur MT, Shultz JJ, Myers JL. Granular cell tumor. Immunohistochemical analysis of 21 benign tumors and one malignant tumor. *Arch Pathol Lab Med*. 1990;114(7):692–6.
  12. Nakazato Y, Ishizeki J, Takahashi K, Yamaguchi H. Immunohistochemical localization of S-100 protein in granular cell myoblastoma. *Cancer*. 1982;49(8):1624–8.
  13. Simsir A, Osborne BM, Greenebaum E. Malignant granular cell tumor: a case report and review of the recent literature. *Hum Pathol*. 1996;27(8):853–8.
  14. Troncoso P, Ordonez NG, Raymond AK, Mackay B. Malignant granular cell tumor: immunocytochemical and ultrastructural observations. *Ultrastruct Pathol*. 1988;12(1):137–44.
  15. Tsuchida T, Okada K, Itoi E, Sato T, Sato K. Intramuscular malignant granular cell tumor. *Skeletal Radiol*. 1997;26(2):116–21.
  16. Rekhi B, Jambhekar NA. Morphologic spectrum, immunohistochemical analysis, and clinical features of a series of granular cell tumors of soft tissues: a study from a tertiary referral center. *Ann Diagn Pathol*, 2010;14:162-7.
  17. Thacker MM, Humble SD, Mounasamy V, Temple HT, Scully SP. Case report. Granular cell tumors of extremities: comparison of benign and malignant variants. *Clin Orthop Relat Res*, 2006; 455: 267-73.
  18. Khansur T, Balducci L, Tavassoli M. Granular cell tumor. Clinical spectrum of the benign and malignant entity. *Cancer*, 1987; 60: 220-2.
  19. Jardines L, Cheung L, LiVolsi V, Hendrickson S, Brooks JJ. Malignant granular cell tumors: report of a case and review of the literature. *Surgery*. 1994;116(1):49–54.
  20. Perez-Gonzalez YC, Pagura L, Llamas-Velasco M, Cortes-Lambea L, Kutzner H, Requena L. Primary cutaneous malignant granular cell tumor: an immunohistochemical study and review of the literature. *Am J Dermatopathol*. 2015;37(4):334–40.