

Cystic Ovarian Mature Teratoma with a « Floating Ball » Sign: about A Case Report

I Zouita*, H El Mortaji, Y Elbadri, D Basraoui, H Jalal

Département D'imagerie Médicale, Hôpital Mère et Enfant, CHU Med VI, Marrakech, Morocco

DOI: [10.36347/sjmcr.2020.v08i04.012](https://doi.org/10.36347/sjmcr.2020.v08i04.012)

| Received: 05.03.2020 | Accepted: 22.03.2020 | Published: 15.04.2020

*Corresponding author: I Zouita

Abstract

Case Report

Mature cystic teratoma is one of the most common human germ cell tumors and is often found in the ovary in women of reproductive age. Ovarian cystic teratomas are usually cystic fatty tumors that can be diagnosed easily using imaging techniques. We present a case of a 44-year-old woman diagnosed with cystic ovarian mature teratoma associated with the floating ball sign.

Keywords: Cystic ovarian teratoma, floating ball sign, mobile spherules, MRI, US, CT.

Copyright @ 2020: This is an open-access article distributed under the terms of the Creative Commons Attribution license which permits unrestricted use, distribution, and reproduction in any medium for non-commercial use (NonCommercial, or CC-BY-NC) provided the original author and source are credited.

INTRODUCTION

Mature cystic teratomas are the most commonly seen germ cell tumors of the ovary [1]. They account for at least 10% of all ovarian tumor [2]. They arise from two or three primitive embryonic germ cell layers, known as the endoderm, mesoderm, and ectoderm [3]. When the ectodermal component predominates, they are called dermoid cysts [2]. We present the case of an ovarian mature cystic teratoma with a floating ball sign that makes the particularity of this case.

CASE REPORT

We report the case of a 44 year old women, mother of six children, with regular periods, who presented to our department for abdominal distension evolving for six months. The clinical examination found a stable vitals with an abdomino-pelvic mass exceeding the umbilicus. The mass was firm, mobile and painless on palpation. The gynecological examination revealed a normal-looking cervix and found a right lateral uterine mass. The biological markers were normal except for an elevation of the CA 19-9 : 118 IU / ml.

The ultrasounds showed a large cystic mass with a thin and regular non vascularized wall with an heterogeneous content. Some mobile spherical structures of increased echogenicity were floating in the cystic mass (Figure-1).

MR imaging was performed and showed a complex cystic mass measuring 21 x 13 x 22 cm occupying the lower abdomen and pelvis, in hyposignal on T1 and hypersignal on T2 weighted images associated with thin septations and an enhanced vegetation measuring 8 x 6 mm. The mass contained also numerous small and non enhanced spherical structures floating in the cystic mass, in intermediate signal on T1 and T2 weighted images with a restricted diffusion.

It also found a second cystic mass with a calcified wall in the right para rectal region, measuring 4.7 x 3.6 x 6 cm, containing some floating non enhanced membranes in hypo signal on T1 and T2 weighted images. This second cystic mass was surrounded by an effusion. The normal right ovary could not be identified. The uterus and the left ovary were of normal appearance.

The CT scan performed for further characterization showed a peripheral calcifications within the cystic masses (Fig-3). Mature cystic teratoma was considered as a preoperative diagnosis.

Laparotomy revealed a large solid and cystic tumor of the right ovary associated with a right para rectal mass. The ovarian tumor contained numerous tissues. The diagnosis at pathology was mature cystic teratoma of the right ovary associated with a dermoid cyst of the right para rectal region.

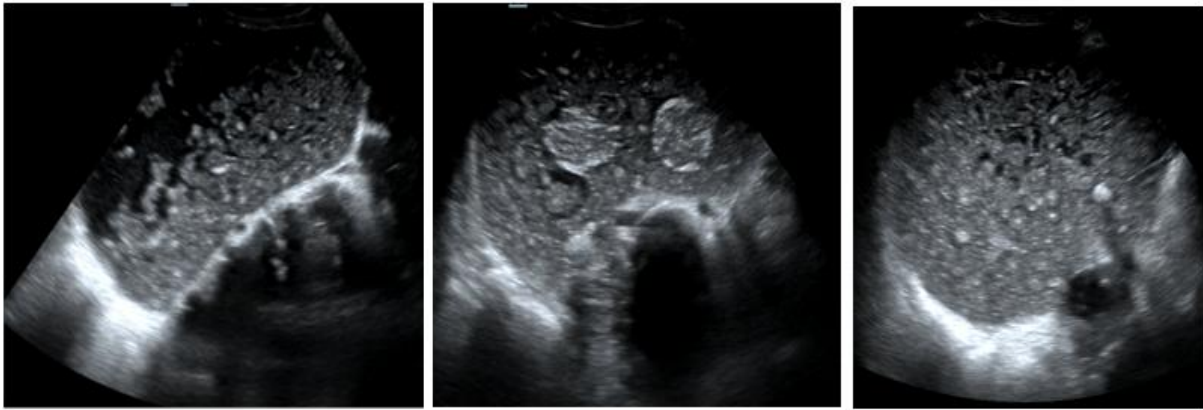


Fig-1: Sonogram shows a cystic mass containing multiple floating spherical hyperechoic globules, variable diameter, with some hyperechoic dots

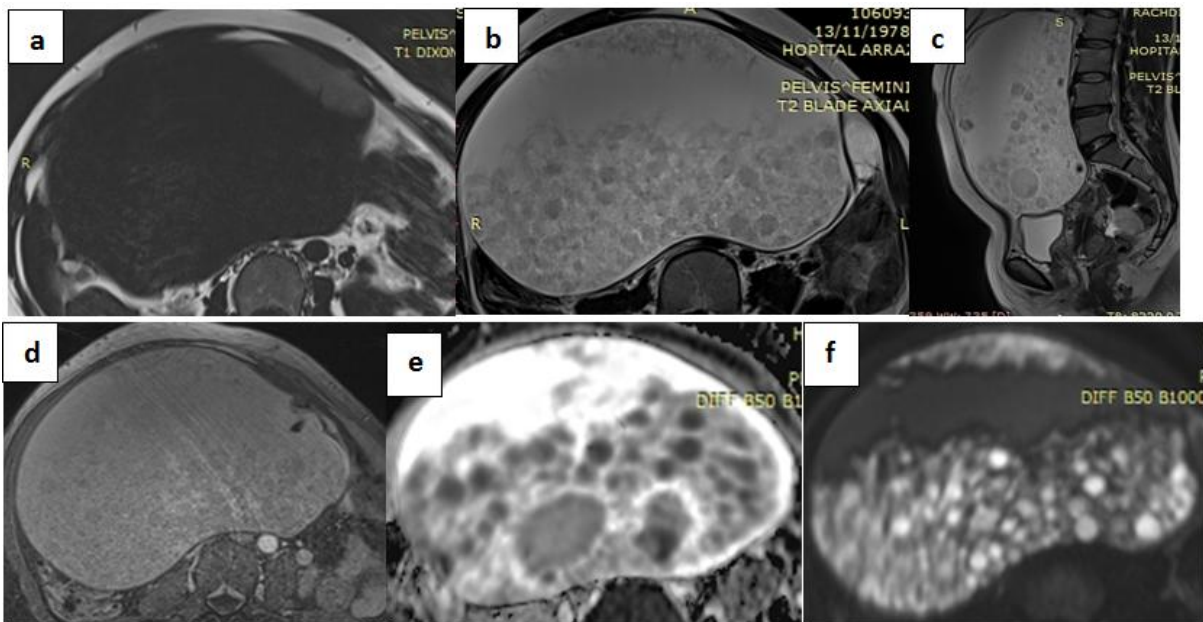


Fig-2: Axial T1 (a) T2 (b) sag T2 (c) axial T1 postcontrast(d) and axial diffusion(e) and ADC map (f) weighted magnetic resonance imaging. Reveals the heterogeneous cystic mass containing the floating balls which shows an intermediate signal intensity in the T1- and T2-weighted sequences and diffusion restriction regarding the keratin content

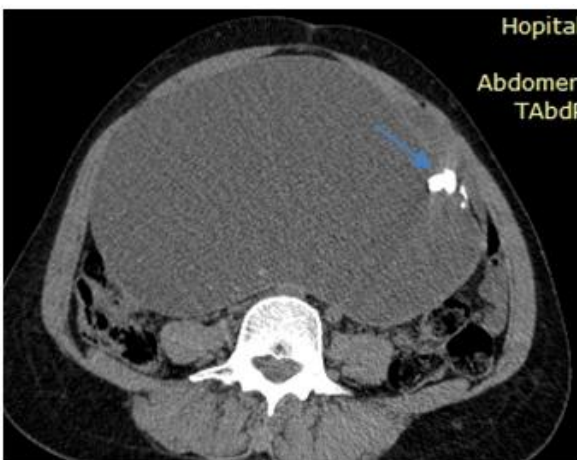

Fig-3: Axial ct scan shows the calcifications (arrow) within a cystic mass

DISCUSSION

The “floating ball” sign is an uncommon pathognomonic feature of ovarian mature teratoma which is defined by one or more small spherical structures floating in a cyst [4]. It may also be called the “meat ball” sign or the “truffle sign,” referring to numerous small floating globules as it was the case of our patient, or “pokeball” sign, referring to a single ball floating in a fat-fluid interphase [5, 6].

First described with radiologic imaging in 1991 by Muramatsu *et al.*, [7]; later, many case reports were written on the floating ball sign regarding its rarity. Recently, the study of Hilal Şahin and al. [8] over a 112 women with a pathologic diagnosis of ovarian mature cystic teratoma reviewed for the presence of the floating ball sign, showed that, with a 25% incidence rate, this sign is uncommon yet not rare, contrary to popular belief.

Floating balls are spherules with variable proportions of keratin, fibrin, hemosiderin, sebaceous material, hair, and fat [4]. According to the contents, these floating spherules take a gravity-dependent or gravity-independent position in the cyst.

Although the mechanism of their formation is still unknown, it is speculated that spherules are made by the aggregation of sebaceous material around a nidus made up of debris, squames or hair shafts, while moving in the cystic cavity [4, 9]. Then, they are given a spherical form because of the difference in physical and thermal properties of the material being deposited [10].

In imagery, cystic teratoma can be diagnosed using ultrasounds, CT or MRI. Some specific features are important for diagnosis, like a cyst with intracystic mural nodule (dermoid plug), fat fluid level, « dermoid mesh sign » which is due to floating hair fibers gives appearance of multiple linear echogenic interface. Another specific feature is distal acoustic shadowing due to mixture of echogenic matted hair and sebum (iceberg sign) [11]. Our case did not show any of these classical signs. Instead, the floating ball sign has helped us to diagnosis of a cystic ovarian teratoma on ultrasounds and MRI and the calcifications found on the complementary CT scan allowed us to obtain more elements to enable the correct diagnosis.

Floating ball sign can easily be recognized by imaging techniques. The spherules are approximately 1 to 3 cm in diameter and maybe more than 100 [12]. In ultrasounds, they appear as hyperechoic small vesicles floating above a cystic mass. In CT images they appear as hypodense structures. And in MRI, in T1-weighted images, the outer portion of the spherical structures is slightly hyperintense to the surrounding fluid, but not as hyperintense as the subcutaneous fat. The center of the spherical structures is relatively hypointense compared with the outer portion. In T2-weighted images the outer portion of the spherical structures is hypointense and the center relatively hyperintense [13].

Beside of its high specificity to diagnosis ovarian teratomas, the floating ball sign was the subject of a statistical analysis in Şahin's cohort [8] to find whether there is a relationship between this sign and tumor morphologic features. Some interesting outcomes came

out from this study and floating ball sign seemed to develop in larger cysts. This correlates with evidence that enough space is essential for floating balls to form their globular shape [4, 14].

The floating ball sign was also significantly related to tumor wall thickness and given that these balls are made up of keratin and sebaceous material, a thick tumor wall containing skin derivatives such as sebaceous glands may provide these materials in sufficient amounts [8].

If this sign had been seen until now only in benign ovarian teratomas, in Şahin's cohort two cases of squamous cell carcinoma presented with this sign. Therefore, the radiologist should be careful while looking for malignancy signs.

CONCLUSION

The floating ball sign is an uncommon and pathognomonic sign for cystic teratomas. It can easily be seen in every imaging modality and in the absence of the classical signs specific to ovarian teratomas, its presence could help the radiologist to redress the diagnosis. According to a recent literature review, we noted that this sign can be seen in both benign and malignant cystic teratomas. Therefore, each teratoma lesion including floating balls should be carefully evaluated for signs of malignancy.

REFERENCES

1. Outwater EK, Siegelman ES, Hunt JL. Ovarian teratomas: tumor types and imaging characteristics. *Radiographics*. 2001 Mar;21(2):475-90.
2. Chen VW, Ruiz B, Killeen JL, Côté TR, Wu XC, Correa CN, Howe HL. Pathology and classification of ovarian tumors. *Cancer: Interdisciplinary International Journal of the American Cancer Society*. 2003 May 15;97(S10):2631-42.
3. Choudhary S, Fasih N, Innes MM, Marginean C. Imaging of ovarian teratomas: appearances and complications. *Journal of medical imaging and radiation oncology*. 2009 Oct;53(5):480-8.
4. Tongsong T, Wanapirak C, Khunamornpong S, Sukpan K. Numerous intracystic floating balls as a sonographic feature of benign cystic teratoma: report of 5 cases. *Journal of ultrasound in medicine*. 2006 Dec;25(12):1587-91.
5. Mahomedy S, Bayat MR, Seedat M. Meat balls: a pathognomonic ultrasound and computed tomography finding in mature cystic teratoma. *Australasian radiology*. 2007 Dec;51:B281-3.
6. Otigbah C, Thompson MO, Lowe DG, Setchell M. Mobile globules in benign cystic teratoma of the ovary. *BJOG: An International Journal of Obstetrics & Gynaecology*. 2000 Jan;107(1):135-8.

7. Muramatsu Y, Moriyama N, Takayasu K, Nawano S, Yamada T. CT and MR imaging of cystic ovarian teratoma with intracystic fat balls. *Journal of computer assisted tomography*. 1991;15(3):528-9.
8. Şahin H, Akdoğan AI, Ayaz D, Karadeniz T, Sancı M. Utility of the “floating ball sign” in diagnosis of ovarian cystic teratoma. *Turkish journal of obstetrics and gynecology*. 2019 Jun;16(2):118.
9. Rao JR, Shah Z, Patwardhan V, Hanchate V, Thakkar H, Garg A. Ovarian cystic teratoma: determined phenotypic response of keratocytes and uncommon intracystic floating balls appearance on sonography and computed tomography. *Journal of ultrasound in medicine*. 2002 Jun;21(6):687-91.
10. Saba L, Guerriero S, Sulcis R, Virgilio B, Melis G, Mallarini G. Mature and immature ovarian teratomas: CT, US and MR imaging characteristics. *European journal of radiology*. 2009 Dec 1;72(3):454-63.
11. Mathew AA, Rohini A. Floating ball sign: a rare but specific sign of mature cystic teratoma. *International Journal of Scientific Research*. 2019 Apr 4;8(04).
12. Tongsong T, Wanapirak C, Khunamornpong S, Sukpan K. Numerous intracystic floating balls as a sonographic feature of benign cystic teratoma: report of 5 cases. *Journal of ultrasound in medicine*. 2006 Dec;25(12):1587-91.
13. Saba L, Guerriero S, Sulcis R, Virgilio B, Melis G, Mallarini G. Mature and immature ovarian teratomas: CT, US and MR imaging characteristics. *European journal of radiology*. 2009 Dec 1;72(3):454-63.
14. Jantarsaengaram S, Siricharoenchai S, Vairojanavong K. Cystic ovarian teratoma with intracystic fat balls. *Ultrasound in Obstetrics and Gynecology: The Official Journal of the International Society of Ultrasound in Obstetrics and Gynecology*. 2003 Jul;22(1):102-3.