

Maroteaux- Lamy Syndrome: A Rare Case of Mucopolysaccharidosis Type- VI with Bilateral Cloudy Cornea

Rajender Singh Chauhan, Apoorva Goel*, Ashok Rathi

Regional Institute of Ophthalmology, PGIMS, Rohtak, Haryana, India

DOI: [10.36347/sjmcr.2020.v08i04.013](https://doi.org/10.36347/sjmcr.2020.v08i04.013)

| Received: 07.04.2020 | Accepted: 14.04.2020 | Published: 17.04.2020

*Corresponding author: Apoorva Goel

Abstract

Case Report

Mucopolysaccharidosis are a group of rare inherited lysosomal storage disorder. The incidence of MPS type VI (Maroteaux- Lamy syndrome) is 0.36 to 1.30 per 100,000. It has autosomal recessive inheritance and is caused due to mutation in ARSB gene located on chromosome 5. This mutation causes absent or reduced production of N- acetyl-galactosamine 6 sulfatase enzyme (Arylsulfatase B). There is a progressive multisystem involvement with ocular involvement in the form of cloudy cornea, thickened sclera, glaucoma, optic atrophy and retinopathy. However, cloudy cornea remains the main culprit for reduced vision which is managed by corneal transplantation. Here we report a case of maroteaux- Lamy syndrome in which penetrating keratoplasty of one eye was done but was deferred in the other eye due to poor outcome in the operated eye in the presence of optic atrophy.

Keywords: Maroteaux- Lamy syndrome, corneal cloudiness, penetrating keratoplasty, optic atrophy.

Copyright @ 2020: This is an open-access article distributed under the terms of the Creative Commons Attribution license which permits unrestricted use, distribution, and reproduction in any medium for non-commercial use (NonCommercial, or CC-BY-NC) provided the original author and source are credited.

INTRODUCTION

Mucopolysaccharidoses (MPS) are a group of disorders which are caused by inherited defects in lysosomal enzymes and result in abnormal intra and extracellular accumulation of glycosaminoglycans [1]. MPS type VI or Maroteaux-Lamy syndrome, is a very rare disorder with an incidence ranging from 0.36 to 1.30 per 100,000 [2]. It is an autosomal recessive disorder caused by the deficiency of enzyme N-acetylgalactosamine 4-sulfatase (arylsulfatase -B) which is involved in the degradation of the glycosaminoglycans dermatan sulfate and chondroitin 4-sulfate. Deficient levels of this enzyme lead to the accumulation of partially degraded glycosaminoglycans in tissues and organs, which leads to a wide spectrum of systemic manifestations including airway and respiratory compromise, skeletal abnormalities (Fig 1, 4, 5), characteristic facies (Fig-2), with enlarged tongue, flat nasal bridge, and macrocephaly, neurological impairment, sleep apnea, cardiovascular abnormalities and gastrointestinal impairment. All these problems worsen progressively with age [1]. Ocular manifestations are also common resulting in gross visual impairment and the most common manifestations are: corneal clouding (Fig-3), and ocular hypertension. Other ocular manifestations include thickening of sclera, glaucoma, cataract, optic disc changes and retinopathy. Hence, the ophthalmologists play an

important role in the multidisciplinary management of these patients who have these additional visual problems apart from physical and intellectual disabilities [3].

Corneal clouding occurs due to the buildup of GAGs in the cornea which is the prime cause of low vision in these patients and also interferes in ophthalmological examination. The best treatment for corneal opacification is a full thickness corneal transplant. While PK is the most preferred surgery for corneal cloudiness, DALK may also be considered in some cases as endothelial function in the MPS may be preserved. Adverse outcomes have been observed after PK due to graft rejection or the associated ocular abnormalities of optic atrophy, retinopathy and glaucoma [4].

CASE REPORT

A 17 years old girl presented to Regional Institute of Ophthalmology, PGIMS, Rohtak with progressive cloudy cornea bilaterally, short stature, abnormal head shape, short neck, coarse facial features, hirsutism, fixed flexed deformity of knees and elbows, claw hands and curved feet since birth. On ocular examination her best corrected visual acuity was 1/60 in both eyes. Anterior segment examination revealed bilateral stromal cloudiness with alternate divergent

squint of 15 degrees. Rest details could not be visualized due to cloudy cornea. Posterior segment could not be assessed. IOP was normal. Pachymetry revealed mild thickening of cornea.

Patient was suspected to have Maroteaux-Lamy syndrome clinically. Orthopedic and paediatric consultation were done. Relevant confirmatory investigations were done which revealed the deficiency of enzyme responsible for mucopolysaccharidosis type-VI i.e. alpha-l-uronidase(1.07 nmol/hr/mg) and N-acetyl-galactosamine-4-sulfatase (arylsulfatase-B)(6.97 nmol/hr/mg). Penetrating Keratoplasty of right eye was done (Fig 6 & 7). However, Post-operatively vision was not improved due to optic atrophy (Fig-8).

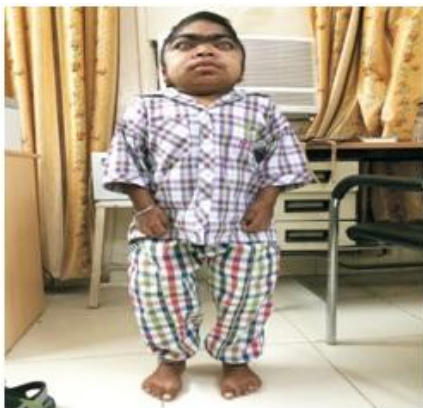

Fig-1

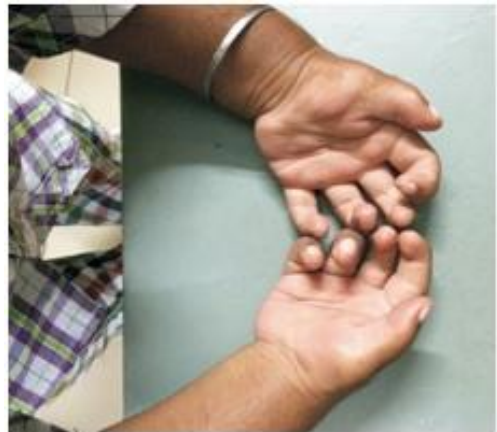

Fig-4

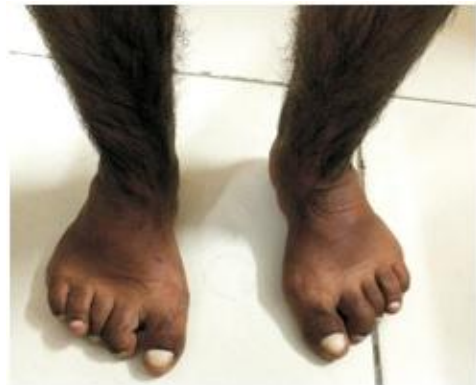

Fig-5

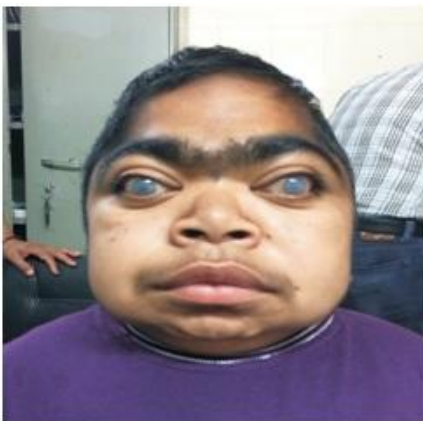

Fig-2

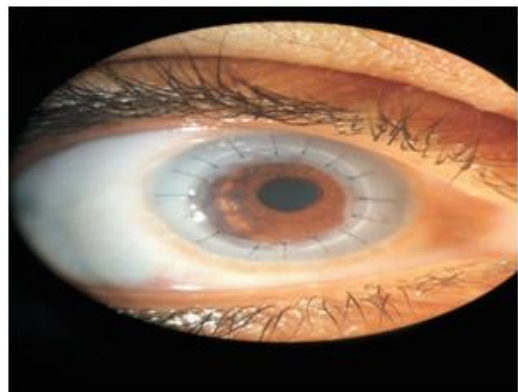


Fig-6

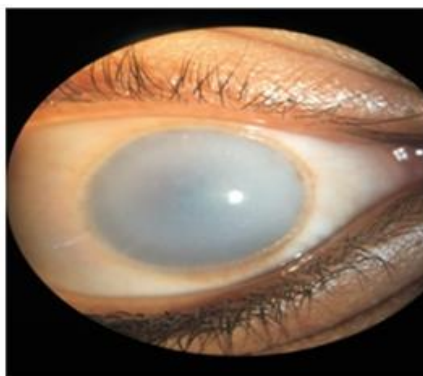

Fig-3



Fig-7

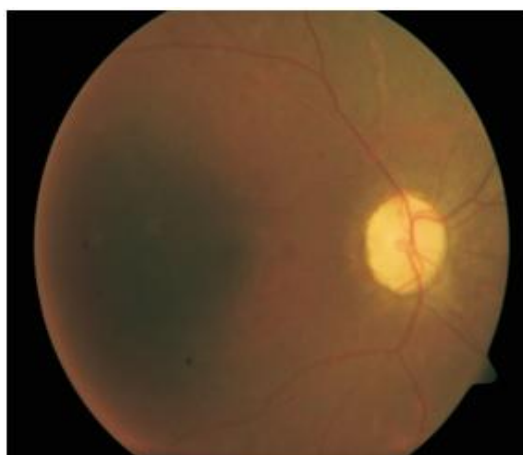

Fig-8

CONCLUSION

The most frequently described ocular manifestations of MPS VI is corneal clouding. Poor vision is mainly attributed to this. The treatment of choice for cloudy cornea is penetrating keratoplasty. The status of optic nerve should be tested by VEP before surgery as these patients are prone to optic nerve damage which can be due to raised intraocular pressure due to deposition of GAG in trabecular cells, GAG accumulation in optic nerve ganglion cells, compression of optic nerve from thickened dura, bony narrowing along optic nerve tract and raised intracranial pressure. Genetic counselling and psychosocial support should be provided to the patient and their family. Such patients require a multidisciplinary approach, coordinated at a specialist center. Management of cardiac, orthopedic,

respiratory and dental abnormalities should also be undertaken. Treatment of choice these days for this disease is enzyme replacement therapy (ERT) with galsulfase. Prognosis is variable depending upon age of onset of disease, disease progression and age at which ERT is started.

Funding: No financial funding

Conflict of interest: No conflict of interest

Ethical approval: Not required

REFERENCES

1. Ashworth JL, Biswas S, Wraith E, Lloyd IC. Mucopolysaccharidoses and the eye. *Survey of Ophthalmology*. 2006;51(1):1–17.
2. Harmatz P. Mucopolysaccharidosis- VI pathophysiology diagnosis and treatment. *Frontiers in Bioscience*. 2017;22(3):385–406.
3. Fenzl C, Teramoto K, Moshirfar M. Ocular manifestations and management recommendations of lysosomal storage disorders I: mucopolysaccharidoses. *Clinical Ophthalmology*. 2015;9:1633–1644.
4. Ohden KL, Pitz S, Ashworth J, Magalhães A, Marinho DR, Lindahl P, Fahnehjelm KT, Summers CG. Outcomes of keratoplasty in the mucopolysaccharidoses: an international perspective. *British Journal of Ophthalmology*. 2017 Jul 1;101(7):909-12.