

## Phenytoin Induced Lymphoid Aggregates in Bone Marrow Biopsy: An Incidental Finding

Sant Prakash Kataria, Rajeev Sen, Padam Parmar\*, Gajender Singh, Sanjay Kumar, Ritika

Department of Pathology, Pt. B. D. S. Post Graduate Institute of Medical Sciences, Rohtak – 124001, Haryana, India

### \*Corresponding Author:

Name: Dr. Padam Parmar

Email: [drpadamparmar@gmail.com](mailto:drpadamparmar@gmail.com)

**Abstract:** Phenytoin is a highly effective anticonvulsant agent. The side effects of phenytoin continue to create significant morbidity. Patients receiving phenytoin may develop benign lymphoid hyperplasia, pseudolymphoma, pseudopseudolymphoma, or, rarely, malignant lymphoma. Obtaining a history of phenytoin use is crucial in the diagnosis of such patients.

**Keywords:** Phenytoin, side effect, pseudolymphoma.

### INTRODUCTION

Lymphadenopathy associated with the use of hydantoin derivatives such as phenytoin was first described in 1940 [1]. Phenytoin (diphenylhydantoin or Dilantin) is anticonvulsant agent used in the treatment of epilepsy. The side effects of phenytoin create significant morbidity [2]. Two most important drug reactions of phenytoin are anticonvulsant hypersensitivity syndrome and lymphadenopathy [1, 2]. Here we presented a case with phenytoin induced pseudolymphoma.

### CASE REPORT

A 24 years old female presented with complain of pallor, easy fatigability and history of fever on and off. She had seizure disorders and was on phenytoin (Diphenylhydantoin) therapy for the last 18 months. There was no history of weight loss or night sweats. Physical examination revealed multiple cervical lymphadenopathy. There was no significant organomegaly.

Peripheral blood examination revealed - Haemoglobin 6.1g/dl, total leukocyte count  $<1500/\text{mm}^3$  with lymphocytosis and platelet count  $<20,000/\text{mm}^3$ . Biochemical test including liver and renal functions tests were in normal limits. Bone marrow aspirations (done twice) were done for evaluation of anaemia which were inconclusive due to low cellularity in smears. Radiological imaging investigations did not reveal organomegaly. Patient was seronegative for human immunodeficiency virus, hepatitis B surface antigen and hepatitis C virus.

Bone marrow trephine biopsy showed normocellular to hypercellular marrow with equal

myeloid and erythroid ratio revealing erythroid hyperplasia with normoblastic to megaloblastic erythropoiesis. Myelopoiesis and megakaryopoiesis were normal. There are two nodular aggregates comprising of lymphoid cells interspersed in between the trilineage hematopoietic cells. On immunohistochemical examination, these lymphoid cells were Tdt negative, CD3 and 5 positive, CD20 positive and CD23 negative. Possibility of Non-Hodgkin lymphoma could not be ruled out on the basis of bone marrow trephine biopsy.

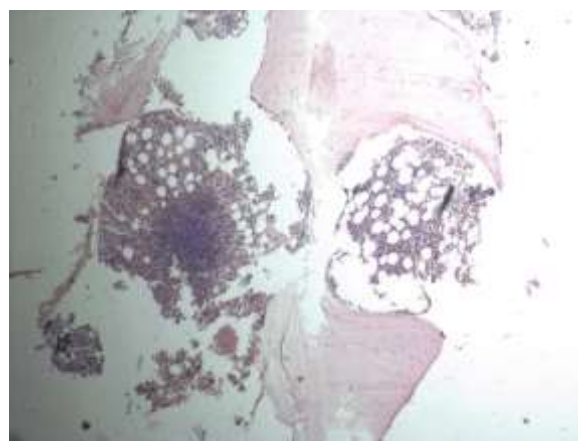
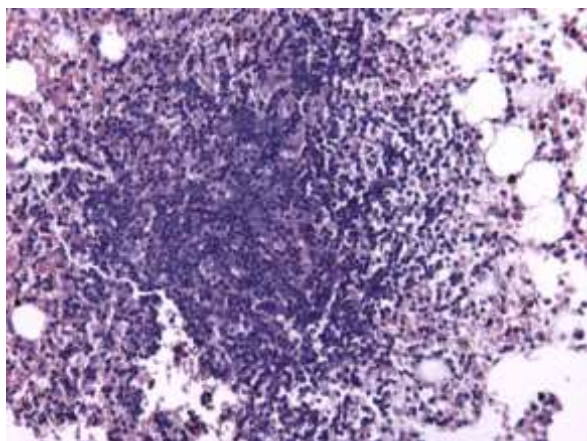
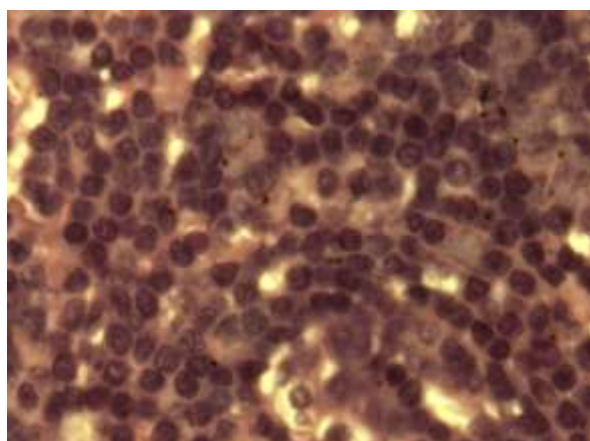


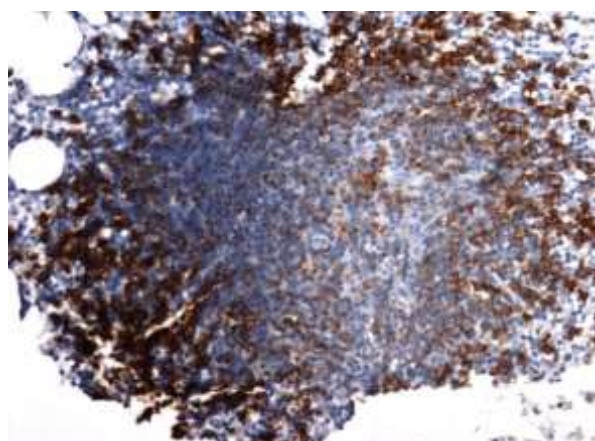
Fig 1: Bone marrow trephine biopsy showing nodular aggregates (H&E, 40x)



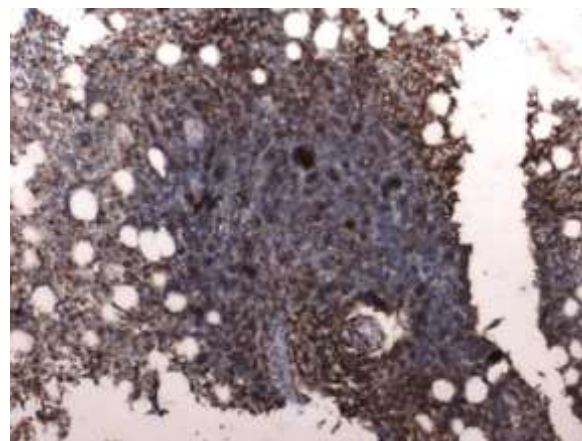
**Fig. 2:** Nodular aggregate composed of lymphoid cells (H&E, 100x)



**Fig. 3:** High power view of nodular aggregate (H&E, oil immersion)



**Fig. 4:** IHC showing CD20 positivity (IHC, 200x)



**Fig. 5:** IHC showing CD5 positivity in few cells (IHC, 100x)

## DISCUSSION

Phenytoin (diphenylhydantoin or Dilantin) is a highly effective anticonvulsant agent used for the treatment of grand mal and psychomotor epilepsy. Phenytoin has been used to treat ulcers, epidermolysis bullosa, and inflammatory conditions of skin due to its ability to inhibit collagenase [2]. Patients with epidermolysis bullosa treated with phenytoin also had lower levels of inflammatory mediators such as arachidonic acid [3]. Phenytoin may promote wound healing through multiple mechanisms, including stimulation of fibroblast proliferation, facilitation of collagen deposition, glucocorticoid antagonism, and antibacterial activity [4].

Phenytoin suppresses cytotoxic activities of immune cells such as natural killer (NK) cells and cytotoxic T lymphocytes (CTL), but not lymphokine activated killer (LAK) cells [2]. Treatment with phenytoin preferentially induces a Th2type response [5]. Specifically, it induces the liver cytochrome P450 enzyme system and stimulates steroid clearance [6]. These effects may partially explain the side effects of phenytoin [2].

Significant morbidity is caused by the side effects of phenytoin. Common side effects include gingival hyperplasia, coarsening of the facies, and hirsutism. Other rarer cutaneous side effects include drug induced lupus, purple hand syndrome, pigmentary alterations, IgA bullous dermatosis and generalized cutaneous eruptions. Prenatal exposure may result in a spectrum of structural, developmental, and behavioral changes known as the fetal hydantoin syndrome [2].

Patients receiving phenytoin may develop benign lymphoid hyperplasia, pseudolymphoma, pseudopseudolymphoma, or, rarely, malignant lymphoma [2]. Lymphoid hyperplasia can be localized in the cervical area. Pseudolymphoma has manifested with generalized nodular lesions.

Obtaining a history of phenytoin use is crucial in the diagnosis of such patients. Fever, hepatitis, and eosinophilia are generally absent, which are present in hypersensitivity syndrome [1].

When a rash is present and a biopsy is obtained, the histological appearance may mimic that of a cutaneous T-cell lymphoma [1]. Southern blots, gene rearrangement studies and chromosome studies are important tools in differentiating pseudolymphoma from malignant lymphoma in patients receiving chronic therapy [7].

Phenytoin induced pseudolymphoma can have mycosis fungoides manifestations [8]. The absence of a clonal population of T-cells in the lymph node aided in the diagnosis of phenytoin-induced pseudolymphoma, and it has been suggested that this is the method of choice to distinguish between pseudolymphoma and a T-cell lymphoma [1].

The anticonvulsant hypersensitivity syndrome is a rare syndrome characterized by fever, rash, lymphadenopathy, eosinophilia, and hepatitis; generally develops within eight weeks after the drug is first prescribed. The lymphoid reaction pattern most commonly seen in this syndrome is a benign lymphoid follicular hyperplasia. Patients generally do well with discontinuation of the anticonvulsant, though corticosteroids have been used in more severe cases [1].

The mechanism that underlies the development of lymphadenopathy in patients with phenytoin treatment is unclear; abnormal detoxification of reactive metabolites of phenytoin, possibly arene oxide metabolites produced by cytochrome P450, is responsible for the syndrome. It remains unknown that whether pathophysiology of phenytoin-induced pseudolymphoma is similar or not [1].

## CONCLUSION

In summary, our case report describes the presentation of the pseudolymphoma of phenytoin-induced and adds to the available body of literature describing this entity.

This type of case could be easily mistaken for a primary bone marrow lymphoma. Careful reviews of a patient's clinical and pathologic data are mandatory before initiating cytotoxic chemotherapy [1].

## Acknowledgement

I am pleased to acknowledge Dr. Tajender Singh for his valuable advise and help during my study.

## REFERENCES

1. Johns ME, Moscinski LC, Sokol L. Phenytoin - associated lymphadenopathy mimicking a

- peripheral T-cell lymphoma. *Mediterr J Hematol Infect Dis* 2010;2:e2010028.
2. Scheinfeld N; Phenytoin in cutaneous medicine: Its uses and side effects. *Dermatol Online J* 2003; 9(3): 6.
3. Fischer JE; The pathophysiology of enterocutaneous fistulas. *World J Surg.* 7, 446-450.1983.
4. Anstead GM, Hart LM, Sunahara JF, Liter ME; Phenytoin in wound healing. *Ann Pharmacother.* 1996; 30(7-8): 768-775.
5. Okada K, Sugiura T, Kuroda E, Tsuji S, Yamashita U; Phenytoin promotes Th2 type immune response in mice. *Clin Exp Immunol.*, 2001; 124(3): 406-413.
6. Putignano P, Kaltsas GA, Satta MA, Grossman AB; The effects of anti-convulsant drugs on adrenal function. *Horm Metab Res.*, 1998; 30(6-7): 389-397.
7. Jeng YM1, Tien HF, Su IJ; Phenytoin-induced pseudolymphoma: reevaluation using modern molecular biology techniques. *Epilepsia*, 1996; 37(1): 104-107.
8. Cooke LE, Hardin TC, Hendrickson DJ; Phenytoin-induced pseudolymphoma with mycosis fungoides manifestations. *Clin Pharm.*, 1988; 7(2): 153-157.