

**Research Article**

**Prevalence of Bergmeister Papilla**

Shinji Makino

Department of Ophthalmology, Jichi Medical University, Shimotsuke, Tochigi, Japan

**\*Corresponding author**

Shinji Makino

Email: [makichan@jichi.ac.jp](mailto:makichan@jichi.ac.jp)

**Abstract:** The objective of the work was to evaluate the prevalence of Bergmeister papilla. We retrospectively analyzed fundus photographs of 7,856 patients (including 4,421 men and 3,435 women) who underwent health screenings at our hospital during a 1-year period. The overall prevalence of Bergmeister papilla was 0.802% (63/7,856). Of the 63 patients with Bergmeister papilla, 38 were men (38/4,421; 0.860%), and 25 were women (25/3,435; 0.728%). The Bergmeister papillae varied in form. Among the 63 patients, 51 had the papillae in one eye and 12 in both eyes. Among the patients who underwent health screenings, the prevalence of Bergmeister papilla was 0.802%. These results may aid in explaining clinically rare conditions.

**Keywords:** Bergmeister papilla, Prevalence, Health screening.

**INTRODUCTION**

Bergmeister papilla is an uncommon anomaly that is derived from avascular remnants of the embryonic hyaloid system and that is characterized by raised glial tissue in the optic disc surface [1-3]. The papillae are usually asymptomatic and are detected incidentally during routine fundus examinations. In this study, we report the prevalence of Bergmeister papilla.

**MATERIALS AND METHODS**

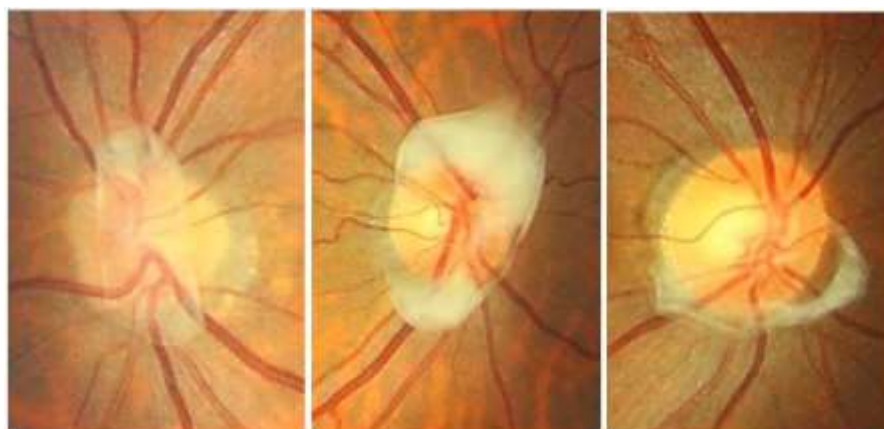
We conducted a retrospective survey of the patients who visited the Jichi Medical University hospital for health screenings from January 2014 through December 2014. Fundus photographs of 7,856 patients, including 4,421 men and 3,435 women,

obtained using a non-mydiatric fundus camera were examined.

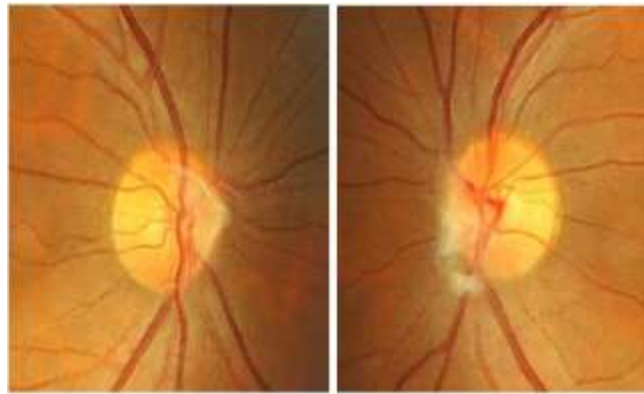
**RESULTS**

The overall prevalence of Bergmeister papilla was 0.802% (63/7,856). Of the 63 patients with Bergmeister papilla, 38 were men (38/4,421; 0.860%), and 25 were women (25/3,435; 0.728%). The Bergmeister papillae varied in appearance: they were cellophane-like, dense and membranous, and ring-shaped (Fig. 1 left, middle, and right, respectively).

Among the 63 patients, 51 had unilateral papillae and 12 had bilateral papillae (Fig. 2).



**Fig. 1: Various forms of Bergmeister papilla**



**Fig. 2: Bilateral Bergmeister papillae**

#### **DISCUSSION**

To the best of our knowledge, there are no reports on the prevalence of Bergmeister papilla in patients who underwent health screenings. In the present study, the overall prevalence of Bergmeister papilla was 0.802%.

In 1940, Lloyd [1] described various types of Bergmeister papillae, including a delicate mass that clung to the vessel trunks like a spider web, a thick mass of opaque tissue that was closely connected with the large vessel stalks covering the entire disc, and a round mass that was partly covering the disc. In the present study, the appearances of the papillae were similar to those in Lloyd's report [1], including a spider web (Fig. 2, right), a thick mass covering the entire disc (Fig. 1, middle), and a round mass partly covering the disc (Fig. 1, right).

#### **CONCLUSION**

These results may aid in explaining clinically rare conditions.

#### **REFERENCES**

1. Lloyd RI; Variations in the development and regression of Bergmeister's papilla and the hyaloid artery. *Trans Am Ophthalmol Soc.*, 1940; 38: 326-332.
2. Petersen HP; Persistence of the Bergmeister papilla with glial overgrowth. Various diagnostic problems. *Acta Ophthalmol (Copenh)*, 1968; 46(3): 430-440.
3. Hamming NA, Apple DJ, Gieser DK, Vygantas CM; Ultrastructure of the hyaloid vasculature in primates. *Invest Ophthalmol Vis Sci.*, 1977; 16(5): 408-415.