

Research Article

Radiographic Comparison between Platform-Shifted and Non-platform-Shifted Implant

Yousuf Aseel KP*, SripathiRao BH, Hassan Sarfaraz, Joyce Sequiera, Gunachandra Rai, Jagadish Chandra
Department of Oral & Maxillofacial Surgery, Yenepoya Dental College and Hospital, Deralakatte, Mangalore- 575018, Karnataka, India

***Corresponding author**

Dr Yousuf Aseel K.P

Email: aseelkp969@gmail.com

Abstract: The present study was aimed to radiographically compare the crestal bone level adjacent to implant with non platform shift and the platform shift implant with rough surface crestal module at 3 months and 6 months post prosthetic loading. This study was carried out in 10 patients reported to the Department of Oral and Maxillofacial Surgery/ Department of Implantology, Yenepoya dental college, Deralakatte, who require replacement of missing teeth using implant supported prosthesis. Twenty two stage titanium implants [Ten Nobel Replace® platform shift Tapered implant and ten Nobel Replace Select™ Tapered implant] were placed bilaterally in mandibular posterior region and were radiographically evaluated for crestal bone. IOPA with grid using paralleling technique was taken on the day of placement, on the day of loading, 3 months after loading and 6 months after loading the implant. Bone loss was evaluated along the mesial and distal surfaces of the implant. The mean crestal bone loss around the perimeter of groups A (non-platform shift) and B (platform shift) at the time of loading was 1.28 mm and 1.16 mm respectively. The mean crestal bone loss around the perimeter of groups A and B implants at three months was 1.4 mm and 1.3 mm. The mean bone loss at six months was 1.61 mm and 1.83 at the mesial and distal aspects respectively in group A. In group B the mean bone loss at six months was 1.3 mm and 1.45 mm at the mesial and distal aspects respectively. The difference in the bone loss at six month is statistically significant with a p value of 0.018 and 0.004. Hence group B i.e the implants with platform switching shows considerably less bone loss than group A.

Keywords: Implant, Crestal bone loss, platform shift.

INTRODUCTION

Dental implants have been shown to be a promising alternative to the traditional prosthetic rehabilitation of the edentulous area. They have reported success rates of over 96% in the long run. Albetsson in the year 1986 proposed the criteria for evaluation of success of dental implants which includes immobility, absence of radiographic evidence of peri-implant radiolucency, crestal bone loss of upto 1.5mm in the first year of function, an ongoing bone loss of less than 0.2mm annually and an absence of signs and symptom of an infection [1].

Crestal bone loss around osseointegrated implants may not necessarily reduce its longevity but definitely has a negative impact on the esthetic outcome due to subsequent changes in gingival contour and loss of interdental papilla. Various studies have reasoned this crestal loss of bone to be caused due to transmission of local gingival inflammation into the crestal bone, mechanical overload and excessive micromovements at the implant abutment junction (IAJ) [2,3,4].

“Platform switching” as a concept was given by Lazzara and Porter [3] in 2006 and they refer to the use of a smaller-diameter abutment on a larger-diameter implant collar; this connection shifts the perimeter of the IAJ inward toward the central axis (ie, the middle) of the implant [5]. The inward movement of the IAJ in this manner also shifts the inflammatory cell infiltrate inward and away from the adjacent crestal bone, which limits the bone change that occurs around the coronal aspect. In different short term studies platform switching is found to enhance crestal bone preservation and alter the starting point from which the crestal bone loss occurs [3,5,9,11,12]. It is also said that the post-restorative biological process is which results in the loss of the crestal bone height is altered in platform switching [10].

An in-vivo study was undertaken with the aim to radiographically evaluate and compare the vertical crestal bone loss occurring along with the platform shift and non-platform shifted crest module design. This would substantiate the basis for selecting an implant

design which would reduce crestal bone loss and confirm the above mentioned observations. Hence, a better long term success rate can be assured.

MATERIALS AND METHOD

Source of data

This study was carried out in 10 patients reported to the Department of Oral and Maxillofacial Surgery/ Department of Implantology, Yenepoya Dental College, Deralakatte, who require replacement of missing teeth using implant supported prosthesis.

Materials

- Nobel Replace® platform shift Tapered implant [fig – 1]
- Nobel Replace Select™ Tapered implant [fig – 2]
- IOPA with Grid

Inclusion criteria

Patients having bilateral edentulous sites in the posterior mandible with healthy adjacent and opposing teeth, between 20 – 40 years who have no contraindications for minor surgical procedures or local factors which may hamper the implant placement.

Exclusion criteria

Edentulous sites with acute infection or patients with systemic or local factors which contraindicates the placement of implant. Patients who are unable to come for routine follow up were also excluded from the study.

Method

Each patient received one implant (Group A) with a non-platform shift (Nobel Replace Select) and another (Group B) with platform shift (Nobel Replace Platform shift). Both the groups of implants were two-stage, tapered, threaded implants. Radiographs revealed mesiodistal and apicocoronal dimensions of the available bone at the implant site as well as the trabecular pattern of the bone. Bone width gauge was used for the assessment of buccoligual thickness of bone.

The selected implants was placed in patients having bilateral missing teeth in the mandibular posterior region in seven female and three male. In this study, specifically mandibular molar sites was chosen to simulate the masticatory forces and angulation. Each type of the implant was placed in the patient according to the surgical protocol recommended by its manufacturer. Post-operatively, IOPA with grid were obtained with paralleling technique to standardize the post operative radiographs and to measure the first crestal bone to implant contact level from the top of the implant along the collar/body surface of each implant on the mesial, distal side. These measurements would become the baseline reference levels to measure future bone loss.

Second stage surgery was performed to relocate the implants after two months. The cover screw was replaced with healing abutment for gingival cuff formation after two weeks healing abutment was removed and impression coping was screwed on the implant. Implant level impression was taken using open tray method. Prosthodontic procedures were carried out for the fabrication of ceramic fused to metal crowns and the crowns were luted with a eugenol-free zinc oxide cement (Rely X Temp Bond NETM, 3M ESPE) on the abutments of each type of implant. Upon prosthodontic loading, the implants became functional in occlusion. Three months and six months after loading the implants, bone levels around each implant were measured with IOPA and bone loss was calculated by deducting the baseline reference bone levels. Crestal bone loss which occurs before implant loading and three and six months after implant loading has tabulated.

RESULTS

The present study was aimed to radiographically compare the crestal bone level adjacent to implant with the non-platform shift and the platform shift implant at 3 months and 6 months post prosthetic loading.

Ten Replace Select Tapered (Group A) dental implant and Ten Nobel Replace Platform Shift (Group B) dental implant were radiographically examined in 10 patients reported to the Department of Oral and Maxillofacial Surgery/ Department of Implantology, Yenepoya dental college, Deralakatte, who require replacement of missing teeth using implant supported prosthesis. The age ranged from 20 to 40 years.

The radiographic evaluation of the implants, the measurements and data taken from all the patients were tabulated for statistical study, Statistical analysis was carried out using 'Paired t-test' to compare the bone loss along Group-A and B types of implants (Table -1) depicts the mean values obtained for crestal bone loss at specified time intervals. Fig-3 and 4 are the graphical representation of comparison of the average crestal bone loss occurring around each type of implant at 3 and 6 after placing the implants. The average crestal bone loss around the perimeter of Group- A and B implants after 3 months was 1.4 mm and 1.3 mm, after 6 months was 1.7 mm and 1.35 mm respectively. After 6 months after loading the implants, there was statistically significant difference in crestal bone loss along Group- A and B implants, average bone loss being more along Group- A implants.



Fig-1: Nobel Replace® platform shift Tapered implant



Fig- 2: Nobel Replace Select™ Tapered implant

Table -1: Mean values obtained for crestal bone loss at specified time intervals.

	Group	N	Mean	Std. Dev.	t	df	p-value
Mesial at Loading diff.	PS	10	1.133333	0.383293	-0.716	18	0.483
	SELCT	10	1.25	0.344713			
Distal at Loading diff.	PS	10	1.208333	0.36694	-0.734	18	0.472
	SELCT	10	1.316667	0.28814			
Mesial 3 Month diff.	PS	10	1.266667	0.361752	-0.827	18	0.419
	SELCT	10	1.383333	0.26117			
Distal 3 Month diff	PS	10	1.4	0.316228	-0.688	18	0.5
	SELCT	10	1.5	0.333333			
Mesial 6 Month diff.	PS	10	1.3	0.322031	-2.61	18	0.018
	SELCT	10	1.616667	0.208611			
Distal 6 Month diff.	PS	10	1.45	0.324118	-3.286	18	0.004
	SELCT	10	1.833333	0.175682			

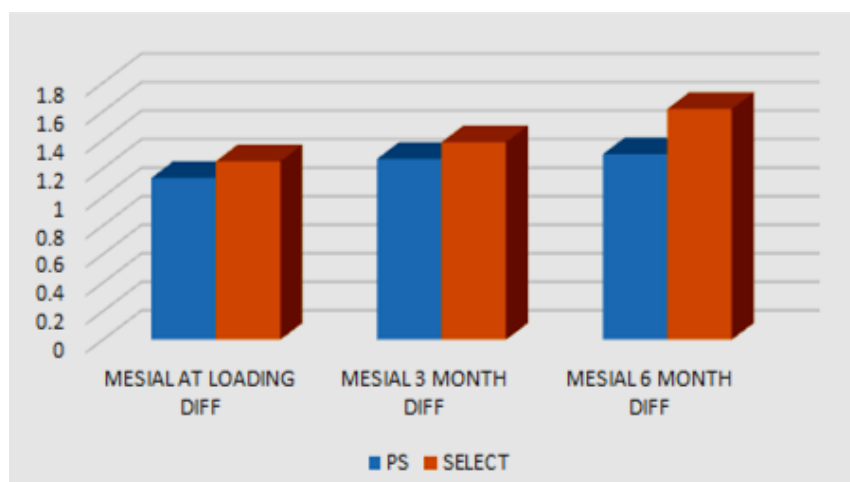


Fig-3: Difference in crestal bone level in group-a and group-b for different time intervals (mesial side)

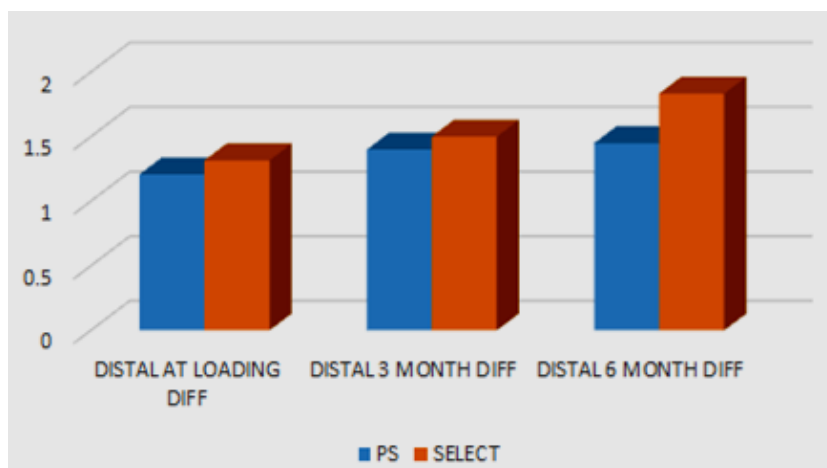


Fig-4: Difference in crestal bone level in group-a and group-b for different time intervals (disatal side)

DISCUSSION

This study aims to compare the crestal bone loss associated with non platform shift implant and platform shift implants. The crestal bone level was measured at the time of placement, at loading, at three months and six months after loading radiographically using a 1mm²grid. The bone level at the time of placement was taken as the reference level.

Twenty implants were placed in these patients as a split mouth study. A non platform implant (Nobel Replace Select Tapered, Nobel Biocare AB, Goteborg, Sweden) was placed in the edentulous area. On the contralateral side of the same patient a platform shift implant (Nobel Replace Platform Shift, Nobel Biocare AB, Goteborg, Sweden) was placed. The split mouth study design removed inter-subject variability [15].

The bone loss was measured from the reference bone levels at the time of the placement. The mean crestal bone loss for group A at loading was 1.25mm mesially and 1.31 mm distally. For group B the mean crestal bone loss at loading was 1.13 mm mesially and 1.20 distally. Three months after loading group A implants showed a mesial bone loss of 1.31mm and distal bone loss of 1.5mm. While group B implants showed a mesial bone loss of 1.2mm and a distal bone loss of 1.4mm after three months. These were measured from the reference level. The differences in bone loss at loading and at three months after loading were not statistically significant. Six months from the time of loading group A implants showed a bone loss of 1.61 mm mesially and 1.83mm distally. At the same interval of six months group B implants showed a bone loss 1.30mm mesially and 1.45mm distally. This difference in bone loss between the two groups were found to be statistically significant with a p value of 0.018 mesially and 0.004 distally.

Crestal bone loss is an important factor in the long term success of an implant [1,13]. The amount of bone loss during the first year of implant service affects the longevity of the implant [2]. Reduction of this bone

loss is associated with better soft tissue health and aesthetics as well [10,14]. Various designs and techniques have been innovated over the years to reduce the crestal bone loss.

The largest amount of bone loss occurred during the healing period when the implants were not functionally loaded. This has been observed in other studies as well [2,4,14]. The reformation of biologic width around dental implants, microgap if placed at or below the bone crest, occlusal overload and implant crest module are said to be the most likely causes of early implant bone loss. Surgical trauma and peri-implantitis may also play a role in this [2].

Lack of effective mechanical loading has added on to this bone loss during the healing period. Finite element analysis and histological studies have inferred that an equivalent stress of 1.6MPa has been deemed sufficient to avoid crestal bone loss from disuse atrophy in canine mandibular premolar region. Any design which creates a low stress region near the coronal implant zone could lead to disuse atrophy. Another finite element study has shown that presence of retentive elements like microthreads at an implant neck would dissipate some forces leading to the maintenance of crestal bone height as per Wolff's law which states that an increased stress tends to elicit the bone stimulation while reduced stress tends to elicit bone loss [23].

The difference in the bone loss between the two groups became significant only after six months from functional loading. Previous studies comparing smooth collared and rough collared implants have shown similar results [2,4,10]. Although the mean bone loss in these studies are 0.71mm for smooth collared and 0.49mm for rough collared implants^{2,4}. Whereas it is 1.72 mm for smooth collar and 1.37 mm for rough collar in this study. This difference can be attributed to different standardisation techniques and radiographic imaging followed in those studies. Specifically in one

study they used 3.5mm diameter implants in all the cases which can reduce the overall bone loss [4].

In this study rough collar crest module was combined with platform shift in group B. This group indeed showed a reduction in bone loss but how much of this reduction is contributed by the rough collar design and how much by the platform shift is quit hard to determine. Histological studies done in animal models showed that there was no significant difference in bone loss between platform switch abutments and regular ones [16,17].

In a systematic review and meta-analysis on platform switching of dental implants they found statistically significant reduction of peri-implant bone loss around platform switched implants in seven studies; whereas three studies failed to show any significant differences between the two groups [12].

CONCLUSION

In this study the crestal bone loss was compared in implants non platform shift and platform shift radiographically. Maximum bone loss is seen during the healing period before functional loading. There is no significant difference in the bone loss at the time of loading and after three months. Significant difference in the bone loss is seen at six months after functional loading. Further studies are required to validate the results and infer the clinical significance of the findings.

REFERENCES

1. Albrektsson T, Zarb GA, Worthington P, Eriksson AR; The long term efficacy of currently used implants: a review and proposed criteria for success. *Int J Oral and Maxillofacial implant*, 1986; 1(1): 11-25.
2. Goswami MM; Comparison of crestal bone loss along two implant crest module designs. *Medical Journal Armed Forces India*, 2009; 65(4): 319-322.
3. Porter SS; Platform switching: a new concept in implant dentistry for controlling postrestorative crestal bone levels. *Dent*, 2006; 26, 9-17.
4. Nickenig HJ, Wichmann M, Happe A, Zöller JE, Eitner S; A 5-year prospective radiographic evaluation of marginal bone levels adjacent to parallel-screw cylinder machined-neck implants and rough-surfaced microthreaded implants using digitized panoramic radiographs. *Journal of Cranio-Maxillofacial Surgery*, 2013; 41(7): 564-568.
5. Harold Baumgarten,, Roberto Cocchetto,. A New Implant Design For Crestal Bone Preservation :Initial Observations And Case Report . *Pract Proced Aesthet Dent*, 2005; 17(10): 735-740.
6. Lee SY, Piao CM, Koak JY, Kim SK, Kim YS, Ku Y, Rhyu IC, Han CH, Heo SJ; A 3-year prospective radiographic evaluation of marginal bone level around different implant systems. *Journal of oral rehabilitation*, 2010; 37(7): 538-544.
7. Norton MR; Marginal bone levels at single tooth implants with a conical fixture design. The influence of surface macro-and microstructure. *Clinical Oral Implants Research*, 1998; 9(2): 91-99.
8. Misch CE, Bidez MW; A scientific rationale for dental implant design. In Misch CE. ed. *Contemporary Implant Dentistry*. 2nded, St. Louis: Mosby, 1999; 329-343.
9. Maarten Glibert ,StijnVervaeke . Clinical and Radiographic Comparison between Platform-Shifted and Nonplatform-Shifted Implant: A One-Year Prospective Study, 2014 : 32: 323-328.
10. Luigi Canullo ,GiulioRasperini . Preservation Of Peri-implant Soft and Hard Tissues Using Platform Switching Of Implants Placed In Immediate Extraction Sockets : A Proof – of – Concept Study With 12 to 36 month follow - up
11. Fernández-Formoso N, Rilo B, Mora MJ, Martínez-Silva I, Díaz-Afonso AM; Radiographic evaluation of marginal bone maintenance around tissue level implant and bone level implant: a randomised controlled trial. A 1-year follow-up. *Journal of oral rehabilitation*, 2012; 39(11): 830-837.
12. Atieh MA, Ibrahim HM, Atieh AH; Platform switching for marginal bone preservation around dental implants: a systematic review and meta-analysis. *Journal of periodontology*, 2010; 81(10): 1350-1366.
13. Tomas Albrektsson, Daniel Buser; Crestal Bone Loss and Oral Implants . *Clinical Implant Dentistry and Related Research*, 2012; 14: 783-791.
14. AL-QUTUB MN; Radiologic evaluation of the marginal bone loss around dental implants with different neck diameters. *Pakistan Oral & Dental Journal*, 2011; 31(1).
15. Hujoel PP; Design and analysis issues in split mouth clinical trials. *Community Dent OralEpidemiol*. 1998; 26: 85-6.
16. Gamborena I, Lee J, Fiorini T, Wenzel BA, Schüpbach P, Wikesjö UM, Susin C; Effect of platform shift/switch and concave abutments on crestal bone levels and mucosal profile following flap and flapless implant surgery. *Clinical Implant Dentistry and Related Research*, 2014.
17. Brent A, Wenzel, InäkiGamborena; Effect of Platform Shift on Crestal Bone Levelsand Mucosal Profile Following Flap Surgery and Subcrestal Implant Placement in Presence/ Absence of Gap Defects, 2014 : 34-41.
18. Hermann JS, Buser D, Schenk RK, Schoolfield JD, Cochran DL; Biologic Width around one- and two-piece titanium implants. *Clin Oral Implants Res*, 2001; 12: 559-71.
19. Hänggi MP, Hänggi DC, Schoolfield JD, Meyer J, Cochran DL, Hermann JS; Crestal bone changes around titanium implants. Part I: A retrospective radiographic evaluation in humans comparing two

- non-submerged implant designs with different machined collar lengths. *J Periodontol*, 2005; 76: 791-802.
20. Lemons JE, Phillips RW; Biomaterials for dental implants. In: Misch CE, editor. *Contemporary Implant Dentistry*, St. Louis: Mosby, 1993.
 21. Baumeister T, Avallone EA, Baumeister T; Marks standard handbook of mechanical engineers, 8th Ed, New York: McGraw-Hill, 1978.
 22. Wiskott HW, Belser UC; Lack of integration of smooth titanium surfaces: A working hypothesis based on strains generated in the surrounding bone. *Clin Oral Implants Res* 1999; 10: 429-44.
 23. Hansson S; The implant neck: smooth or provided with retention elements. A biomechanical approach. *Clin Oral Implants Res*, 1999; 10: 394-405
 24. Shin SY, Han DH; Influence of a microgrooved collar design on soft and hard tissue healing of immediate implantation in fresh extraction sites in dogs. *Clin Oral Implants Res*, 2010; 21: 804-14.
 25. Park YS, Lee SP, Han CH, Kwon JH, Jung YC; The microtomographic evaluation of marginal bone resorption of immediately loaded scalloped design implant with various microthread configurations in canine mandible: Pilot study. *J Oral Implantol*, 2010; 36: 357-62.