

Case Report

Gorlin Gortz Syndrome: A Rare Case Report

Dr. Madhumati Singh^{*1}, Dr. Anjan kumar Shah², Dr. Amit Ashok Basannavar³, Dr. Sathesh kumar⁴,
Dr. Pramod kumar⁵

¹Professor and Head, Rajarajeswari Dental College and Hospital Bangalore-560060, Karnataka, India

²Professor, Rajarajeswari Dental College and Hospital, Bangalore-560060, Karnataka, India

^{3,4,5} Post graduate students, Rajarajeswari Dental College And Hospital, Bangalore-560060, Karnataka, India

*Corresponding author

Dr. Madhumati Singh

Email: amit2205@gmail.com

Abstract: Gorlin-Goltz syndrome which is also known as Bifid rib syndrome comprises of multiple organ system. One of the most common features includes the multiple odontogenic keratocysts in maxilla or mandible and basal cell nevus on the skin that usually shows an early age onset. Studies have showed that Gorlin syndrome is an autosomal dominant disorder which arises from chromosome defects. These multiple odontogenic keratocysts should be treated at the earliest for the related damage and possible complications associated. One thing that should be taken in consideration while explaining the prognosis to the patient is the recurrence of these lesions which is the most characteristic feature. A case report of a young female patient with Gorlin-Goltz syndrome is presented here.

Keywords: Gorlin Gortz syndrome, Odontogenic keratocyst, Bifid ribs.

INTRODUCTION

The GorlinGortz syndrome is a hereditary condition that is transmitted as an autosomal dominant trait with high (almost 100%) penetrance and varying expressivity. In 1960, Gorlin and Gortz studied the main features of this syndrome and stated that it affects multiple organ systems, including skeletal, skin, eye, reproductive, and neural system, however all the features are rarely seen in the same patient. Often the affected patient consults a dentist with the chief complaint of swelling in the jaw and following which the diagnosis of this syndrome is made with the help of routine investigations. Hence, a dental clinician should always be open to the chances of encountering multiple cystic lesions of the jaws. Here in we report a case with similar features.

CASE REPORT

A 10-year-old female patient reported to the Department of Oral and Maxillofacial Surgery with a chief complaint of intraoral firm painless mass on the upper anterior region. The duration of the swelling was 8 months and the growth was slow in nature. Her medical and past dental history was not significant. On examination, wide nasal bridge and mild prognathous was observed extra orally (FIGURE1). Intra orally the swelling was firm and tender on palpation, it extended from midline of the central incisors to distal aspect of canine (#23) region.

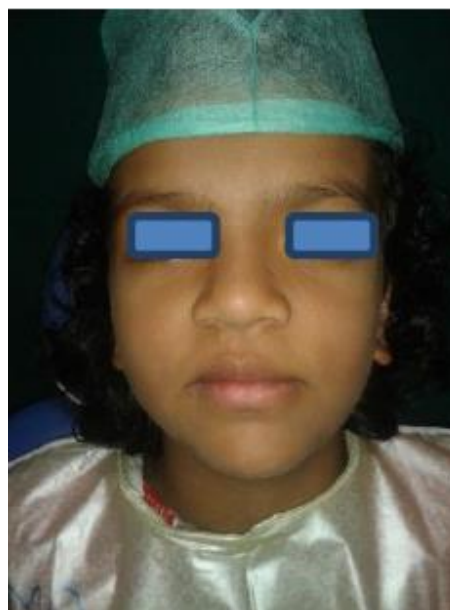

Fig-1: Facial profile

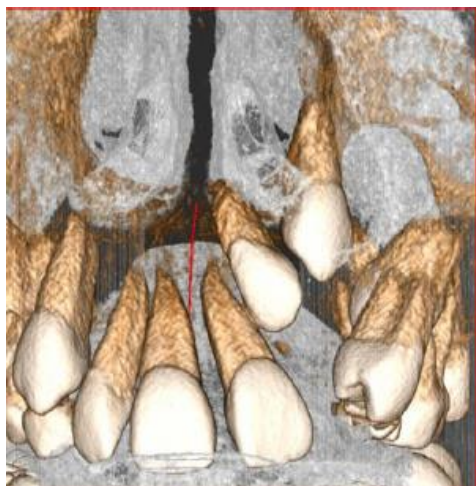

Fig-2: 3D CBCT view

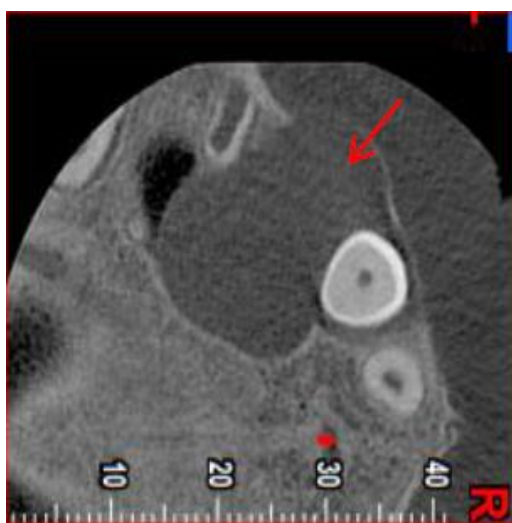


Fig-3: Axial section

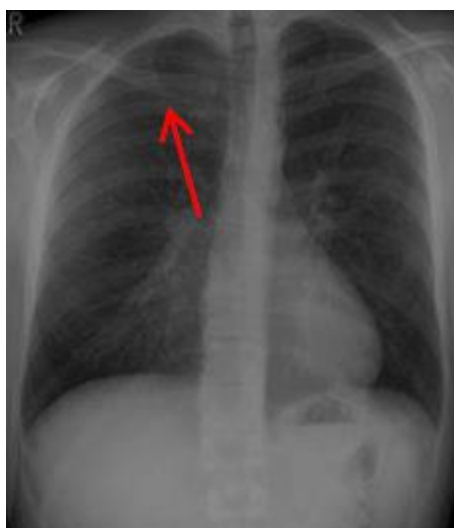

Fig-4: Chest radiograph

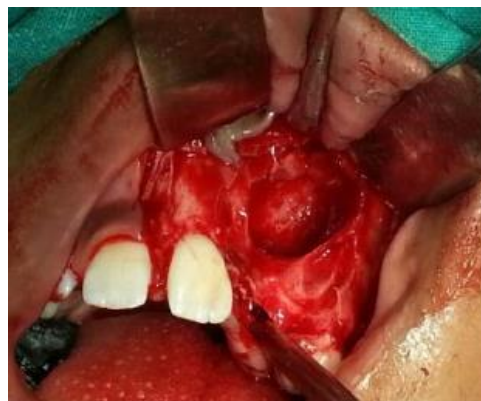

Fig-5: Enucleation

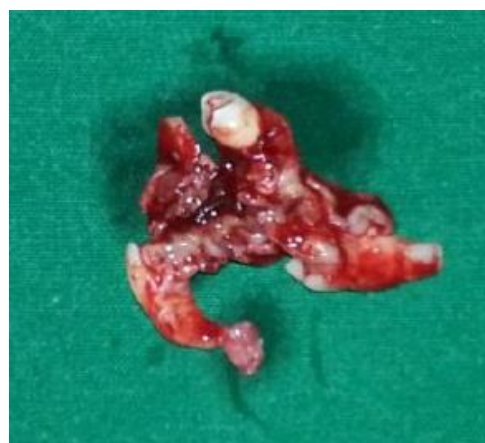

Fig-6: Enucleated cyst

The cone beam computed tomography showed cystic lesions in the upper left jaw associated with interrupted permanent teeth showing cortical expansion and radiolucent lesion on the left side (FIGURE 2,3). The chest radiograph showed second and third bifid ribs on the right side (FIGURE 4). Based on the clinical and radiological findings, a provisional diagnosis of Gorlin-Goltz syndrome was made. No skin lesions in the form of basal cell nevus, palmar or plantar pits or keratosis were present.

The parents and siblings of the patient were also examined clinically and radiographically; however, none of them showed any characteristics of this condition.

An incisional biopsy was done which was sent for histopathological evaluation. The histopathology report suggested, a para keratinised type of odontogenic keratocyst (FIGURE 7,8).

Complete surgical removal was the treatment of choice. The present case was treated with surgical enucleation and curettage of the cyst under general anesthesia (FIGURE 5,6).

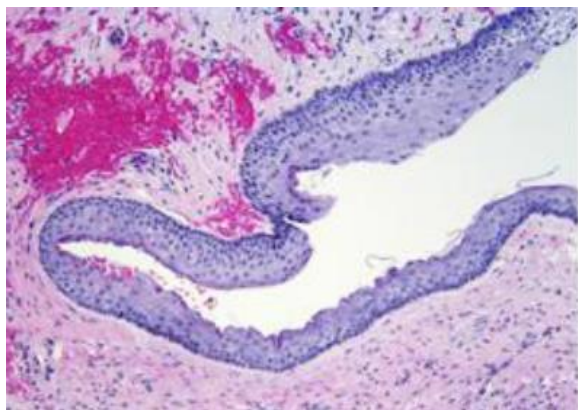


Fig-7: Histologic slide showing stratified squamous epithelium with areas of focal thickening.

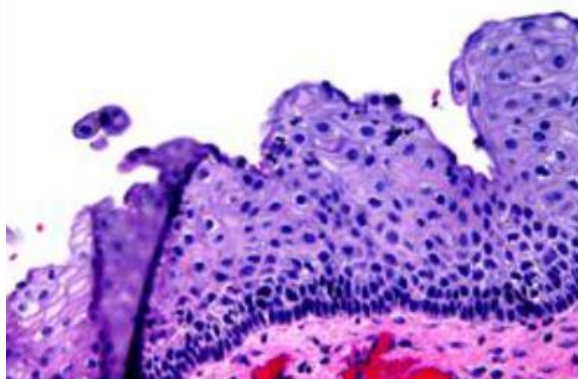


Fig-8: Higher magnification showing corrugated par keratin surface and palisaded basal cell layer.

DISCUSSION

As stated earlier, Gorlin syndrome is an autosomal dominant disorder which arises due to defects on chromosome. Some authors suggest that almost half of odontogenic keratocysts are associated with Gorlin syndrome. These lesions have the capacity to grow to large sizes, more than any other odontogenic cyst. They usually penetrate the bone rather than causing expansion of the bone and grow in an antero-posterior direction. Despite these features, specially the aggressive growth capability, they often remain asymptomatic.

Odontogenic keratosis (OKC) is a cyst originating from the tooth with an aggressive clinical behavior and with a high recurrence rate. It is known for its rapid growth, its tendency to invade the adjacent tissues including bone and is usually associated with the basal cell nevus syndrome[1].

Studies have reported that OKCs most often occur in the second and third decades of life and show a slight predilection for males (male to female ratio 1.3:1)[2]. The World Health Organization (WHO) in its recent (2005) classification of Head and Neck Tumors have reclassified the orthokeratinised type of odontogenic keratocyst as a benign neoplasm,

recommending the term “keratocystic odontogenic tumor” (KCOT)[3].

The management of these lesions ranges from simple enucleation or curettage to ostectomy with curettage of the adjacent bone. An adjunctive surgical procedure termed as "peripheral ostectomy" has been described, following enucleation or curettage, in which the osseous walls of the defect are abraded with coarse surgical burs so as to ensure that all residual peripheral neoplastic tissue is removed[4]. The advantage of a conservative surgical procedure is the preservation of the adjacent bone, soft tissue and dental structures. Reduced morbidity and a short term hospitalization generally follows this course of therapy. Some large, destructive cases need to undergo segmental resection of the involved jawbone with immediate or delayed reconstruction. All the cases require periodic clinical and radiological follow up to rule out any early signs of recurrence owing to its high rate of recurrence, with reports ranging from 20% to 60%[5].

REFERENCES

1. Neville BW; Oral and maxillofacial pathology. 3rd ed. St. Louis, MO: Elsevier/Saunders; 2009.
2. Broume RM; The odontogenic keratocyst - histological features and their correlation with clinical behavior. Br Dent J, 1971;131: 249-59.
3. Madras J, Lapointe H; Keratocystic odontogenic tumour: Reclassification of the odontogenic keratocyst from cyst to tumour. J Can Dent Assoc, 2008;74:165-165.
4. Zachariades N, Papanicolaou S, Triantafyllou D; Odontogenic keratocysts: Review of the literature and report of 16 cases. J Oral Maxillofac Surg, 1985;43:117.
5. Myoung H, Hong SP, Hong SD, Lee JI, Lim CY, Choung PH, et al.; Odontogenic keratocyst: review of 256 cases for recurrence and clinicopathologic parameters. Oral Surg Oral Med Oral Pathol Oral Radiol Endod, 2001;91(3):328-333.