

Endometrial Clear Cell Carcinoma: A Case Report and Literature Review

Bouchabaka Y*, El Matlini A, Raouah M, Saadoune M, Laatitioui S, Zayane A, Darfaoui M, Lalya I, El Omrani A, Khouchani M

Department of Radiation Oncology – Center Of Oncology and Hematology (COH) - Mohammed IV Hospital - Marrakech

DOI: [10.36347/sjmcr.2020.v08i07.010](https://doi.org/10.36347/sjmcr.2020.v08i07.010)

| Received: 19.06.2020 | Accepted: 26.06.2020 | Published: 21.07.2020

*Corresponding author: Bouchabaka Yassine

Abstract

Case Report

Background: Clear cell carcinoma (CCC) is first described a century ago, received little attention until the publication of two pathological studies by Silverberg and De Giorgi and Kurman and Scully in the 1970s. Endometrial CCC is rare subtype of endometrial carcinoma that seems to have a poor prognosis. Diagnosis is often difficult, but pathological examination with immunohistochemistry can be useful for solving differential diagnosis problem. **Case presentation:** We report the case of a woman with Endometrial Clear Cell Carcinoma (ECCC). Our purpose is to report this rare case, its diagnosis, prognosis and therapeutic management. **Conclusions:** Consensus on the optimal treatment is not well elucidated because of lack of prospective randomized studies.

Keywords: Clear cell carcinoma, endometrial carcinoma, prognosis, management, radiotherapy, radiation oncology, gynecological.

Copyright @ 2020: This is an open-access article distributed under the terms of the Creative Commons Attribution license which permits unrestricted use, distribution, and reproduction in any medium for non-commercial use (NonCommercial, or CC-BY-NC) provided the original author and source are credited.

INTRODUCTION

Endometrial Clear Cell Carcinoma (ECCC) is rare subtype of endometrial carcinoma accounting for only 2% to 5.5% of all endometrial malignancies [1]. It presents mainly in postmenopausal women and shows poor response to adjuvant therapy [2].

The diagnosis is based essentially on the final pathological examination, but sometimes it requires the use of immunohistochemistry. Clear cell histology appears to be a factor of poor prognosis.

CASE PRESENTATION

Mrs O.S aged 60 years was multipare, menarch at 17 and menopausal at the age of 57, under medical treatment for hypertension and diabetes mellitus. The patient was also under oral contraception pills for fifteen years.

Due to post menopausal bleeding without abdominal pain or any other signs, the patient underwent a gynecological examination and the transvaginal ultrasound showed an endometrial thickness. An endometrial biopsy was performed and the anatomopathological examination revealed a papillary small cell carcinoma of the endometrium. Immunohistochemistry exhibited negative

immunostaining for ER and PR, with moderate expression of Ki67 and P53.

Pelvic MRI showed a suspect and heterogeneous thickness of the endometrium. The patient underwent total hysterectomy, bilateral salpingo-oophorectomy and pelvic/para-aortic lymphadenectomy, and the final pathological examination revealed a grade 3 endometrial clear cell carcinoma with lymphovascular invasion. The tumor measured 4cm with 40% of myometrial infiltration, the right parametrium was also infiltrated. No vaginal or adnexal extension was found. Bilateral iliac lymphadenectomy removed 10 negative lymph nodes on the right side, and 2 negative lymph nodes on the left side. Thoracic and abdominal CT as an extension work-up came back negative. Tumor was classified IIIB stage according to FIGO 2018 classification. Adjuvant treatment was discussed in a multidisciplinary concertation meeting, but was not retained because the delay after surgery was too long (>4months). The patient is actually under surveillance for 9 months after the end of treatment without signs of recurrence or complications.

DISCUSSION AND CONCLUSIONS

Etiology

Etiology of clear cell endometrial cancer is not well understood in contrast to uterine endometrioid and

serous carcinoma, but in a study [3], at least one putative precursor lesion (PPL) was identified in 90% of the cases. These lesions were typically isolated glands or surface epithelium, within an otherwise normal endometrial region, that displayed cytoplasmic clarity and/or eosinophilia with varying degrees of nuclear atypia[3]. Compared to endometrioid, clear cell endometrial cancer may be more common in older women.[4]

Diagnosis

The majority of women with clear cell endometrial cancer are diagnosed after presenting a post menopausal bleeding. Less commonly, it is diagnosed as part of screening. The diagnosis of the histological type is done on surgical specimen or on biopsies and the final report confirms the diagnosis of the type CCC[5].

Pelvic ultrasound can aid in the diagnosis, however, caution must be taken when interpreting the results in women with post menopausal vaginal bleeding because a thin or indistinct endometrial stripe, especially when associated with other ultrasound abnormalities does not reliably exclude endometrial cancer.[6]

Pathology

Clear cell carcinoma of the endometrium, first described a century ago, received little attention until

the publication of two pathological studies by Silverberg and De Giorgi and Kurman and Scully in the 1970s[7,8].

Endometrial clear cell carcinoma is a member of type II endometrial tumors, which is a rare variant of endometrial carcinoma, along with serous cell and sarcomatous carcinoma.

The final diagnosis of primary clear cell carcinoma of the endometrium is made according to World Health Organization morphological criteria: presence of polygonal or hobnail or cells with clear or eosinophilic/oxophilic cytoplasm and nuclear atypia, with different pattern of growth, such as papillary, tubulocystic, or solid. Papillae with hyalinized stroma and hyaline bodies were also important diagnostic clues[9]. These features may exist alone or in combination, the papillary form seems to be the most common.

The typical immunohistochemical profile of clear cell carcinoma is HNF1B-positive, Napsin A-positive, ER-negative and PR-negative and p53-wild-type. This immunohistochemical panel is more useful in the distinction of clear cell carcinoma from endometrioid carcinoma than from serous carcinoma[10–13]. In a recent study, MMR deficiency was observed in 19% of clear cell carcinomas[14].

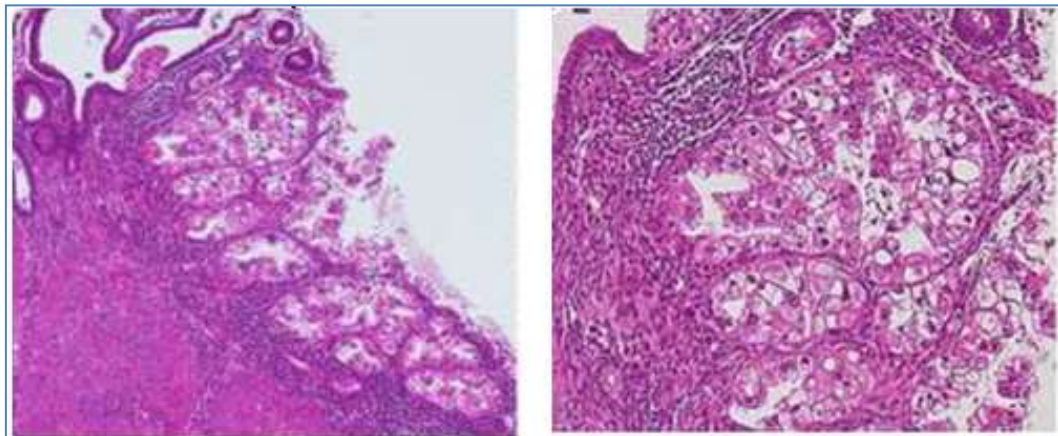


Fig-1 : (A) Low magnification showing a superficial focus of clear cell endometrial carcinoma. As shown in the picture, this case was confined to the endometrium without evidence of myometrial invasion. (B) Higher magnification of the same case showing the classic clear cell morphology.[11]

Treatment

Treatment for endometrial clear cell carcinoma incorporates surgery, chemotherapy, and/or radiotherapy, often in a multimodal combination[5].

The 2020 National Comprehensive Cancer Network (NCCN) guidelines recommend for primary treatment, total hysterectomy and bilateral salpingo-oophorectomy with surgical staging, peritoneal lavage for cytology, omental and peritoneal biopsies.

Adjuvant therapy is highly individualized. For patients with stage IA without myometrial invasion, options include chemotherapy with or without vaginal brachytherapy, observation if no residual serous or clear cell carcinoma in hysterectomy specimen, or EBRT with or without vaginal brachytherapy. For all others patients with more advanced disease, systemic therapy with or without tumor-directed RT are the preferred option. Adjuvant platinum/taxane-based therapy appears to improve survival in patients with uterine serous or clear cell carcinoma.

An American study (2017) included 4298 patients treated from 1998 to 2011 with stage I-IVA CCC, concluded that adjuvant therapy did not have a meaningful effect on survival[2].

A randomized phase III trial displayed the superiority of pelvic RT versus Vaginal Brachytherapy plus Carboplatin/Paclitaxel, in term of effectiveness and tolerance, in high-risk early stage endometrial carcinoma[15].

Consensus on the optimal use of adjuvant therapy for ECCC is still lacking. We need prospective, ideally randomized, data to best elucidate the optimal treatment. Recommendations for adjuvant therapy should remain individualized and based on the individual patient's risk factors.

Prognosis

Histology of clear cells is an independent predictor of poor prognosis[16]. There are numerous studies in the literature indicating myometrial invasion, extra-uterine spread and lymph node involvement in the presence of high CA-125 levels [17,18].

ECCC is generally diagnosed in advanced stages due to the tendency towards deep myometrial invasion, LVSI, and extra-uterine spread[19].

Cetinkay and Al, showed that the mean OS was significantly shorter in patients with higher pre-operative CA-125 values, tumor diameter >2cm, myometrial invasion $\geq 1/2$, cervical involvement, uterine serosal and/or adnexal invasion, lymph node metastasis and, thus, with advanced-stage disease. Uterine serosal invasion was the only independent prognostic factor associated with OS in the multivariate analysis[20].

Abdulfatah and al(2017), in a retrospective review of 165 patients with ECCC, showed that older age at diagnosis, advanced stage, deep myometrial invasion and adnexal involvement were independent poor diagnosis factors. Adjuvant radiotherapy had a significant positive impact on 5 year OS[21].

CONCLUSION

Endometrial Clear cell carcinoma is a very rare and aggressive disease and the role of a specialist pathologist is crucial to obtain the right diagnosis. Consensus on the optimal treatment is not well elucidated because of lack of prospective randomized studies.

List of abbreviations

ECCC: Endometrial clear cell carcinoma.
OS: Overall Survival
RT: Radiation Therapy
LVSI: Lymphovascular space invasion
NCCN: National Comprehensive Cancer Network

FIGO: International Federation of Gynaecology and Obstetrics

REFERENCE

- Gadducci A, Cosio S, Spirito N, Cionini L. Clear cell carcinoma of the endometrium: a biological and clinical enigma. *Anticancer Res. Avr.* 2010;30(4):1327- 34.
- Nieto K, Adams W, Pham N, Block AM, Grover S, Small Jr W, Harkenrider MM. Adjuvant therapy in patients with clear cell endometrial carcinoma: an analysis of the National Cancer Database. *Gynecologic oncology.* 2018 Jan 1;148(1):147-53.
- Fadare O, Liang SX, Cagnur Ulukus E, Chambers SK, Zheng W. Precursors of Endometrial Clear Cell Carcinoma: *Am J Surg Pathol.* déc 2006;30(12):1519- 30.
- Hoffman K, Nekhlyudov L, Deligdisch L. Endometrial Carcinoma in Elderly Women. *Gynecol Oncol.* août 1995;58(2):198- 201.
- Olawaiye AB, Boruta DM. Management of women with clear cell endometrial cancer. *Gynecol Oncol.* mai 2009;113(2):277- 83.
- Wang J, Wieslander C, Hansen G, Cass I, Vasilev S, Holschneider CH. Thin endometrial echo complex on ultrasound does not reliably exclude type 2 endometrial cancers. *Gynecol Oncol.* avr 2006;101(1):120- 5.
- Silverberg SG, De Giorgi LS. Clear cell carcinoma of the endometrium. Clinical, pathologic, and ultrastructural findings. *Cancer.* mai 1973;31(5):1127- 40.
- Kurman RJ, Scully RE. Clear cell carcinoma of the endometrium: an analysis of 21 cases. *Cancer.* févr 1976;37(2):872- 82.
- Carcangiu ML, Kurman RJ, Carcangiu ML, Herrington CS. WHO classification of tumours of female reproductive organs. International Agency for Research on Cancer; 2014.
- Reid-Nicholson M, Iyengar P, Hummer AJ, Linkov I, Asher M, Soslow RA. Immunophenotypic diversity of endometrial adenocarcinomas: implications for differential diagnosis. *Modern pathology.* 2006 Aug;19(8):1091-100.
- Zannoni GF, Santoro A, Angelico G, Spadola S, Arciuolo D, Valente M, Inzani F, Pettinato A, Vatrano S, Fanfani F, Scambia G. Clear cell carcinoma of the endometrium: an immunohistochemical and molecular analysis of 45 cases. *Human pathology.* 2019 Oct 1;92:10-7.
- Han G, Soslow RA, Wethington S, Levine DA, Bogomolny F, Clement PB, Köbel M, Gilks B, DeLair D. Endometrial carcinomas with clear cells: a study of a heterogeneous group of tumors including interobserver variability, mutation analysis, and immunohistochemistry with HNF-1 β . *International Journal of Gynecological Pathology.* 2015 Jul 1;34(4):323-33.
- Murali R, Davidson B, Fadare O, Carlson JA, Crum CP, Gilks CB, Irving JA, Malpica A, Matias-

- Guiu X, McCluggage WG, Mittal K. High-grade endometrial carcinomas: Morphologic and immunohistochemical features, diagnostic challenges and recommendations. *International Journal of Gynecological Pathology*. 2019 Jan;38(1 Suppl 1):S40.
14. DeLair DF, Burke KA, Selenica P, Lim RS, Scott SN, Middha S, Mohanty AS, Cheng DT, Berger MF, Soslow RA, Weigelt B. The genetic landscape of endometrial clear cell carcinomas. *The Journal of pathology*. 2017 Oct;243(2):230-41.
 15. Randall ME, Filiaci V, McMeekin DS, Von Gruenigen V, Huang H, Yashar CM, Mannel RS, Kim JW, Salani R, DiSilvestro PA, Burke JJ. Phase III trial: adjuvant pelvic radiation therapy versus vaginal brachytherapy plus paclitaxel/carboplatin in high-intermediate and high-risk early-stage endometrial cancer. *Journal of Clinical Oncology*. 2019 Jul 20;37(21):1810.
 16. Sakuragi N, Hareyama H, Todo Y, Yamada H, Yamamoto R, Fujino T, Sagawa T, Fujimoto S. Prognostic significance of serous and clear cell adenocarcinoma in surgically staged endometrial carcinoma. *Acta Obstetrica et Gynecologica Scandinavica: ORIGINAL ARTICLE*. 2000 Apr;79(4):311-6.
 17. Brassard L, Bessette P. Value of gynecological cytology and CA 125 level for the prediction of extrauterine malignancy in endometrial cancer. *Journal of obstetrics and gynaecology Canada: JOGC= Journal d'obstetrique et gynecologie du Canada: JOGC*. 2012 Jul;34(7):657-63.
 18. Yildiz A, Yetimalar H, Kasap B, Aydin C, Tatar S, Soylu F, Yildiz FS. Preoperative serum CA 125 level in the prediction of the stage of disease in endometrial carcinoma. *European Journal of Obstetrics & Gynecology and Reproductive Biology*. 2012 Oct 1;164(2):191-5.
 19. Scarfone G, Secomandi R, Parazzini F, Viganò R, Mangili G, Frigerio L, Villa A, Tateo S, Ricci E, Bolis G. Clear cell and papillary serous endometrial carcinomas: survival in a series of 128 cases. *Archives of gynecology and obstetrics*. 2013 Feb 1;287(2):351-6.
 20. Cetinkaya N, Selcuk İ, Ozdal B, Meydanli MM, Gungor T. Prognostic factors in endometrial clear cell carcinoma. *Archives of gynecology and obstetrics*. 2017 Jan 1;295(1):189-95.
 21. Abdulfatah E, Sakr S, Thomas S, Al-Wahab Z, Mutch DG, Dowdy S, Bandyopadhyay S, Munkarah A, Elshaikh M, Morris R, Ali-Fehmi R. Clear cell carcinoma of the endometrium: evaluation of prognostic parameters in a multi-institutional cohort of 165 cases. *International Journal of Gynecologic Cancer*. 2017 Oct 1;27(8).