

Case Report

Preventive prosthodontics by precision attachment- A case report

Dr. Krishna Chaitanya Kanneganti¹, Dr. Meer Abbasi², Dr. V. Vamsikrishna Reddy³, Dr. Dileep Nag Vinnakota⁴

^{1,2}Post graduate student, ^{3,4}Reader, Department of Prosthodontic dentistry, Narayana Dental College and Hospital
Nellore; Andhra Pradesh, India

***Corresponding author**

Dr. Dileep Nag Vinnakota

Email: dileepnagmnds@yahoo.co.in

Abstract: Prosthodontic practice should always concentrate on procedures that prevent the excessive loss of jaw bone and those that contribute in maintaining the alveolar ridge height. Overdentures are one such option wherein roots prevent alveolar bone resorption, provide better load transmission, maintain sensory feedback and achieve better stability of denture with emphasis on psychological aspect of not being completely edentulous. Additionally, precision attachment retained Overdentures distributes the masticatory forces, minimize trauma to abutments and soft tissues, attenuate ridge resorption and improve esthetics. Hence, the present case report discusses the use of stud attachment (Rhein'83) in the fabrication of attachment retained Overdenture.

Keywords: Overdenture, precision attachment, rhein'83, stud attachment

INTRODUCTION

Preventive prosthodontics emphasizes the importance of procedures that delay or eliminate future prosthodontic problems. In patients presenting with few remaining over erupted, tilted and/or mobile teeth, extraction should not be planned before considering the advantage of retaining their roots and thus the surrounding alveolar bone. Retention of roots of one or more teeth for planning an Overdenture offers the patient several advantages, from functional as well as biologic stand point. Extraction of all the teeth and replacement with complete denture is not the most desirable treatment, especially in the mandible; [1-4] many sequelae like loss of discrete root proprioception, the progressive loss of alveolar bone and the transfer of all the occlusal forces from the prostheses to the oral mucosa, make the complete denture progressively less effective [5] Poor long term functional service [6] and no long term neuromuscular benefit [7] for edentulous patients with complete dentures are reported. Thus, Overdenture should be considered in the event of alveolar bone loss and subsequent development of an unfavorable crown-root ratio, as less bone loss in Overdenture abutments is reported [8-10]. Studies have also proved superiority of Overdentures over conventional dentures, when the patient satisfaction is considered [11, 12].

Precision attachment retained Overdentures can offer additional advantage in dentistry because of their flexibility. They are being largely ignored by the dental professionals for understandable reasons like

notable cost and an inadequate grasp of their application. For decades, attachments made entirely of metal were used; and despite the application of sound technical concepts and care by the laboratory technicians, various problems were encountered. With time and experience these techniques improved, but, patients continued to utilize the prosthesis with results inferior to what they expected [11, 12]. Hence, the present case report discusses the clinical success of rhein'83 stud attachments used in the fabrication of attachment retained Overdenture.

CASE REPORT

A 48 year old male patient visited to the Department with ill-fitting interim removable prostheses. On examination, patient had 13, 23, 33 (grade II mobile), 34 and 44. (Figure1) Endodontic treatment was planned for all the teeth and considering retention factor, stud attachments were planned in the lower arch; and because of adequate surface area conventional Overdenture copings in the upper arch. As mandibular canine was mobile, conventional coping was planned for that tooth for the transmission of axial forces towards the apex. Ethical approval was obtained from the Institutional Ethical Committee and treatment plan executed. Diagnostic impressions were made with an irreversible hydrocolloid (Tropical gin, Zhermack INDIA Limited) and impressions poured with Type II dental stone (Kalabhai Karson Pvt. Ltd). All coronal portions of the teeth on the model were cut 1mm from the gingival margin with bard parker blade (No.12) and special trays fabricated conventionally using auto

polymerizing acrylic resin (DPI self cure, Dental products of India).

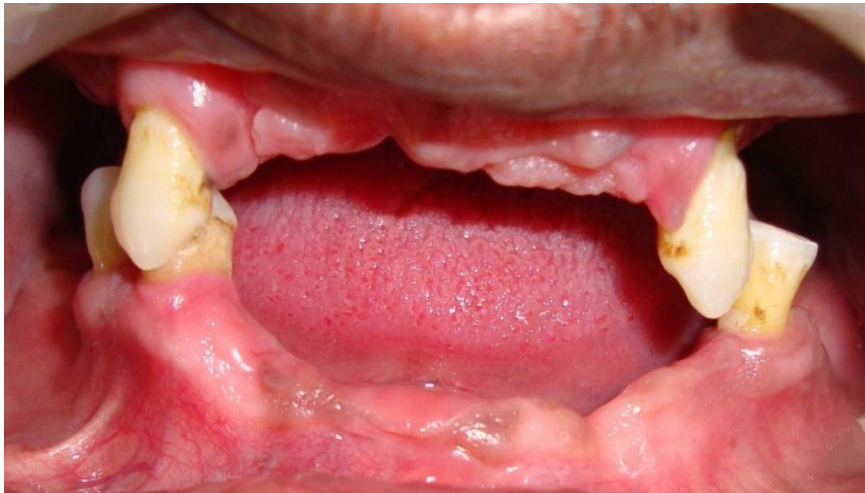

Fig.1. Pre- operative intraoral photograph

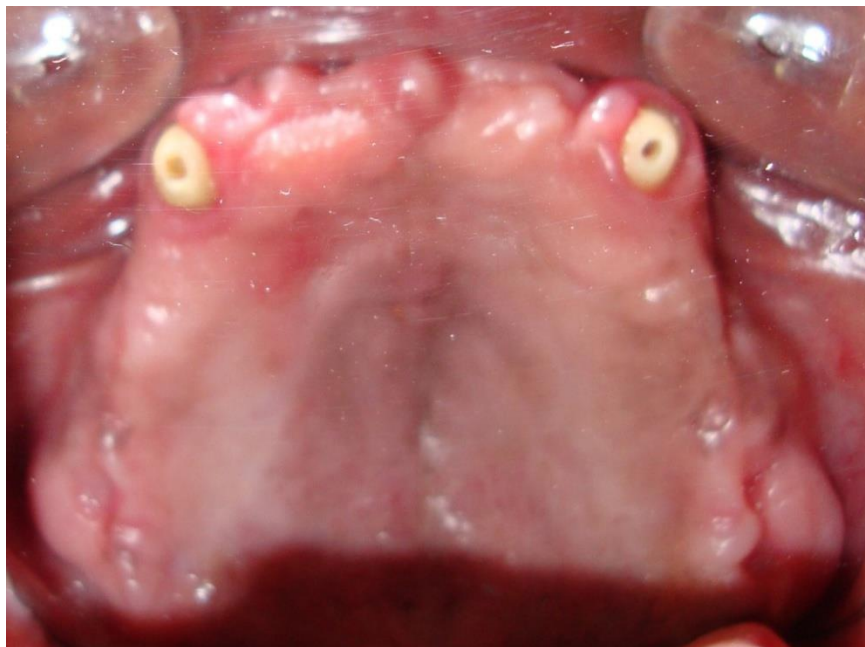


Fig.2. Maxillary canines prepared to receive conventional dowel copings

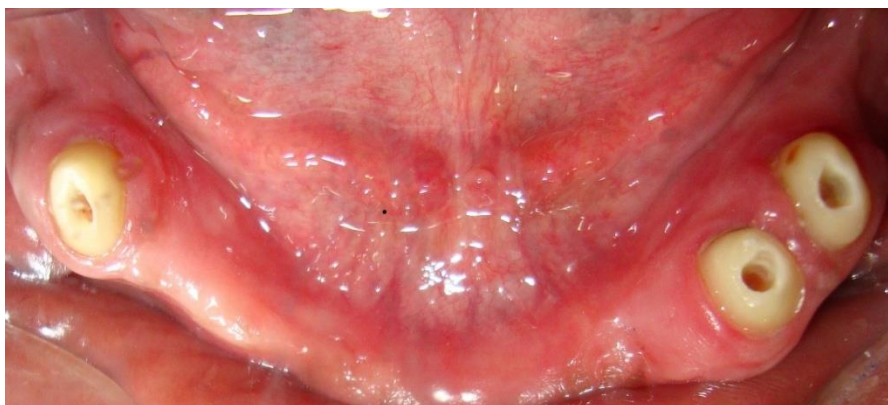

Fig.3. Mandible-Premolars and canine prepared to receive copings with attachments and Conventional coping respectively

Post space preparation was done to all the endodontically treated teeth with passo reamers (28mm, Dentsply, Maillefer). Length of the coronal portion of the teeth was reduced to 1mm above the gingiva and the margins prepared with sintered diamond bur (878K/010/8, Pointed taper diamond, Coltene India Limited) to create chamfer finish line and receive dowel copings (Figure 2 and 3). Post space impressions were made with Rhein 83 impression posts. Impressions were made with poly vinyl siloxane and poured in Type IV dental stone (Kalabhai Karson Pvt. Ltd). Wax patterns

were fabricated both for post space and copings with crown wax (crown wax hard blue, Bego dental 40111, Germany). Prefabricated Rhein'83 plastic patterns for stud attachments (micro, 1.8mm diameter head) (Figure 4) were attached to these patterns using parallelmeter. These patterns were casted in cobalt chromium alloy (Wirobond® 280, Bego Dental Germany). After divesting, the stud attachments and the conventional copings were finished and polished. The conventional copings and copings with stud attachments were checked for intraoral fit.




Fig.4. Prefabricated Rhein'83 plastic patterns for stud attachments (micro, 1.8mm Diameter head)

Conventional border moulding was done with Type I, low fusing compound (DPI green stick compound, India) and the wash impressions were made by picking up the conventional copings and copings with attachments using hydrophilic light body addition silicone impression material (Aquasil Ultra LV, Dentsply India limited) (Figure 5). Casts were poured with Type IV dental stone (Kalabhai Karson Pvt. Ltd). A cast metal reinforcement was fabricated to prevent the midline fracture of lower denture. Jaw relations were recorded, teeth try in done to check for proper

centric relation, followed by acrylization, finishing and polishing. Copings were cemented using resin cement (RelyX™ Unicem Self-Adhesive Resin Cement, 3M India limited) along with prostheses. (Figure 6, 7, 8 and 9) Patient was advised to avoid prostheses removal and post insertion recall done after 24 hours. Case was followed clinically after 1week, 1month, 6 months, 1 year and thereafter annually for four years. Every year elastic retentive caps were changed to replace worn-out caps and restore the original retention.

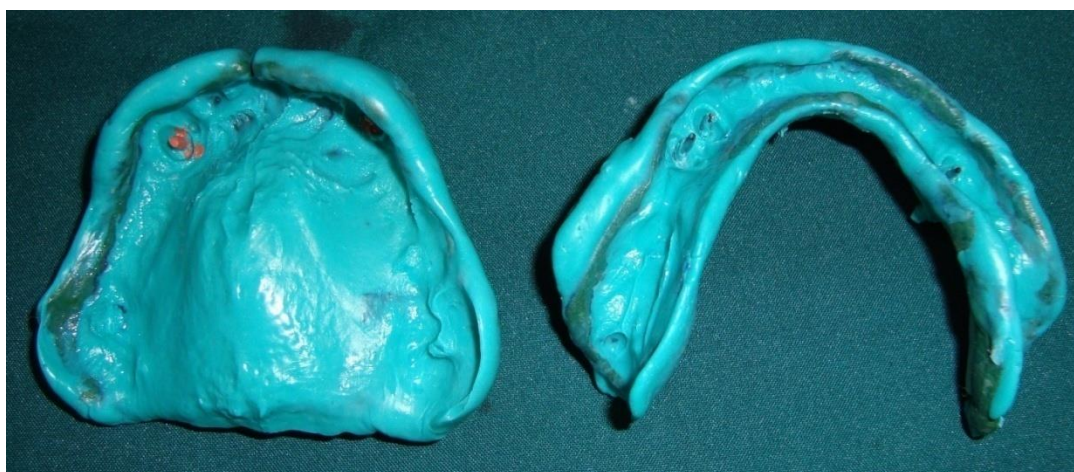


Fig.5. Final impressions for dowel copings

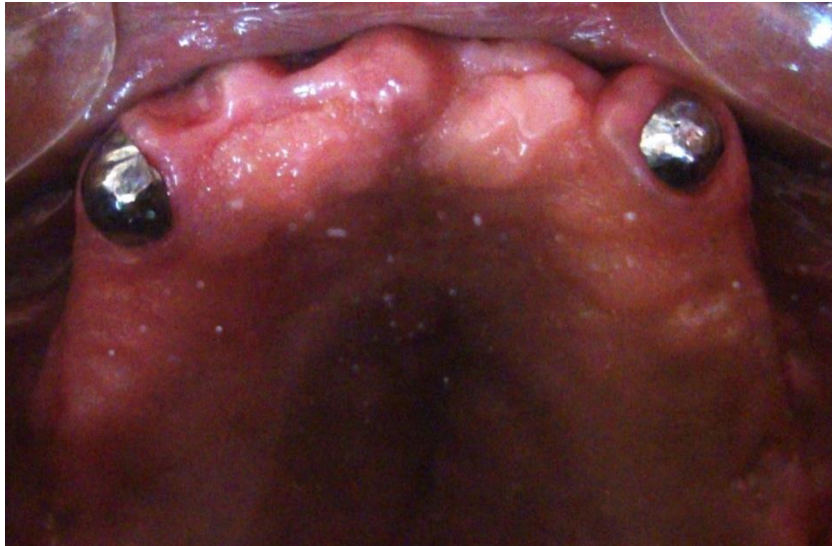

Fig.6. Maxillary conventional copings

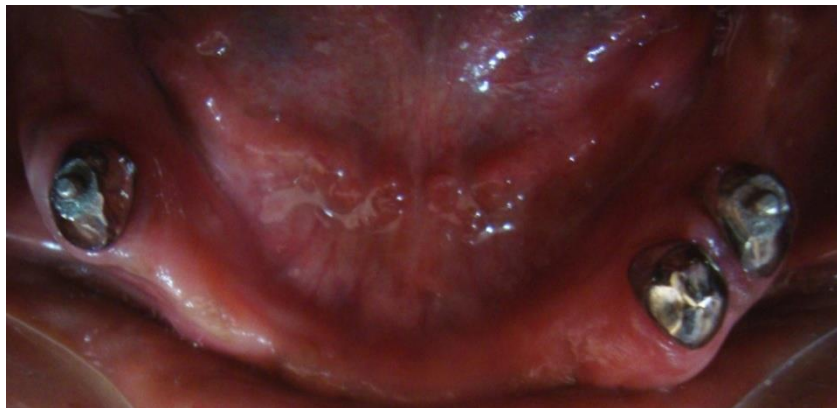

Fig.7. Mandible - copings with attachments for both the premolars and conventional coping for canine

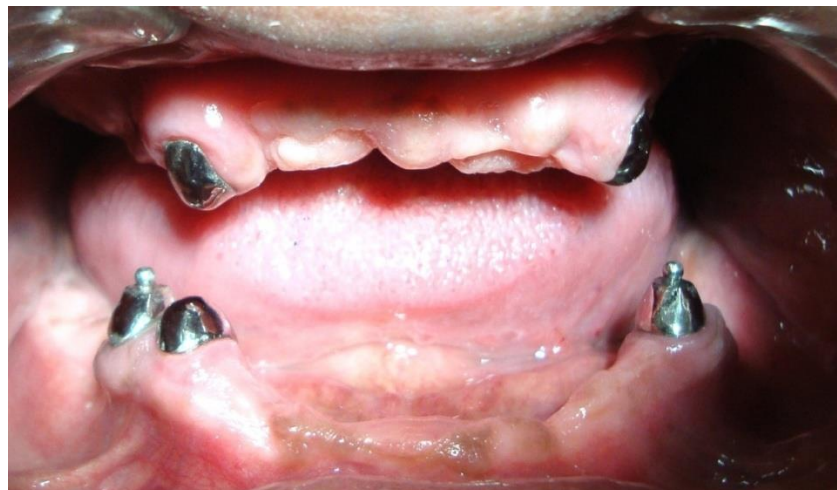

Fig.8. Maxillary and mandibular copings

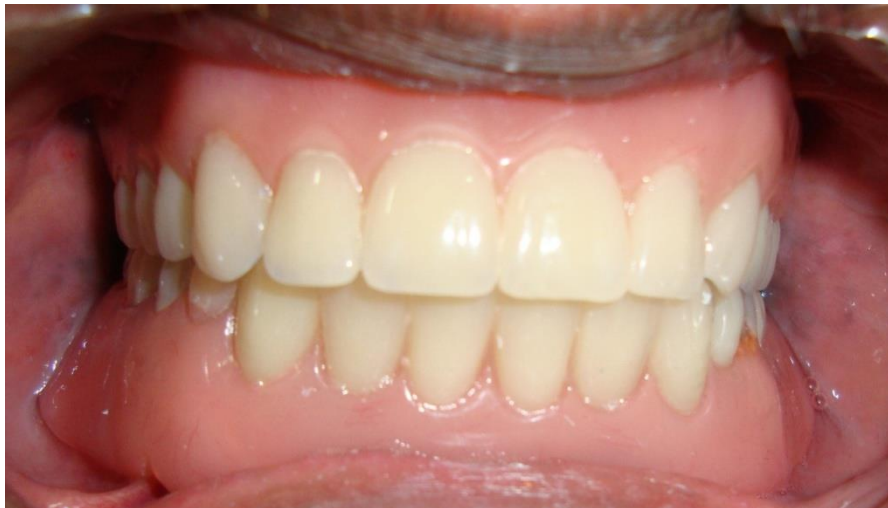

Fig.9. Definitive prostheses

DISCUSSION

The alveolar bone with its overlying mucosa will never be intended to receive the full force of a complete denture. Thus, the major problem with complete dentures is the constant and rapid loss of alveolar bone [5, 13]. This resorptive process referred to as reduction of residual ridges varies among individuals and is a chronic progressive, irreversible disabling disease [8]. Almost 1.63mm of resorption in conventional denture wearers in 5 year period has been reported [14]. This remodeling of the bone results in insufficient retention, stability and support. Excessive amounts of resorption leads to excessive ridge atrophy leading to problems with appearance, habituation of denture, psychologic and economical effects [15-17]. The application of Overdentures has proved to result in less alveolar bone resorption in contrast to complete dentures [8, 13].

Attachment retained Overdentures further help in masticatory force distribution, minimize trauma to abutments and soft tissues, thus attenuating ridge resorption. They also improve the esthetics and retain proprioception. Attachments for Overdentures can be stud or bar type, which can again be rigid or resilient. Rhein'83 stud attachment is a form of sphere with a flat head (incomplete), while the inside of the cap has a completely spherical form (complete). When the attachment is assembled, an empty space is created between the cap and the sphere that forms a cushion of air, which favors both its resilience and sagging. (Figure 10) Considering the average gingival width of 0.2-3.0 mm, in many cases the elastic cap permits the prostheses to give way proportionately together with the gingival tissue. The sagging is also favored by materials that are sensitive to body temperature and liquids in the mouth that act as lubricants.

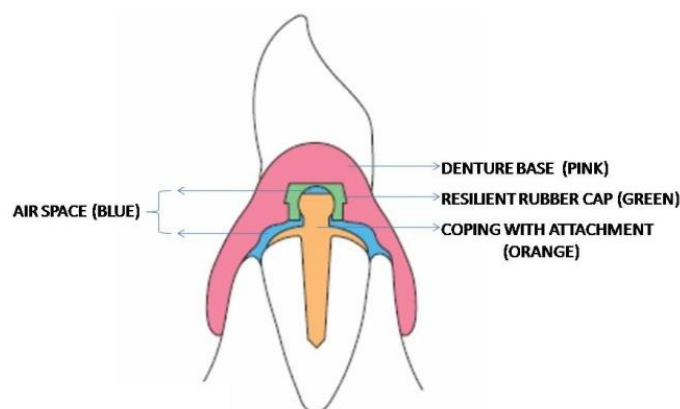


Fig.10. Pictorial representation of the prosthesis with stud attachment

Retention is a major factor that should be considered in precision attachment retained Overdentures. Studies have proved that there will be more loss of retention and physical deterioration of stud

attachments, and those retentive properties of attachments depend on type of dislodgement [18-20]. In order to overcome this problem, every year elastic retentive caps were replaced for the worn-out ones and

retention restored. Thus, in the selection of an Overdenture attachment design for a clinical situation, it is suggested that the clinician choose the one that provides the most equitable distribution of masticatory forces. The tissue resilient ball type used in the present case might have transferred the stress in a more favorable manner to the remaining structures in the oral cavity, as there is clinical success for over a period of four years.

CONCLUSION

Prosthesis design should embody principles that lessen or eliminate torque on supporting teeth. So, this paper highlights the fact that whenever possible precision attachment retained Overdenture should be planned, as it is healthier and comfortable to the patient than the conventional Overdentures.

REFERENCES

1. Carlsson GE, Otterland A, Wennström A, Odont D; Patient factors in appreciation of complete dentures. *J Prosthet Dent*, 1967; 17:322–328.
2. Mericske-Stem R; Treatment outcomes with implant-supported Overdentures: Clinical considerations. *J Prosthet Dent*, 1998; 79:66–73.
3. Davis DM; The shift in the therapeutic paradigm: Osseointegration. *J Prosthet Dent*, 1998; 79:37–42.
4. Budtz-Jørgensen E, Chung JP, Mojon P; Successful aging—the case for prosthetic therapy. *J Public Health Dent*, 2000; 60:308–312.
5. Brewer AA, Morrow RM; Overdentures. 2nd edition, The C.V. Mosby company, St.Louis,1980:370
6. Dorner S, Zeman F, Koller M, Lang R, Handel G, Behr M; Clinical performance of complete dentures: A retrospective study. *Int J Prosthodont*, 2010; 23:410–417.
7. Spitzl C, Rer Nat PP, Wichmann M, Heckmann S; Long-term neuromuscular status in Overdenture and complete denture patients with severe mandibular atrophy. *Int J Oral Maxillofac Implants*, 2012; 27:155–161.
8. Crum RG, Rooney GE; Alveolar bone loss in Overdentures: a five year study. *J Prosthet Dent*, 1978; 40:610-613.
9. Dhir RC; Clinical assessment of the Overdenture therapy. *J Indian Prosthodont Soc*, 2005; 5:187-192.
10. Brkovic-Popovic S, Staniscic-Sinobad D, Postic SD, Djukanovic D; Radiographic changes in alveolar bone height on Overdenture abutments: a longitudinal study. *Gerodontology*, 2008; 25:118–123.
11. De Lucena SC, Gomes SGF, da Silva WJ, Del bel cury AA; Patients' satisfaction and functional assessment of existing complete dentures: correlation with objective masticatory function. *Journal of Oral Rehabilitation*, 2011; 38:440–446.
12. Assuncao WG, Barao VAR, Delben JA, Gomes EA, Tabata LF; A comparison of patient satisfaction between treatment with conventional complete dentures and Overdentures in the elderly: a literature review. *Gerodontology*, 2010; 27:154–162.
13. Tallgren A; The continuing reduction of the residual alveolar ridges in complete denture wearers: A mixed longitudinal study covering 25 yrs. *J Prosthet Dent*, 1972; 27:120-132.
14. Kordatzis K, Wright PS, Meijer HJA; Posterior mandibular residual ridge resorption in patients with conventional dentures and implant Overdentures. *Int J Oral Maxillofac Implants*, 2003; 18:447–452.
15. Heath MR; Dental state and bone loss in the elderly. *Proc R Soc Med*, 1973; 66:590–594.
16. Klemetti E; A review of residual ridge resorption and bone density. *J Prosthet Dent*, 1996; 75:512–514.
17. Atwood DA; Bone loss of edentulous alveolar ridges. *J Periodontol*, 1979; 50(Suppl):11–21.
18. Chung K, Whiting D, Kronstrom M, Chan D, Wataha J; Retentive characteristics of overdenture attachments during repeated dislodging and cyclic loading. *Int J Prosthodont*, 2011; 24:127–129.
19. Chung KH, Chung CY, Cagna DR, Cronin RJ Jr; Retention characteristics of attachment systems for implant Overdentures. *J Prosthodont*, 2004; 13:221–226.
20. Rutkunas V, Mizutani H, Takahashi H; Influence of attachment wear on retention of mandibular overdentures. *J Oral Rehabil*, 2007; 34:41–51.