

**Research Article****A Comparative Study between Preoperative HRCT Scan Findings of Temporal Bone & Peroperative Findings in CSOM Unsafe Ear****Dr. Pramod Menon\*<sup>1</sup>, Dr. Anoop Babu R<sup>2</sup>**<sup>1</sup>Associate Professor of ENT, Govt. Medical College, Thrissur, Kerala State - 680596. India<sup>2</sup>Postgraduate student in ENT, Govt. Medical College, Thrissur, Kerala State - 680596. India**\*Corresponding author**

Dr. Pramod Menon,

Email: [drpramodmenon@gmail.com](mailto:drpramodmenon@gmail.com)

---

**Abstract:** High resolution CT (HRCT) has an important role in investigating Chronic Suppurative Otitis Media Active Squamosal disease (CSOM Unsafe ear) associated with bone erosions, but its ability for assessing erosions of each structure varies. The objective of this study was to compare the preoperative HRCT findings with peroperative findings in CSOM unsafe ear. In this descriptive diagnostic study, the HRCT findings of 45 patients who attended the Department of Otorhinolaryngology, Government Medical College, Thrissur, Kerala were compared with their peroperative findings and the data was statistically analyzed. In the present study, the sensitivity for the detection of cholesteatoma with the help of HRCT was 80 %. But it could not differentiate cholesteatoma from other soft tissue densities in 18% of the patients. HRCT showed a sensitivity and specificity of 83.8% and 100 % for detecting ossicular erosion. The sensitivity and specificity observed for detecting erosions of lateral semicircular canal, tegmen tympani, facial canal erosion were 50 % and 100 %, 75% and 100% and 60% and 100% respectively. Statistical analysis of the various observations on HRCT and preoperative findings showed significant agreement between both. HRCT is an important armamentarium for the Otorhinolaryngologist for the diagnosis and management of cholesteatoma. With its high sensitivity and extreme specificity, HRCT can pinpoint the damage to the middle ear structures with extreme precision and high accuracy. It also helps to prevent peroperative complications. HRCT remains the gold standard investigation for handling CSOM unsafe ear.

**Keywords:** Comparative Study, HRCT Temporal Bone, CSOM, Unsafe Ear, Mastoidectomy

---

**INTRODUCTION**

Chronic Suppurative Otitis Media Active Squamosal disease is one of the most common diseases of the ear leading to infectious and noninfectious complications and causes considerable morbidity. The use of HRCT in the preoperative evaluation of the patient with CSOM is still controversial. Still it is one of the most commonly used investigations in CSOM unsafe ear [1]. But its sensitivity and specificity in detecting different structures and disease may vary. In the present study, a comparative study was done between HRCT findings and per operative findings in CSOM unsafe ear.

**MATERIALS AND METHODS**

The study was conducted in 45 patients who were operated upon in Government Medical College, Thrissur for CSOM unsafe ear with preoperative HRCT scan. The period of study was one year from 2012 April to 2013 March. Help was obtained from radiology department for interpretation of HRCT. Ethical committee clearance was obtained initially. In each patient, history was elicited; physical examination and

investigation were carried out and recorded in a proforma. These findings were verified peroperatively under microscopic guidance. Peroperative findings were regarded as gold standard for determination of sensitivity and specificity of HRCT scan for different variables.

The data were entered in an excel spread sheet and statistical analysis was performed using microsoft excel and statistical package for social sciences (SPSS) version 16 for windows. For categorical variables, association was tested using chisquare test. Kappa value for agreement was also calculated.

**RESULTS**

In the present study, 45 cases of CSOM Unsafe ear were included. Of the 45 patients, 18 (40%) were females and 27(60%) males. The male to female ratio was 1.5. 10 patients (22.2%) were in the pediatric age group (<14years), 8 (17.8%) were adolescents (14 – 25 years) and 27 (60%) were adults (> 25 years). The ages ranged from 6 to 67 years with mean age of 29.6 years.

As regards to the clinical profile, 43 (95.5%) had ear discharge. Hard of hearing alone was the presenting complaint of 2 (4.4%) patients. 15 had (33.3%) a combination of these two.

Complications were present in 3 patients (6.67%). Clinically tympanic membrane was found abnormal in 43 patients (95.6%). Cholesteatoma flakes on otoscopic examination were seen in 10 (22.2%) patients. Clinical evidence of bone erosion in was seen in 5 (11.1%) patients.

Fistula sign was positive in 1 patient. All patients were subjected to canal wall down mastoidectomy (Modified Radical Mastoidectomy).

Blunting of scutum on HRCT scan was seen in 35 (77.8%) patients. Cholesteatoma was identified in HRCT scan in 36 patients. Diagnosis with HRCT was doubtful in 8 patients and was reported incorrectly as absent in 1 patient.

The various findings on HRCT were analysed using the  $\chi^2$  test and p values were calculated. 37 patients had ossicular erosion per operatively. HRCT could identify erosion in 31 patients (table 1).

**Table-1:**

HRCT	Per operative			
	Eroded		Intact	
	Frequency	Percent	Frequency	Percent
Eroded	31	83.8	0	0
Intact	6	16.2	8	100
Total	37	100.0	8	100

Malleus was found to be eroded in 17 (38%) patients per operatively, with partial erosion in 13 and full erosion in 4. HRCT could identify partial erosion in 12 (92.3%) and full erosion in 3 (75%). 37 patients (82.22%) had incus erosion, of which 32 had partial and 5 had full erosion. HRCT identified partial erosion in 24(75%) and full erosion in 4(80%) patients. In 1 case full erosion diagnosed by HRCT was found to be partial erosion.

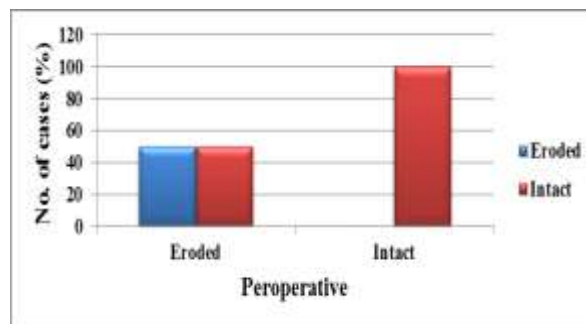
Per operatively it was found that 22 patients (49%) had stapes supra structure erosion, of which 18 patients had partial and 4 had full erosion. HRCT identified partial erosion in 12 (66.7%) and full erosion in all cases. In one case, HRCT scan over diagnosed partial erosion as full erosion.

5 patients (11%) had per operative facial canal dehiscence, of which HRCT could identify dehiscence in 3 patients (table 2).

**Table-2:**

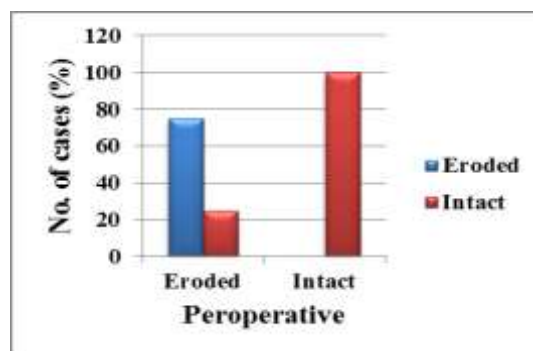
HRCT	Per operative			
	Dehiscent		Intact	
	Frequency	Percent	Frequency	Percent
Dehiscent	3	60.0	0	0
Intact	2	40.0	40	100
Total	5	100.0	40	100

Per operatively it was found that 2 patients had lateral semicircular canal erosion, HRCT could identify that erosion in 1 patient pre operatively (graph 1).

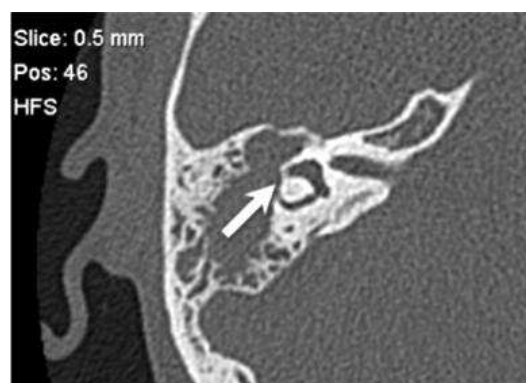

**Graph-1**

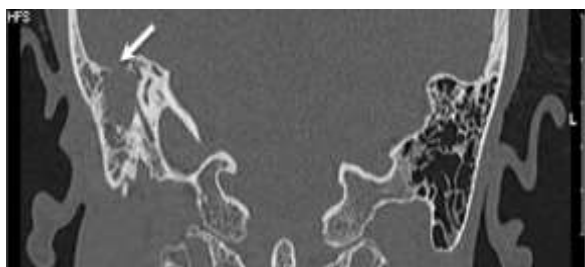
8 patients (17.8%) were found to have erosion of tegmen plate per operatively. HRCT could identify 6 such cases pre operatively (graph 2). There was no anatomical variation or any other disease pathologies encountered in the present study.



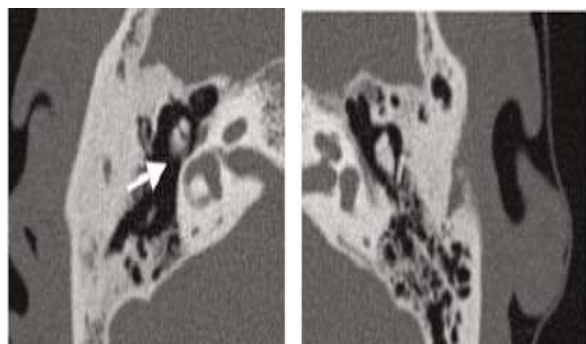
**Graph-2:**



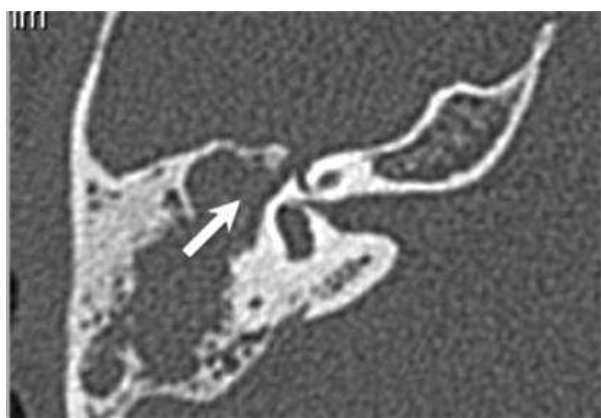
**Fig-1:(Axial HRCT. Right-sided dehiscence of lateral semicircular canal (arrow).**



**Fig-2: Coronal HRCT. Dehiscence of right tegmen tympani (arrow).**



**Fig-3: Axial HRCT. Erosion of body and short process of right incus (arrow), and the normal incus on the opposite side.**



**Fig-4: Axial HRCT showing Eroded right horizontal facial nerve canal (arrow)**

## DISCUSSION

Blunting of scutum was seen in 77.8% in this study, this is comparable with the study by Mafee [2] and David [3], who described blunting of the scutum as the criteria for cholesteatoma. It is considered as one of earliest sign of cholesteatoma in HRCT. The sensitivity of HRCT scan in detecting cholesteatomas was 80% in the present study. It is similar to the studies conducted by Jackler RK [4], Garber LZ and Park KH who reported sensitivity of HRCT from 70 to 96.88% with an average of 85%. In this study, in 18% of patients cholesteatomas couldn't be differentiated from other soft tissue density with the help of HRCT and in one case there was a false negative report. O'Reilly BJ [5] and Phelps PD mentioned that it was difficult to differentiate cholesteatomas from soft tissue mass like granulations with the help of HRCT. So we must rely

on secondary findings to help in diagnosis, like ossicular destruction or any other bone erosion.

Bone resorptions of the ossicles depend on the origin and mode of spread of cholesteatomas. In this study it was found that HRCT had sensitivity and specificity of 83.8% and 100%, false positive and negative rates of 0% and 16.2%, and positive and negative predictive values of 100 and 57.14 respectively in identifying ossicular erosion. There is agreement between the HRCT and per operative findings as evidenced by a p value of <0.001 and kappa score of 0.648. The maximum agreement was for malleus erosion (0.9) followed by incus (0.80) and stapes (0.72). The studies by Jackler and colleagues [4], Garber [6] and Park, report that HRCT has sensitivity ranging from 70 to 96.88% in detection of ossicular erosion which is comparable to the present study. To detect malleus erosion, CT had an overall sensitivity of 94.1% and specificity of 100%. Mafee [2] demonstrated a sensitivity of 89% in their study. In this study it was observed that the most common ossicle involved in CSOM Unsafe ear was incus, 82.22% of total cases with erosion. It was found that CT has a sensitivity and specificity of 78.4% and 100%, the positive and negative predictive values of 100 and 50, and a false negative rate of 21.6 in identifying incus erosion. This is supported by O'Donoghue [7], who reported a sensitivity of 81.4% in identifying incus erosion.

It was found in this study that the second most common involved ossicle was stapes (49%). As per this study, HRCT has a sensitivity and specificity of 77.3% and 100%, the positive and negative predictive values of 100 and 91.38, and a false negative rate of 22.7% in identifying stapes erosion. It was also observed in this study that involvement of the stapes is difficult to analyze due to inconsistent visualization on HRCT scan. Many authors like Jackler, Garber etc. have reported the same problem in their studies. In the current study, HRCT had a sensitivity and specificity of 60% and 100% in detecting facial canal erosion. Positive and negative predictive values of 100 and 95.24, and false positive and negative rates of 0% and 40% respectively were obtained in identifying facial canal erosion with the help of HRCT in this study. It is almost similar to the reports of O'Reilly, Jackler, Garber and Ranga Reddy Sirigiri [8]. However some studies by Freng [9], Gaurano and Chee NW show variable results.

The disparity can be explained on the fact that the visualization of thin bony structures like facial nerve canal may be misleading due to errors in computer reconstruction of their images. Also visualizing the tympanic portion of the facial canal is difficult when there is an adjacent pathologic soft tissue mass in the meso-tympanum. For identifying LSCC erosion, the HRCT scan had a sensitivity and specificity of 50% and 100% respectively in this study. In other studies by

Parisier SC [10], Chiossone E, Martin C and Abeele D [11] the sensitivity of HRCT in detecting LSCC fistula was approximately 55%. In one study, however, Fuse [12] had reported a sensitivity of 97% for the same. With evidence of erosion in the preoperative HRCT, any accusation of iatrogenic damage can be defended. In this study, the positive and negative predictive values in identifying fistula were 100 and 97.73 respectively and false positive and negative rates were 0% and 50%. There was a significant statistical agreement between the findings on HRCT and preoperatively as evidenced by a p value of <0.001 and kappa score of 0.647. In this study, HRCT had a sensitivity and specificity of 75% and 100%, the positive and negative predictive values of 100 and 94.87, and false positive and negative rates of 0% and 25% respectively in identifying tegmen plate erosion. The kappa score was found to be 0.83 which showed agreement between HRCT and per operative findings. Study by Mafee et al also showed a positive predictive value of 100 for the same. It was also observed that Tegmen erosion was well seen on coronal imaging, but again misinterpretations may result from volume averaging effects. Study by Garber, Sneyers W [13], Park KH has reported a specificity of more than 90% in diagnosing the condition.

The variable, anatomical variation could not be studied as there were no such patients in the current sample.

#### SUMMARY

- In the present study, the sensitivity for the detection of cholesteatoma with the help of HRCT was 80 %. But it could not differentiate cholesteatoma from other soft tissue densities in 18% of the patients.
- Blunting of scutum in HRCT was seen in 2/3 rd of the patients.
- HRCT showed a sensitivity and specificity of 83.8% and 100 % for detecting ossicular erosion.
- Involvement of incus was seen in most cases of cholesteatoma. HRCT showed maximum sensitivity in detecting erosion of malleus and least sensitivity for erosion of stapes.
- The sensitivity and specificity observed for detecting erosions of lateral semicircular canal, tegmen tympani, facial canal erosion were 50 % and 100%, 75% and 100% and 60% and 100% respectively.
- Statistical analysis of the various findings on HRCT and preoperative findings showed significant agreement between both.

#### CONCLUSION

HRCT is an important armamentarium for the Otorhinolaryngologist for the diagnosis and management of cholesteatoma. With its high sensitivity and extreme specificity, HRCT can pinpoint the damage to the middle ear structures with extreme precision and high accuracy. Thus it helps to identify the extent of the pathological involvement of middle ear milieu. HRCT

also alerts the surgeon about the complications and warrants an immediate intervention. This gives a scanner view for planning surgery and guides the surgeon with necessary precaution to prevent per operative complications. This is also a proof at hand and an armour to solve the medico legal issues. Even though not foolproof, HRCT remains the gold standard investigation for handling CSOM Unsafe ear.”

#### REFERENCES

1. Blevins NH, Carter BL; Routine preoperative imaging in chronic ear surgery. *Am J Otol*, 1998; 19(4): 5273-5275.
2. Mafee MF, Levein BC, Applebaum EL, Campos M, James CF; Cholesteatomas of the middle ear and mastoid- a comparison of CT scan and operative findings. *Otolaryngol Clin North Am*, 1988; 21(2): 265-292.
3. David C, Lia D, Thomas R, Bergeron M; Contemporary radiologic imaging in the evaluation of middle ear-attic-antral complex cholesteatoma. *Otolaryngol Clin North Am*, 1989; 22: 897-909.
4. Jackler RK, Dillon WP, Schindler RA; Computed tomography in suppurative ear disease: a correlation of surgical and radiographic findings. *Laryngoscope*, 1984; 94(6): 746-752.
5. O'Reilly BJ, Chevretton EB, Wylie I, Thakkar C, Butler P, Sathanathan N, Kenyon GS; The value of CT scanning in suppurative otitis media. *J Laryngol Otol*, 1991; 105(12): 990-994.
6. Garber LZ, Dort JC; Cholesteatoma: diagnosis and staging by CT scan. *J Otolaryngol*, 1994; 23(2): 121-124.
7. O'Donoghue GM, Bates GJ, Anslow P, Rothera MP; The predictive value of high resolution computed tomography in chronic suppurative ear disease. *Clin Otol*, 1987; 12(2): 89-96.
8. Sirigiri RR, Dwaraknath K; Correlative study of HRCT in Attico-Antral Disease. *Indian J Otolaryngol Head Neck Surg*, 2011; 63(2): 155-158.
9. Freng A, Larsen PL, Nordshus T; Cholesteatomas of the temporal bone. Preoperative CT versus peroperative findings. *Sc and Audiol*, 1988; 30: 185-188.
10. Parisier SC, Edelstein DR, Han JC; Management of labyrinthine fistulas caused by cholesteatoma. *Otolaryngol Head Neck Surg*, 1991; 104(1): 110-115.
11. Abeele D, Offeciers FE; Management of labyrinthine fistulas in cholesteatoma. *Acta Otorhinolaryngol Belg*, 1993; 47: 311-321.
12. Fuse T, Tada Y, Aoyagi M; CT detection of facial canal dehiscence and semicircular canal fistula: comparison with surgical findings. *J Comput Assist Tomogr*, 1996; 20(2): 221-222.
13. Sneyers W, Debruyne F, Morlion J, Lemahieu F, Baert A; Cholesteatomas of the temporal bone-a comparison of CT and operative findings. *Acta Otorhinolaryngol Belg*, 1991; 45(4): 369-373.