

## Case Report

### **Mid-surgical endodontics: retro touch to an orthograde approach**

Dr. Ayush Goyal<sup>1\*</sup>, Dr. Vineeta Nikhil<sup>2</sup>, Dr. Digvijay Singh<sup>3</sup>, Dr. Ritu Singh<sup>4</sup>

<sup>1</sup>Lecturer, Dept. Of Conservative Dentistry & Endodontics, Subharti Dental College, Meerut, Uttar Pradesh, India.

<sup>2</sup>Professor and Head, Dept. Of Conservative Dentistry & Endodontics, Subharti Dental College, Meerut, Uttar Pradesh, India.

<sup>3</sup>Post-graduate student, Dept. Of Conservative Dentistry & Endodontics, Subharti Dental College, Meerut, Uttar Pradesh, India.

<sup>4</sup>Lecturer, Dept. Of Paedodontics and Preventive Dentistry, Subharti Dental College, Meerut, Uttar Pradesh, India.

#### **\*Corresponding author**

Dr. Ayush Goyal

Email: ayush2106\_goyal@yahoo.co.in

---

**Abstract:** A numbers of factors have improved the success rate of endodontic surgery. One of these factors is the introduction of newer root-end filling materials. However, the absolute necessity of a root-end filling has been recently questioned by some authors. A fluid-tight seal is probably more important for successful healing than the type of filling placed at the resected root-end. This article aims to focus on the technique of mid-surgical endodontics, its indications and case reports documenting the same.

**Keywords:** Mid-surgical endodontics, mid-surgical obturation, endodontic surgery

---

#### **INTRODUCTION**

Though endodontic surgery has become very selective in contemporary dental practice, the techniques, materials used, and concepts involved in surgery must be continuously evaluated and modified. Periradicular surgery is the most frequently carried out endodontic surgical procedure [1]. The objective of periradicular surgery is to yield a favourable healing environment for periapical tissues [2]. The introduction of newer root-end filling materials in addition to development in microsurgical techniques has considerably improved the success rate of periradicular surgery [1]. Much research has been done on the rationale for use of root-end filling materials. A root-end filling provides a 'physical seal' in addition to the 'biological seal' of cementum, thereby imparting a 'double seal' at the root apex [3].

However, Chong and Ford have questioned the necessity of placement of a root-end filling in all cases of periapical surgery. According to the authors, if a root apex is inaccessible to instrumentation and the root canal filling that is exposed following root-end resection is of a good quality, a root-end filling is not a requisite for optimal healing [1].

Mid-surgical endodontics is easy to perform and at the same time ensures complete disinfection of the canal followed by adequate sealing of the root apex. The present article aims to describe the technique of

mid-surgical endodontics, its indications and case reports documenting the same.

#### **Mid-surgical endodontics- Indications**

1. Inaccessibility of instrumentation for retro-preparation and root-end filling
2. Failure to maintain a dry canal before obturation due to persistent drainage (even after multiple inter-appointment dressings)

#### **Mid-surgical endodontics- Technique**

The concepts and principles involved in all periradicular surgical procedures hold equally good for a periradicular surgery involving mid-surgical endodontics, apart from one difference. The hemostasis in the surgical field has to be 'integrated' with the achievement of a completely dry canal (during obturation). Complete removal of granulation tissue will itself lead to cessation of hemorrhage. Following apicectomy, once the osteotomy site can be clearly visualized, it is advisable to chemically cauterize the surgical wound. After cautery, pressure packing with epinephrine cotton pellets like Racellets (Pascal Co., Bellevue, WA), Epidri (Pascal Co.) and Radri (Pascal Co.) into the osteotomy site is a very useful approach to achieve complete hemostasis so as to proceed with the endodontic management.

The largest file that can pass through the resected root-end is selected and this becomes the

'master apical file'. This file is used to carry out circumferential filing of the whole canal. The root canal is now irrigated with chlorhexidine gluconate or betadene solution (with the epinephrine cotton pellet in place). The irrigating solution will pass through the root apex into the osteotomy site, thus disinfecting the whole 'complex'. The canal is dried using paper points and the largest gutta-percha cone that can pass through the resected root surface is selected.

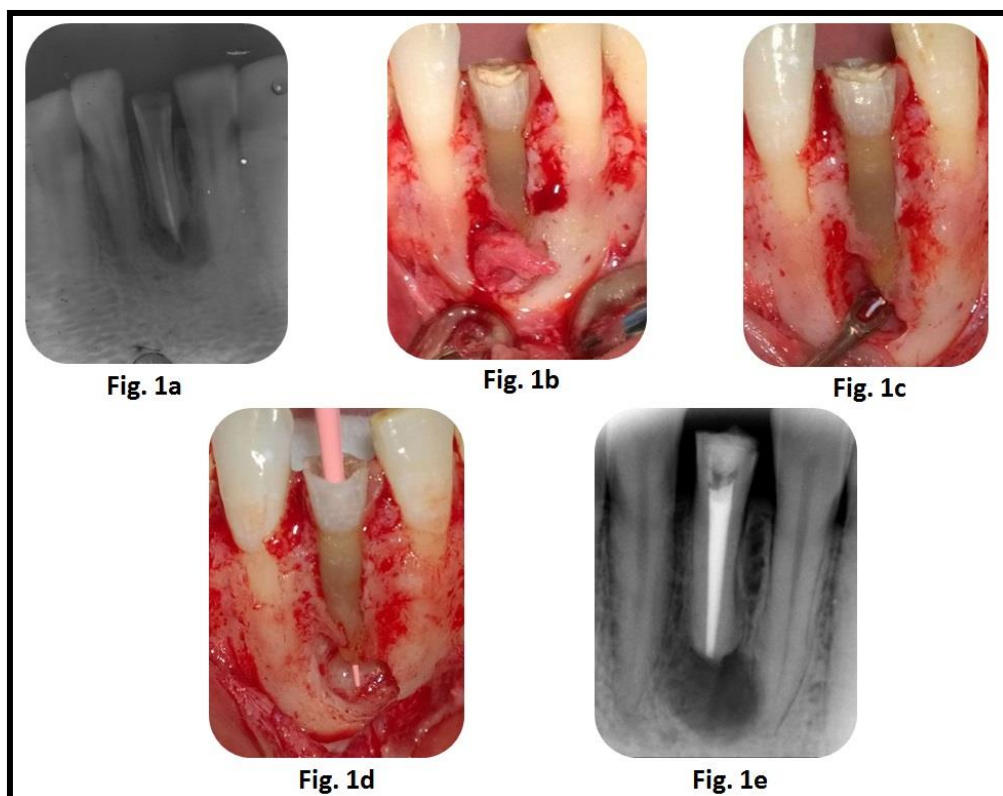
This 'master' GP cone is coated with a sealer and inserted into the canal with its tip extruding from the resected root-end. The extruding tip is now held with a long shank tweezer and pulled in an apical direction so as to achieve an optimal seal. The rest of the canal is now obturated using lateral compaction technique. A radiograph is now exposed so as to assess the quality of obturation. The radiographs can be taken chair-side using portable hand-held wireless equipment. Following obturation, the extruding GP tip is now sheared-off using a commercially available Gutta-cutter or a heated instrument. The resected root-end is now burnished with a warm burnisher to adapt the gutta-percha to the root surface.

The epinephrine cotton pellet is now removed and the osteotomy site is again flushed with betadene solution so as to remove dentinal debris, GP or sealer remnants. The obturation is now complete and the clinician can now proceed with flap repositioning and suturing.

## CASE REPORTS

### Case 1

This patient reported with a chief complaint of pain in relation to his lower front teeth region since one month and history of root canal treatment in relation to 31, one year back. On clinical examination, 31 was found to be discolored and was tender on percussion. Radiographic examination revealed over-extended obturation in relation to the same tooth along with a periapical lesion (Fig. 1a). The extruded gutta-percha could not be retrieved with orthograde approach and minimal persistent discharge was observed every time the root canal was opened. Periapical surgery with mid-surgical endodontics was planned to retrieve the extruded gutta-percha (Fig. 1b to 1e). The patient was asymptomatic during the follow-up period (3 months).



**Fig-1: (1a)- Pre-operative IOPAR of 31 showing over-extended obturation (1b)- Granulation tissue is seen after reflection of the flap (1c)- Extruded gutta-percha being retrieved (1d)-Largest cone that can pass through the resected root end (1e)-Post-obturation IOPAR of 31**

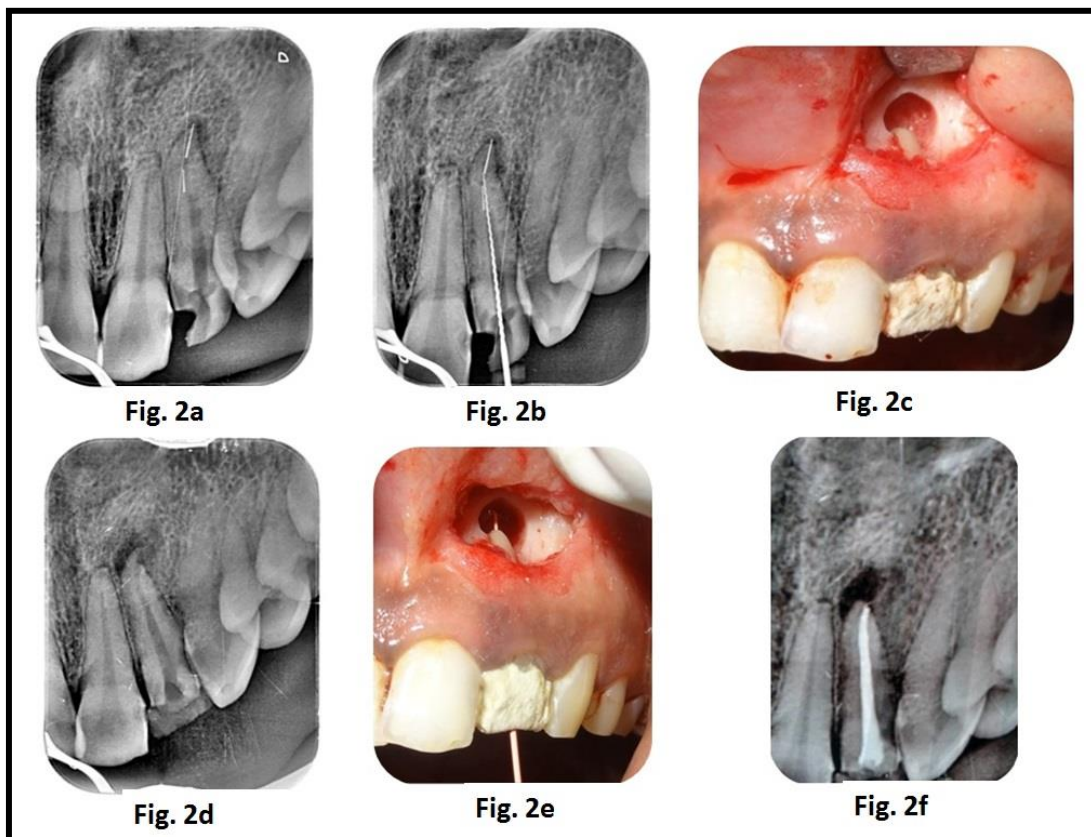
### Case 2

This patient reported with a chief complaint of a dislodged crown and pain in relation to her upper left lateral incisor with a history of an attempted root canal treatment 2 years back. On clinical examination, tooth 22 was found to be tender on percussion. Intra-oral

periapical radiograph (IOPAR) with respect to 22 revealed a separated instrument at the apical third. An ultrasonic (US) file separated when attempting to retrieve the first fragment (Fig 2a). The US file could easily be by-passed and subsequently came out with irrigation. The first fragment could neither be by-passed

nor be retrieved and minimal persistent discharge was observed every time the root canal was opened. Hence, periapical surgery was planned along with mid-surgical

endodontics (Fig. 2b to 2f). The patient was asymptomatic during the follow-up period (18 months).



**Fig-2:** (2a)US file separated while attempting to remove the initial fragment at the apical third (2b)- US file by-passed (2c)- Fragment removed and apicectomy done (2d)- Confirmatory IOPAR after fragment retrieval (2e)- Largest cone that can pass through the resected root end (2f)- Post-obturation IOPAR of 22

## DISCUSSION

Though mid-surgical endodontics might seem an arduous task initially, but it can be performed with relative ease, provided basic principles of endodontic surgery are followed. Inspection and management of resected root surface requires special armamentarium and in the absence of the same, treatment may be compromised. Clinicians will agree, that root-end resection done with anything other than US leads to unnecessary removal of tooth structure and erroneous placement of root-end filling.

In addition to this, cases refractory to inter-appointment dressings, presenting with persistent discharge are fine candidates for mid-surgical endodontics.

Endodontic literature on mid-surgical endodontics is sparse, though there are case reports documenting the same. Geetha *et al* have reported a case of internal resorption with periapical pathosis with respect to 22 and 23 in a 47 years old male patient. Upon chemo-mechanical preparation, profuse bleeding was observed in both 22 and 23. Hence, case was managed surgically along with mid-surgical obturation

[4]. Mathew *et al* have documented a case in which a 19 year old female patient reported with a chief complaint of discoloured anterior tooth. There was history of an attempted root canal treatment in relation to 21. IOPAR with respect to 21 revealed a blunderbuss canal associated with a periapical lesion. Retrofilling with glass-ionomer cement and mid-surgical obturation was planned [5].

Though mid-surgical endodontics is useful in selected number of cases, it should not be viewed as the primary mode of treatment. Only after the case has been carefully assessed, should the decision be made to proceed with mid-surgical endodontics. Endodontic management during a surgery requires both an experienced and a skillful operator. Only a carefully planned interdisciplinary approach involving both, a surgeon and an endodontist can lead to a successful treatment.

## CONCLUSION

Mid-surgical endodontics appears to be a valuable approach in management of certain cases. Following the correct protocol will increase the chances of success. Longitudinal studies with long term follow-

up are needed to accurately determine the success rate achieved with this technique.

#### REFERENCES

1. Chong BS and Pitt Ford TR; Root-end filling materials: rationale and tissue response. *Endod Top*, 2005;114-30.
2. Gutmann JL, Pitt Ford TR. Management of the resected root end: a clinical review. *Int End J* 1993; 233: 272-83.
3. Regan JD, Gutmann JL, Witherspoon DE; Comparison of Diaket and MTA when used as root-end filling materials to support regeneration of the periradicular tissues. *Int Endod J*, 2002; 35: 840-47.
4. Geetha P, Raveendran R, Padmakumar TP; Internal root resorption and periapical pathoses as dental complication of herpes zoster infection: Report of rare case with review of literature. *J orofac sci*, 2014; 6: 62-4
5. Mathew BP, Hegde MN; Management of non vital immature teeth -Case reports and review. *Endodontology*, 2010: 18-22.