

Case Report

Endodontic and surgical treatment of an uppercentral incisor with a radicular cyst following a trauma

Saeede Zadsirjan¹, NegarNorouzi*², Reza Mofidian³, Ali Haeri Tabatabaei⁴

¹ Department of Endodontics, Dental Faculty, Hamadan University of Medical Sciences, Hamadan, IR Iran

² Postgraduate student, department of endodontic, Dental school of Shahidbeheshti university of medical sciences, Tehran, Iran

³ Postgraduate student, department of oral and maxillofacial surgery, Dental school of Shahidbeheshti university of medical sciences, Tehran, Iran

⁴ Assistant professor, department of oral and maxillofacial surgery, Dental school of Shahidbeheshti university of medical sciences, Tehran, Iran

***Corresponding author**

Negar Norouzi

Email: dr.negar.noroozi@gmail.com

Abstract: Radicular cyst is the most common odontogenic cystic lesion of inflammatory origin. It is also known as periapical cyst, apical periodontal cyst, root end cyst, or dental cyst. It arises from epithelial residues in the periodontal ligament as a result of inflammation. The inflammation usually follows the death of dental pulp. This paper presents a case report of a patient with radicular cyst associated with a central incisor. In the present case due to the patient's apprehension regarding the presence of a swelling and also the lesions size and extent a surgical procedure was opted. After endodontic therapy, complete enucleation of cyst was done followed by apicoectomy and retrograde filling with MTA.

Keywords: apicoectomy; enucleation; Radicular cyst; root canal treatment

INTRODUCTION

Radicular cyst is an inflammatory jaw cyst originating from epithelial remnants of the periodontal ligament as a result of inflammation that is generally a consequence of pulp necrosis. The resulting cyst commonly involves the apex of the affected tooth [1]. It was reported that the incidence of cysts among apical lesions amounted to 40% to 50%, but more recent observations concluded that only about 15% can be considered as apical cysts [2]. Of these, about 50% are true apical cysts and the other half are categorized as apical pocket cysts, which are more likely to heal without surgical intervention[3].

CASE REPORT

A healthy 12-year-old male was referred to dental school of Shahid Beheshti University of medical sciences, with a chief complaint of swelling in palatal region. Patient gives History of trauma in upper anterior teeth 5 years ago.

On intra oral examination a swelling was present in the palatal region. Swelling was soft and fluctuant. Tooth #8 was found to be nonvital (no response to cold or electrical stimulation), whereas all other maxillary anterior teeth were normal in all

regards. Tooth was tender to vertical percussion and the periodontal probing depths were normal. Radiographs were taken and revealed a radiolucent lesion and the tooth #8 was open apex.

Consequently, the preliminary diagnosis was a radicular cyst. In consultation with the patient's parents, initial treatment was to be root canal therapy with an interim dressing of calcium hydroxide(Cinabartar, Tehran, Iran). On opening, copious drainage of very thin viscosity was noted, which persisted for some times despite repeated drying with paper points (Maillefer, Dentsply, Ballaigues, Switzerland) after shaping and alternately irrigating with sodium hypochlorite (NaOCl) 5% (Shemin company, Tehran, Iran) , EDTA 17% (Asia ChemiTeb. Co., Tehran, Iran). During the first appointment an anti-bacterial dressing (calcium hydroxide) was applied into the root canal. After 7 days, on opening, copious drainage was noted. Therefore calcium hydroxide therapy was repeated on second visit. On the third visit, we obturated the canal with MTA plug(MTA Angelus, Londrina, PR, Brazil) and warm vertical method, but there was not seen any improvement after 3 months. So the treatment was followed by surgical enucleation of cyst, apicoectomy. The procedure is as follows: After administration of

local anesthesia crevicular incision was given in buccal region which extends from distal of tooth #7 to mesial of tooth #10 regions. A full thickness mucoperiosteal flap was reflected and irrigated with normal saline. Buccal bone was intact; also access to lesion and apical root of tooth #8, complete curettage and enucleation of cyst was done. Then Root end of involved tooth was

resected and MTA filling was checked. Flap was closed with 5-0 silk following hemostasis. The histopathology report confirmed the diagnosis of an infected radicular cyst. Post-operative instruction given and patient was kept under Antibiotics and Analgesics. Patient was recalled at intervals of 7 days, 3, 6 months and 1 year(Fig1).

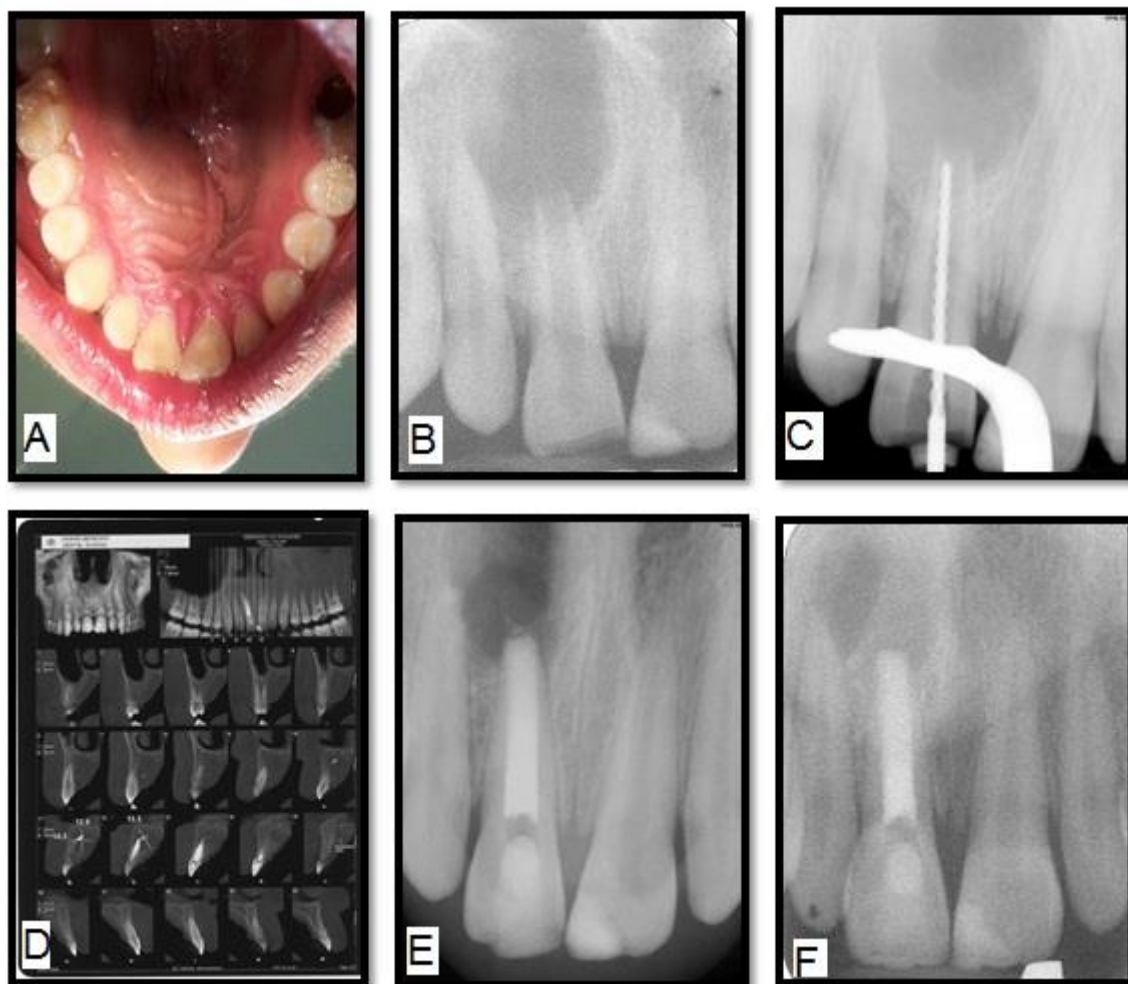


Fig 1: A- swelling in palatal region. B- Preoperative radiography C- working length detection D-Cone Beam Computed tomography before surgery.E- postoperative radiography F- follow up after 12 months

DISCUSSION

A radicular cyst is an odontogenic cyst of inflammatory origin preceded by a chronic periapical granuloma and stimulation of cell rests of Malassez. Although the source of the epithelium is cell rest of Malassez, other sources can be crevicular epithelium, sinus lining, or epithelium lining of fistulous tracts, have been suggested[4]. Radicular cysts are inflammatory lesions leading to bone resorption and can reach great dimensions and become symptomatic when infected or with great size due to nerve compression [5, 6]. The treatments of these cysts are still under discussion and many professionals option for a conservative treatment by means of endodontic technique[7]. However in large lesions the endodontic treatment alone is not efficient and it should be

associated to a decompression or a marsupialization or even to enucleation[8, 9]. The advantage of enucleation is the immediate rehabilitation resulting in fewer control appointments, which makes it a good choice for patients with poor compliance [10]. Disadvantages are the large defect and possible damages to adjacent structures owing to the surgical procedure. Another aspect is the higher risk of wound infection [11]. In fact, even more aggressive lesions such as odontogenic keratocysts are more often being first treated with decompression and then further treated with enucleation when the lesion is smaller and lining epithelium thicker[12]. Several recent studies have confirmed the effectiveness of marsupialization/decompression as a preliminary procedure in the treatment of odontogenic keratocysts, with a surprising number of lesions

exhibiting complete healing with no further surgical intervention [13, 14].

In the present case due to the patient's apprehension regarding the presence of a swelling and also the lesions size and extent a surgical procedure was opted. After endodontic therapy, complete enucleation of cyst was done followed by apicoectomy and retrograde filling with MTA.

REFERENCES

1. Delbem A, Cunha R, Vieira A, Pugliesi D; Conservative treatment of a radicular cyst in a 5-year-old child: a case report. *Inte J Paediatr Dent.* 2003;13(6):447-50.
2. Nair P; On the causes of persistent apical periodontitis: a review. *Int Endod J.* 2006;39(4):249-81.
3. Natkin E, Oswald RJ, Carnes LI; The relationship of lesion size to diagnosis, incidence, and treatment of periapical cysts and granulomas. *Oral Surg Oral Med Oral Pathol.* 1984;57(1):82-94.
4. Manwar NU, Agrawal A, Chandak MG; Management of infected radicular cyst by surgical approach. *International Journal of Dental Clinics.* 2011;3(4).
5. Sabhachandani N, Nagarathna D, Shanbag C, Nasila M; Enucleation of a radicular cyst lesion-A case report. *Journal of Pearl Dent.* 2014;5(1):47-51.
6. Nainani P, Sidhu GK; Radicular Cyst—An Update with emphasis on Pathogenesis. *Journal of Advanced Medical and Dental Sciences Research,* 2014;2(3).
7. Lokade J, Wankhade SV, Gade V; Nonsurgical endodontic treatment of a periradicular lesion using LSRT therapy: a case report. *International Journal of Dental Clinics.* 2012;4(3).
8. Danin J, Linder LE, Lundqvist G, Ohlsson L, Ramsköld LO, Strömberg T; Outcomes of periradicular surgery in cases with apical pathosis and untreated canals. *Oral Surg Oral Med Oral Pathol Oral Radiol Endod.* 1999;87(2):227-32.
9. Aslan M, Aras DMH, Şimşek G, Ertunç D; Large Dentigerous And Radicular Cysts Of The Mandible (Case Report). *Atatürk Üniversitesi Diş Hekimliği Fakültesi Dergisi.* 2006; 2006(1).
10. Rajkumar G, Hemalatha M, Shashikala R, Sonal P; Massive keratocystic odontogenic tumor of mandible: a case report and review of literature. *Indian Journal of Dental Research.* 2011;22(1):181.
11. Nawaz M, Yazdanie N, Faheemuddin M; Rehabilitation of a cystic mixed dentition mandible following marsupialization with a multipurpose acrylic splint acting as a space maintainer and an obturator. *J Ayub Med Coll Abbottabad.* 2011;23(2).
12. Oh S, Park J-H, Paeng J-Y, Kim C-S, Hong J; Comparison of surgical approach and outcome for the treatment of cystic lesion on lower jaw. *Journal of the Korean Association of Oral and Maxillofacial Surgeons.* 2012;38(5):276-83.
13. Sulabha A, Choudhari S, Kenchappa U, Totad S; Massive keratocystic odontogenic tumor of mandible crossing the midline in 11-year child: An unusual case report and its management. *Dental Hypotheses.* 2013;4(1):28.
14. Blanas N, Freund B, Schwartz M, Furst IM; Systematic review of the treatment and prognosis of the odontogenic keratocyst. *Oral Surg Oral Med Oral Pathol Oral Radiol Endod.* 2000;90(5):553-8.