

Original Research Article

Lingual Neurectomy in the Treatment of Trigeminal Neuralgia

Dr. S. Daniel Sathiya Sundaram¹, Dr. Jeba Karunya R², Dr. Santosh Koshy³¹Asst. Professor, Dental Department unit 2, Chrisitan Medical College and Hospital, Vellore, India²Asst. Professor, Radiotherapy Department unit 2, Chrisitan Medical College and Hospital, Vellore, India³Professor, Dental Department unit 2, Chrisitan Medical College and Hospital, Vellore, India

*Corresponding author

Dr. S. Daniel Sathiya Sundaram

Email: danielvellore@gmail.com

Abstract: Peripheral neurectomies for trigeminal neuralgia has been one of the modalities of treatment, which is cheaper, but with co morbidities. But the success in treating the third branch of the trigeminal nerve with peripheral neurectomy has been greatly reduced because of the failure to perform lingual neurectomy along with the other branches. We propose that lingual neurectomy should be done in cases where mental and inferior alveolar neurectomies have failed to relieve the pain and we also describe the surgical procedure for lingual neurectomy to ensure better success in the treatment of trigeminal neuralgia, through peripheral neurectomy.

Keywords: Peripheral Neurectomy, Lingual Nerve, Trigeminal Neuralgia

INTRODUCTION

The characteristic, covering face with hands, writhing in intolerable short bursts of pain is a sight that any clinician who deals with trigeminal neuralgia cannot forget. Treating trigeminal neuralgia can be so satisfying for the clinician when a relieved patient comes for review but can also be nagging if there is recurrence or no respite even after treatment. Treatment options can be medical management, microvascular decompressions, radiofrequency management, ganglionolyses or peripheral neurectomies [1].

REVIEW OF LITERATURE

Peripheral Neurectomy is a age old procedure practised from as early as 1830 [2]. There is a lot of literature on peripheral neurectomies of third branch of trigeminal nerve (V3), which is mental nerve neurectomies and inferior alveolar nerve neurectomies, [3] but literature on lingual nerve peripheral neurectomy is few and the procedure is a remotely practiced surgery. So many articles and centres deal with peripheral neurectomies of (V3) as confined to inferior alveolar and mental neurectomies [4]. But often times the reason for failure of peripheral neurectomies is, not addressing the lingual nerve.

MATERIAL AND METHODS

This study is a retrospective study in which records of patients that reported to or referred to Dental unit 2 OPD and diagnosed with trigeminal neuralgia between the years 2013 and 2015 was collected.

Categorisation was done on the basis of treatment offered which is medical or surgical and symptom free status or relapses were noted.

The total number of patients in this study is 11. All of them were started with Carbamazepine and pregabalin in varying doses after consultations with the department of Neurology. Of these 11 patients 4 were previously diagnosed with trigeminal neuralgia and were already on medicines for it and they sought surgical remedy. Peripheral neurectomy was performed in 4 patients of which 2 were symptom free at the end of two years, third patient was symptom free only for about weeks and was later diagnosed with leprosy [5] of the region which was surprisingly painful. The fourth patient was never symptom free after peripheral neurectomy (mental neurectomy). A week later lingual neurectomy was performed and she was symptom free for a year and then never reported back, was lost to follow up. The other seven of the total eleven patients are still on medical management though with increased dosages and are comfortable.

Surgical Procedure

This procedure can be done under local anaesthesia on a dental chair by an oral and maxillofacial surgeon. The access incision is similar to that of a lower third molar incision without the buccal extension anteriorly. The reflection of the mucosal flap in the lingual aspect of the third molar is a little different. The concept and practice of protecting the

lingual nerve by raising a mucoperiosteal flap and placing the elevator subperiosteally thereby guarding the lingual nerve [6] has to be modified a little. The dissection in the lingual side of the lower third molar should be supra periosteal, a dissecting scissors would be very handy. As the mucosa alone is dissected off, the course of lingual nerve will be from superior to inferior, posteroanteriorly and is closer to the mandible around the third molar region, the nerve is much more medial as it runs anteriorly. The depth of the nerve varies with individuals but can be expected within a centimetre inferior to the lingual bony margin distal to the second molar or third molar, once the nerve is identified it is dissected off and about a centimetre length of the lingual nerve is resected and primary closure done.

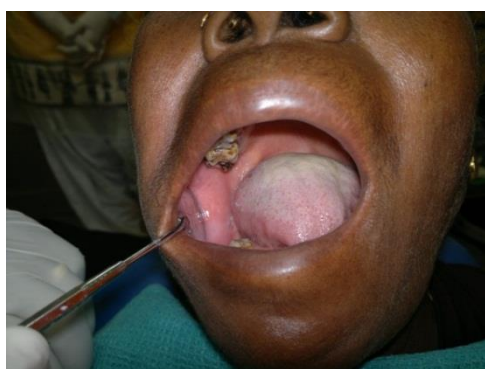


Fig-1: prior to incision

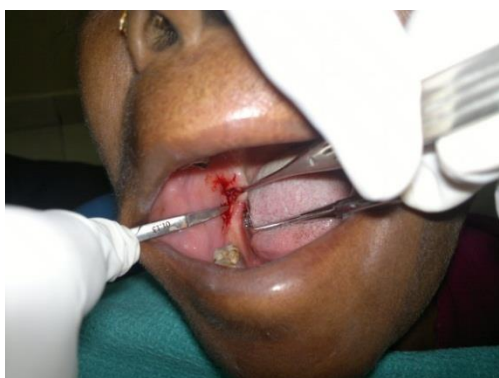

Fig-2: supra periosteal dissection with dissecting scissors

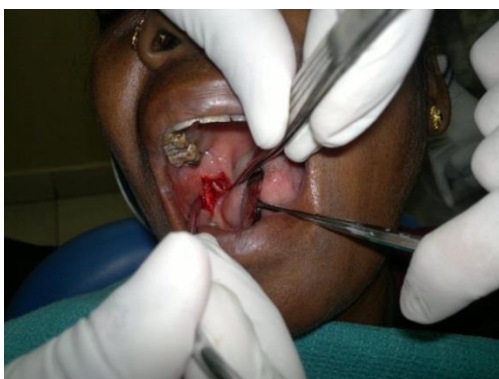


Fig-3: the identified lingual nerve

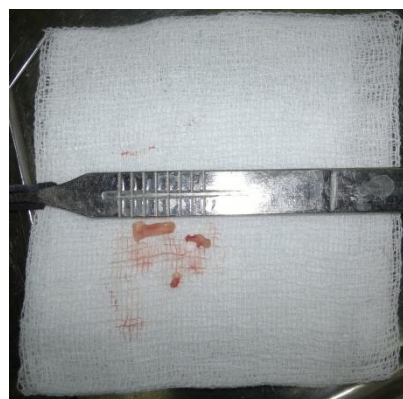

Fig-4: shows the resected length of nerve

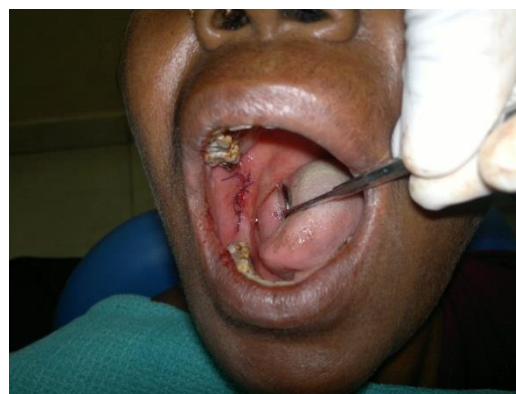

Fig-5: post suturing

DISCUSSION

The reason why lingual nerve neurectomies are not practised could be because of the restricted access and probably difficulty to identify and remove a considerable length of the lingual nerve. But the reality of inadvertent damage of lingual nerve leading to lingual nerve paraesthesia, post-surgical removal of lower third molars [7] and the longevity of the paraesthesia should be encouraging factors when a planned lingual neurectomy for therapeutic purposes are considered. The post operative, expected permanent loss of sensation to the particular side of the tongue should be adequately explained to the patient and the procedure be done with an informed consent.

When peripheral neurectomy of the mental or inferior alveolar nerve is done and still the patient is not symptom free, a diagnostic lingual nerve block should be given and if the patient is relieved of pain with a lingual nerve block lingual neurectomy should be performed.

CONCLUSION

Though peripheral neurectomies are considered obsolete now [8], for patients who are not fit to undergo a procedure under GA and for those who cannot afford other treatment options, and for those remedy from medical management is failing, lingual neurectomy along with the other already in practice mental and inferior alveolar neurectomies would

increase the success rate of the peripheral neurectomies, besides the procedure is a low cost one and would be an effective treatment tool.

REFERENCES

1. Obermann M. Treatment options in trigeminal neuralgia. *Ther Adv Neurol Disord.* 2010 Mar;3(2):107–15.
2. Ali FM, Prasant M, Pai D, Aher VA, Kar S, Safiya T. Peripheral neurectomies: A treatment option for trigeminal neuralgia in rural practice. *J Neurosci Rural Pract.* 2012;3(2):152–7.
3. Mason DA. Peripheral neurectomy in the treatment of trigeminal neuralgia of the second and third divisions. *J Oral Surg Am Dent Assoc* 1965. 1972 Feb;30(2):113–20.
4. Agrawal SM, Kambalimath DH. Peripheral Neurectomy: A Minimally Invasive Treatment for Trigeminal Neuralgia. A Retrospective Study. *J Maxillofac Oral Surg.* 2011 Sep;10(3):195–8.
5. Daniel Sathiya SS, Sharma SP, Babu R, Koshy S. Tooth Ache to Leprosy! Importance of Revisiting Diagnosis. *J Maxillofac Oral Surg* [Internet]. 2016 Jul 9; Available from: <https://doi.org/10.1007/s12663-016-0940-4>
6. Pichler JW, Beirne OR. Lingual flap retraction and prevention of lingual nerve damage associated with third molar surgery: a systematic review of the literature. *Oral Surg Oral Med Oral Pathol Oral Radiol Endod.* 2001 Apr;91(4):395–401.
7. Valmaseda-Castellón E, Berini-Aytés L, Gay-Escoda C. Lingual nerve damage after third lower molar surgical extraction. *Oral Surg Oral Med Oral Pathol Oral Radiol Endod.* 2000 Nov;90(5):567–73.
8. Cerovic R, Juretic M, Gobic MB. Neurectomy of the trigeminal nerve branches: clinical evaluation of an “obsolete” treatment. *J Cranio-Maxillo-fac Surg Off Publ Eur Assoc Cranio-Maxillo-fac Surg.* 2009 Oct;37(7):388–91.